



# A Scoping Review to Evaluate the Clinical Efficacy of Indigenously Produced, Patient-Specific Acrylic Cranial Prosthesis in Decompressive Craniectomy in India

Charu Guleria<sup>1</sup> Shrish Nalin<sup>2</sup> Dinesh Kumar<sup>2</sup>

<sup>1</sup> Health Technology Assessment (HTA), Community Medicine, Dr. Rajendra Prasad Government Medical College, Kangra, Himachal Pradesh, India

<sup>2</sup> Community Medicine, Dr. Rajendra Prasad Government Medical College, Kangra, Himachal Pradesh, India

**Address for correspondence** Dinesh Kumar, MD, Professor, Community Medicine, Dr. Rajendra Prasad Government Medical College, Kangra, Himachal Pradesh, 176001, India (e-mail: dinesh9809@gmail.com).

Indian J Neurosurg

## Abstract

**Background** Health Technology Assessment in India assesses, evaluates, and carries out cost-effectiveness of available health technologies in the country for evidence-based decision-making. Current study carried out a scoping review to assess clinical efficacy of poly-methyl-methacrylate (PMMA) after decompressive craniectomy using various prototyping techniques in published literature.

**Methods** The O'Malley methodology and Preferred Reporting Items for Systematic Reviews and Metanalysis for Scoping Reviews—PRISMA-ScR—checklist were used to assess published literature from year 2008 to 2023.

**Results** A total of 507 records were identified after searching electronic databases. After removing duplicate studies and studies that did not meet inclusion criteria, a total of 12 studies were included for review. A total of four studies were described as experimental and eight were case reports/series. The sample size of intervention studies varied between 10 and 30 patients with a mean age of 36.7 years. In a total of seven studies, cranioplasty was done by a self-made PMMA prosthesis fabricated using a novel three-dimensional-printed cranial model fabrication technique. In experimental study, objective criteria like operative Glasgow Outcome Scale, Cranial Index of Symmetry score, and Visual Analog Score for Cosmesis were employed.

**Conclusion** Clinical assessment for cranial symmetry was observed favorable for PMMA with fewer complications, though sample size was inadequate (range: 10–30) with comparator group in two studies.

## Keywords

- decompressive Craniectomy
- efficacy
- neurosurgery
- PMMA

## Introduction

Decompressive craniectomy (DC) is a surgical procedure that includes removing a portion of the patient's skull without immediate restoration. It is frequently used as a last resort therapy in patients with elevated intracranial pressure (ICP) following conditions like traumatic brain injury (TBI),

malignant infarction, cerebral venous sinus thrombosis, or a spontaneous intracerebral hemorrhage.<sup>1–4</sup> This procedure overcomes the space constraints of the Monroe-Kelly doctrine, which dictates that maintenance of constant ICP is a prerequisite for normal functioning of the brain.<sup>5</sup> ICP reduction is documented even in the ancient period, as skull trephination (to drill) was carried out in ancient Greece,

DOI <https://doi.org/10.1055/s-0043-1777056>.  
ISSN 2277-954X.

© 2023. The Author(s).

This is an open access article published by Thieme under the terms of the Creative Commons Attribution License, permitting unrestricted use, distribution, and reproduction so long as the original work is properly cited. (<https://creativecommons.org/licenses/by/4.0/>)

Thieme Medical and Scientific Publishers Pvt. Ltd., A-12, 2nd Floor, Sector 2, Noida-201301 UP, India

which was carried out in Roman era and Middle Ages.<sup>6–8</sup> After DC, cranial defects are restored by cranioplasty to maintain normal ICP and improve aesthesis. Autologous bone is used in contemporary reconstructive procedures for the skull, whereas synthetic alternatives are used in conditions where autografts are not available like in cases with bone graft resorption, infection, and limited donor site options.<sup>9–11</sup> Over time, a range of items was used in cranioplasty like metals (titanium), ceramics (hydroxyapatite, alumina), plastics, and recently polymers (poly-methyl-methacrylate [PMMA] and Polyetheretherketone [PEEK]) and biomaterials.<sup>12–14</sup>

PMMA is considered to be the most biocompatible synthetic material with characteristics like stability, durability, and strength along with being lightweight and well tolerated by adjacent tissues.<sup>15–17</sup> Therefore, PMMA is reported with high tensile strength, which makes it more resistant to stress and compression.<sup>12</sup> It is considered to be readily available, relatively inexpensive, moldable, adherent to soft tissue, nonconductive, heat resistant, and radiolucent.<sup>16</sup> Rapid prototyping technique (RPT), like three-dimensional (3D) casting of skull mount, has become convenient and reduces surgery time and errors related to manual fabrication.<sup>18</sup> A study used locally available material (Osteo3D Inc, Bengaluru, India) and reported a one-fifth reduction in average production cost as compared to nonmolded titanium plate.<sup>19</sup> In resource-limited countries, with high out-of-pocket expenditure (OOPE), low-cost technology proves to be beneficial in reducing catastrophic expenditure due to expensive surgical procedures.<sup>20–22</sup>

In India, Health Technology Assessment (HTA) has been launched for assessment, evaluation, and analysis of the cost-effectiveness of available health technologies in country. It is aimed to reduce OOPE and maximize the health benefits. Through its HTA India resource centers, evidence-based decision-making is done to inform national and state-level health policy. New technologies are assessed for their clinical efficacy and effectiveness with existing literature and then cost-effective analysis is carried out. Based on the result, a cost-effective technology is introduced among the population to maximize benefits.<sup>23</sup> With this mandate, current coping review was done to assess the extent of the use of PMMA in post-DC procedures with clinical efficacy using various prototyping techniques in published literature.

## Methods

The scoping review was carried out using O'Malley methodology involving standard steps like defining research question, identification of pertaining literature, selection of publications, extraction of data, data analysis, and summary.<sup>24</sup> To report current scoping review, the Preferred Reporting Items for Systematic Reviews and Metanalysis for Scoping Reviews—PRISMA-ScR—checklist was used.<sup>25</sup>

For the purpose of current review, the framed research question was: “What is the clinical efficacy of indigenously produced, patient-specific acrylic PMMA cranial prosthesis in decompressive craniectomy (DC) in India?” It also included a specific subset of questions “What techniques

are being used to place prosthesis?” and “What types of clinical criteria were used to assess for efficacy?”

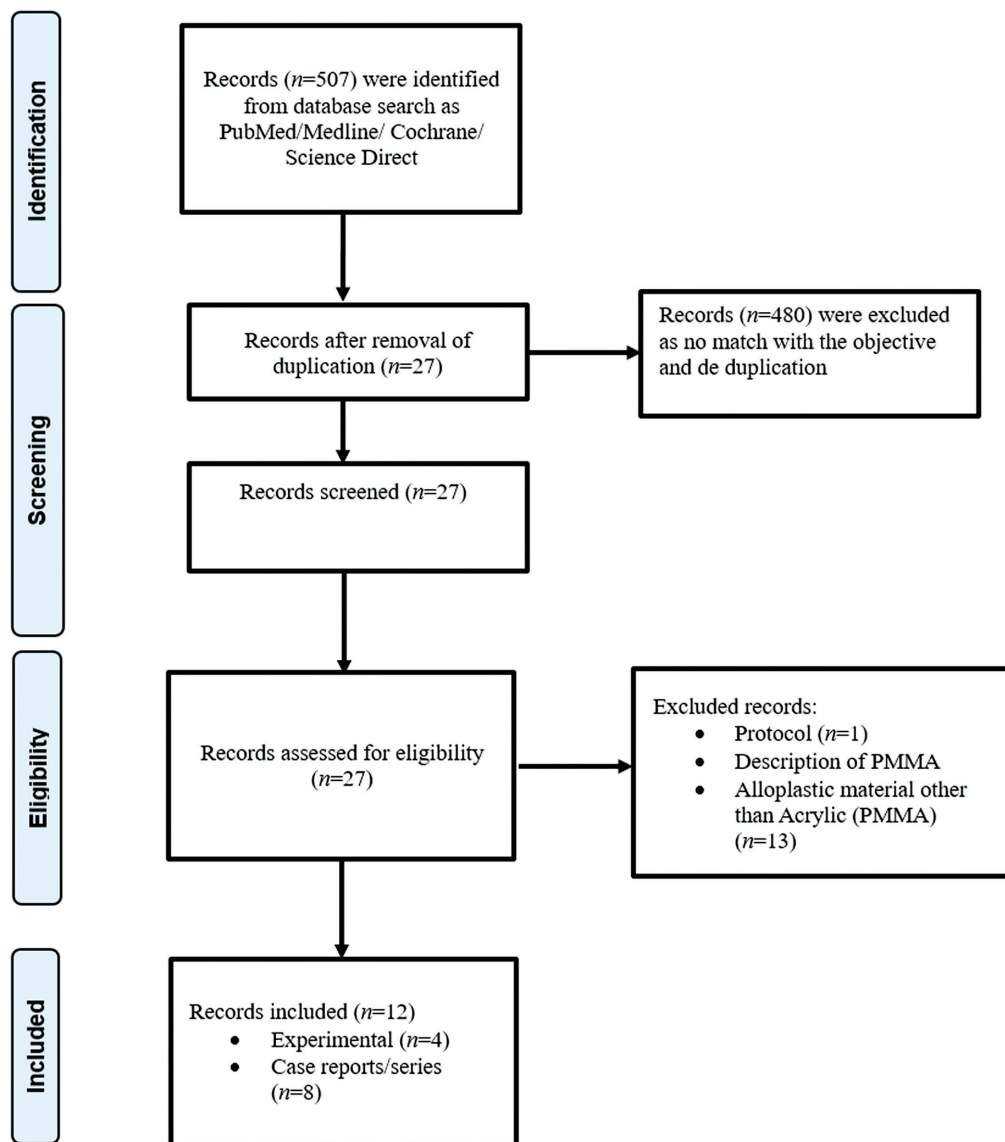
Inclusion criteria of studies were: studies mentioning PMMA acrylic material manufactured in India; studies carried out in India; full-text publications; published studies (original articles, case series/reports); studies published in the last 15 years (2008–2023); and publications in English language. Exclusion criteria for studies were: use of PMMA in other surgical procedures except DC; study protocols, abstracts, brief highlights, and editorials/commentaries/communications; and other languages. We searched the Cochrane Central Register of Controlled Trials and Cochrane Database of Systematic Reviews, MEDLINE, PUBMED, Science Direct, and Google Scholar for relevant studies. The keywords used were “decompressive craniotomy,” “decompressive craniectomy,” “cranial implants,” “India,” “cranial acrylic implants,” “PMMA implants,” “cranioplasty,” and “efficacy.” In addition, widespread Internet search was applied for relevant gray literature along with manual assessment of cross-references of included studies.

Studies were assessed first with screening of abstract and then full-text evaluation was done based on laid down inclusion and exclusion criteria. It was carried out by two researchers independently with an excellent agreement rate, so third independent assessment was not done. Mendeley reference manager was used for deduplication of retrieved records. Microsoft Excel was used to extract and collect information in a structured format aligning to research question.

## Results

A total of 507 records were identified after searching electronic databases and a total of 27 duplicate studies were removed. Therefore, a total of 12 studies were finally included in the current review, which focused on and described indigenously produced patient-specific acrylic implants post-DC (►Fig. 1). The acrylic material widely used for cranial defect restoration was PMMA, which edges over others in being radiolucent, ease of availability, and biocompatibility.

A detailed summary of the studies included for review is mentioned in ►Table 1. A total of four studies were described as experimental and eight were case reports/series (►Table 1). The sample size of intervention studies varied between 10 and 30 patients with a mean age of 36.7 years, whereas it ranged between 8 and 74 years in case reports/series. Distribution of clinical indication for intervention was TBI and stroke, and majority were males (~80.0%). In one clinical experimental study, cranioplasty was performed for restoration of cranial defects mainly due to nonavailability of the autologous bone graft.<sup>19</sup> A clinical experimental study compared PMMA with other materials like autologous bone grafts and titanium,<sup>26</sup> and another study retrospectively compared 3D technique with conventional alginate impression technique.<sup>27</sup> In remaining two clinical experimental studies, no comparator group was chosen to assess clinical outcomes following PMMA implant with 3D technology<sup>18,19</sup> (►Table 1).



**Fig. 1** PRISMA—Preferred Reporting Items for Systematic Reviews and Metanalysis—flowchart to report clinical efficacy of indigenously produced, patient-specific acrylic cranial prosthesis in decompressive craniectomy in India.

In a total of seven studies, cranioplasty was done by a self-made PMMA prosthesis fabricated using a novel 3D-printed cranial model fabrication technique. One of the studies used a 3D binder jet printer and in-house software for prosthesis fabrication.<sup>18</sup> Another one used 3D template molds created using a local start-up company, Osteo3D Inc, Bengaluru, India, using locally available acrylic material.<sup>19</sup> Majorly, studies reported the use of RPT for the fabrication of acrylic prosthesis using 3D technology (► **Table 1**).

All four clinical experimental studies reported the clinical efficacy as quantitative measures. Among these, a single study mentioned postoperative Glasgow Outcome Scale (GOS) as a criterion, two studies reported improved aesthesis by analysis of cosmesis and conformity using Cranial Index of Symmetry score and Visual Analog Score for Cosmesis (VASC), two studies mentioned patient satisfaction score and Odom's score, and one study reported postoperative infection episode and need for resurgery (► **Table 1**).

The mean GOS score postoperatively in a patient cohort (n = 10) was observed to be  $4.2 \pm 0.9$  with a median score of 5. Similarly, cranial symmetry is considered excellent in majority (80.0%) of cases postoperatively after fabrication of the PMMA implant.<sup>18,27</sup> The other study reported excellent median Odom's score in 52.0% of cases and good in 40.0% of cases postoperatively. The same study reported a good VASC score of  $8.2 \pm 1.4$  in the postoperative patients.<sup>19</sup> One of the studies compared two techniques of PMMA fabrication, where patient satisfaction was excellent in 69.2% of cases in 3D group as compared to 23.5% in group with conventional method (alginate-based). Cranial symmetry was reported satisfactory by 92.3% (n = 12) of the patient who underwent cranioplasty using 3D group compared to only 52.9% in alginate group. There was no need for resurgery in 92.3% of the patients who had PMMA implants with 3D fabrication. Further, a higher blood loss volume of 187.6 mL was observed in patients under alginate

**Table 1** Characteristics of the Indian studies included for search related to usage of acrylic implants post decompressive craniotomy

Author, year, place	Study design/Objective	No. of patients	Comparator	Characteristics and clinical indications	Intervention	Clinical outcomes	Clinical complications
Basu et al, 2021, Bangalore <sup>18</sup>	Clinical experimental/To establish safety profile and clinical efficacy of cranial prosthesis	10	None	Mean age: 40.8 ± 14.8 years (female: 1; males: 9); TBI and stroke	Self-made acrylic cranial prosthesis (PMMA) fabricated using a 3D-printed cranium model using 3D binderjet printer and in-house software	Properties of casted PMMA: hardness of 15.8 ± 0.24 Hv, tensile strength of 30.7 ± 3.9 Mpa, and elastic modulus of 1.5 ± 0.1 Gpa; Excellent CIS score (CIS ≥ 93.0%) in 80.0% patients; Mean postoperative GOS score: 4.2 ± 0.9	Follow-up: 6 months; Site infection (n = 1); Subgaleal collections (n = 2)
Gopal et al, 2021, Karnataka <sup>19</sup>	Clinical experimental/To evaluate the outcomes in 3D cranioplasty using CAD and 3D printing technology	25	None	Mean age: 38.4 ± 14.6 years (females: 7; males: 18); nonavailability of the autograft	Used 3D template molds created using a local start-up company, Osteo3D Inc, Bengaluru, India, using locally available acrylic material (PMMA)	Median Odom's score: Excellent in 52.0% (n = 13), Good in 40.0% (n = 10), and Fair in 8.0% (n = 2) of cases; Mean VASC score: 8.2 ± 1.4; Production cost: Expected 1/5 reduction in developed countries (i.e., INR 20,000); Production time is less than 13 hours	3D-bone flap infection, flap exposure due to skin necrosis, and extradural collection post surgery (n = 3)
Desai, 2019, Bangalore <sup>27</sup>	Observational retrospective study/To compare 3D-printed patient-specific mold preparation technique with conventional method	30 (3D group: 13; conventional group: 17)	Conventional alginate impression and wax elimination cranioplasty technique	3D group mean age: 35.9 ± 16.4 years (females: 2; males: 11), conventional group mean age: 40.9 ± 17.1 years (females: 4; males: 13); Patients treated for cranial defects using acrylic implants	Fabrication of custom-made PMMA-based cranial implants using conventional alginate impression and wax elimination technique and 3D-printed patient-specific mold and wax elimination technique of cranioplasty	3D Group Patient satisfaction: Excellent, 69.2% (n = 9); Fair, 7.7% (n = 1) Cranial symmetry: Satisfactory, 92.3% (n = 12); Unsatisfactory = 0 Surgery needed: No, 92.3% (n = 12); Minor, 7.7% (n = 1) Mean surgical time: 109.8 min (SEM 2.2) Mean estimated blood loss: 158.9 mL (SEM 2.8) <i>Alginate group</i> Patient satisfaction: Excellent, 23.5% (n = 5); Fair, 47.1% (n = 8) Cranial symmetry: Satisfactory, 52.9% (n = 9); Unsatisfactory: 5.9% (n = 1) Surgery need: No, 47.1% (n = 8) Need for new intervention: 5.8% (n = 1) Mean surgical time: 122.4 min (SEM 2.2) Mean estimated blood loss: 187.6 mL (SEM 4.8)	3D group: wound (n = 1); fluid collection (n = 3) Alginate group: wound (n = 3); fluid collection (n = 4)
Sahoo et al, 2010, Pune <sup>28</sup>	Clinical experimental/To compare and evaluate the outcome after reconstruction of cranial defects with an autologous vis-a-vis alloplastic material	22 (Autologous: 11; PMMA: 6; Titanium: 5)	Alloplastic materials (PMMA and Titanium)	Mean age: 27 years (males: 22); TBI and cranial tumor	Autologous bone graft titanium mesh PMMA	Autograft Graft uptake: Good, 100.0% (11) PMMA Graft uptake: Good, 20.0% (1); Implant exposure (3) Titanium Graft uptake: Good, 50.0 (3%);	Autograft: None PMMA: Postoperative infection (1) Titanium: Postoperative infection (1); Implant exposure (3)

**Table 1** (Continued)

Author, year, place	Study design/Objective	No. of patients	Comparator	Characteristics and clinical indications	Intervention	Clinical outcomes	Clinical complications
Thakur et al, 2019, New Delhi <sup>29</sup>	Case series/To compare techniques of prosthesis construction directly on skull template compared to prosthesis printed directly using 3D technology	2	3D technology	Age: case 1, 50 years; case 2, 45 years (males:2); TBI and stroke	Use of rapid prototyping technique (RPT) for construction of polyacrylic (PMMA) implants using 3D technology	Implant exposure (3); Thermal Sensitivity (2)  Aesthesia: Excellent in both patients; fewer chances of intraoperative corrections; uniform thickness of prosthesis; less time consuming; no wastage of material	None
Chauhan et al, 2022, New Delhi <sup>30</sup>	Case reports/Rehabilitation of the cranial defects using conventional method compared to 3D RPT using acrylic implant	4	3D technology	Age range: 18–74 years (females: 2; males: 2); TBI and tumor	Use of RPT for construction of polyacrylic (PMMA) implants using 3D technology	Improved aesthetics in all the patients; improved motor functions/patient able to walk with support; minimum adjustments required for prosthesis generated using 3D technology	None
Kaur et al, 2015, New Delhi <sup>31</sup>	Case report	1	None	Age: 8 years (male); Right parietal hemangioma	Manually fabricate a heat-polymerized PMMA-based cranial implant (utilizing a digitally obtained skull analog)	Satisfactory contour, shape, symmetry, and margins on clinical examination	None
Goyal and Goyal, <sup>32</sup> 2014, Rajasthan	Case report	1	None	Age: 17 years (male); TBI	Posttraumatic restoration of large cranial defect with alloplastic heat cure PMMA resin	Uneventful	None
Hallur et al, 2010, Karnataka <sup>33</sup>	Case report	1	None	Age: 40 years (male); TBI	Reconstruction of cranial bone defect with bone cement (surgical simplex —radiopaque PMMA resin)	Good aesthesis and excellent adaptation	None
Gupta et al, 2014, Manipal <sup>34</sup>	Case report	1	None	Age: 15 years; TBI	Cranial defect restored with a prefabricated acrylic resin prosthesis (PMMA)	Improved aesthesis	None
Simon et al, 2014, Salem <sup>35</sup>	Case report	1	None	Age: 14 years (male); TBI	Reconstruction of cranial bone defect with bone cement (surgical simplex —radiopaque PMMA resin)	Good aesthesis and excellent adaptation	None
Da Costa et al, 2016, Goa <sup>36</sup>	Case report	1	None	Age: 30 years (male); Infected bone fragment	Cranial defect restored with acrylic material (PMMA) using a unique flask design technique	Improved aesthesis	None

Abbreviations: 3D, three-dimensional; CAD, computer-aided design; CIS, Cranial Index of Symmetry; COS, Glasgow Outcome Scale; INR, Indian national rupee; PMMA, poly-methyl-methacrylate; SEM, standard error mean; TBI, traumatic brain injury; VASC, Visual Analog Score for Cosmesis.



group. In contrast, a lower mean blood loss volume was observed in PMMA implanted group, i.e., 158.9 mL.<sup>27</sup> In a comparative study measuring outcomes in cranioplasty done using autograft vs. alloplastic material (PMMA vs. Titanium), it was observed that patients who underwent cranioplasty with PMMA and titanium reported infection and implant exposure postoperatively. Meanwhile, none of the complications were reported in the group with autograft implants<sup>28</sup> (► **Table 1**).

In addition to the patient-related outcomes that were observed postoperatively, one of the studies established safety profile of the self-fabricated PMMA prosthesis and compared its properties with those of other alloplastic materials as mentioned in the literature. The authors obtained good properties of casted PMMA that include hardness of  $15.8 \pm 0.24$  Hv, tensile strength of  $30.7 \pm 3.9$  Mpa, and elastic modulus of  $1.5 \pm 0.1$  Gpa, which was clinically acceptable. Hence, low-cost 3D printer-based PMMA flap fabrication is an affordable option for cranioplasty in resource-constrained settings<sup>18</sup> (► **Table 1**).

Further, clinical complications were reported in 11 (12.6%) out of a total of 87 patients in 4 clinical experimental studies. After PMMA, wound infection was reported in 6 (6.9%) and fluid collection in 5 (5.7%) patients, which improved later on. In one of the patients, extradural collection post surgery required immediate reopening, evacuation of the clot, and replacement of the customized flap. In other two patients, there was a need to redo the surgery for construction of the bone flap using their previous template.<sup>18,19,27,28</sup>

There were seven case reports and one series report, which only mentioned subjective analysis of outcomes as an overall improvement in the patient aesthesia. The material used as implants in all the studies was PMMA. More than 50% of the studies used 3D technology RPT for fabricating the implant. In the rest of the studies, conventional methods of casting were described. In one study, comparison was done in two patients for prosthesis construction directly on skull and printed directly using 3D technology. None of case reports/series reported any complications after the surgery and reported satisfactory/improved/good/excellent aesthesia<sup>29–36</sup> (► **Table 1**).

## Discussion

The current literature review suggests PMMA acrylic material as one of the potential candidates that can be recommended for fabrication of the cranial defects post-DC. It edges over other materials in being less expensive and has produced good clinical outcomes regarding patients' overall aesthetics and satisfaction. Limited evidence from India suggests that the use of 3D RPT is growing. It is likely to reduce time and errors in the fabrication of the prosthesis, improve technical efficiency, reduce surgery time, and provide good aesthetics as compared to manual fabrication of the implant using conventional techniques. PMMA observed hardness and better cranial symmetry when 3D technique was used to cast the graft.<sup>18,19,27</sup> Accessibility to locally produced 3D

technology and PMMA material is expected to reduce production costs (up to 80%).<sup>19</sup> In all intervention studies, postoperative complications were observed among 11 (12.6%) out of a total of 87 patients in 4 clinical experimental studies. After PMMA, wound infection was reported in 6 (6.9%) and fluid collection in 5 (5.7%) patients. Complications like implant exposure were observed in three patients whereas two patients required redo surgery. None of the case reports/series reported postoperative complications. All patients in case reports/series were assessed clinically and observed with satisfactory clinical aesthetics.

Clinical outcomes to assess intracranial function were limited, as one study<sup>18</sup> reported a mean GOS of 4.2, which can be considered favorable.<sup>37</sup> Odom's criteria,<sup>38</sup> a 4-point scale to assess patient's satisfaction, were used in one study where it was excellent in half of the patients.<sup>19</sup> Same study observed a Visual Analogue Scale to assess clinical wounds and also showed excellent results.<sup>39</sup> Assessment for clinical symmetry was also done along with blood loss and average surgery time in one study. These indicators favored PMMA with 3D as compared to conventional alginate impression and wax elimination cranioplasty technique.<sup>27</sup>

Patient dissatisfaction due to cranial deformity after DC is a common reason for placing grafts. In a study, not from India, in which retrospective analysis was done on 108 patients, 18.0% underwent primary/secondary surgical intervention to recorrect temporal deformity. In one patient, an altered mental state due to mass effect was observed and urgent recontouring of PMMA was done. A review of 25 studies reported that complications were not reported in patients with alloplastic material, autologous bone, and free tissue transfer. Catastrophic complications like stroke, pulmonary embolism, and death were not observed with the use of alloplastic material as a graft, whereas it was observed to be associated with fat augmentation and dermal filler.<sup>40</sup>

Computer-aided manufacturing was adopted where autologous bone grafts cannot be used. A systematic review of 36 articles showed that 3D printing was used in various other fields along with neurosurgery for surgical planning, simulation and training, tissue-engineered implants, and secondary devices.<sup>41</sup> The use of desktop 3D printers led to the production of patient-specific implants with excellent cosmesis. It can be done intraoperatively for various cranial discontinuities. This evidence reported with cost of Canadian dollar (CAD) 50–100 per case with expected annual savings of CAD 685,000 in Canada.<sup>42</sup>

## Limitations of Study

As a limitation, quality assessment of studies in scoping reviews is not explicit. For current review, studies from India and those that used PMMA implant as a post-DC procedure, irrespective of clinical condition, were studied. It was more specific as to a research question. Studies reported were extracted using online platforms with cross-checking of references. It is limited to numerical summary and reporting of results. Next steps like stakeholders' consultations and additional considerations to support

applications and advancements of scoping review were not done in current study.<sup>43</sup>

## Conclusion

We think that in the Indian context, this study gives a good idea that suggests usage of PMMA material with 3D printing technology. Selection of study period was considered wide to include all available evidence and it suggests that it is recently becoming in use due to availability of affordable technology. PMMA is safe, with satisfactory aesthetic and low complication rate favoring its more use in coming times. This review suggests a large scope of PMMA and computer-aided technology in post-DC procedure. Affordable and quality manufacturing of PMMA and 3D printers with standardized training protocols will be beneficial to patients.

## A Way Forward

However, there is negligible evidence to support the clinical efficacy of acrylic material over other alloplastic materials. Studies highlighting the outcomes have inadequate sample sizes with differential results. Most of them are focused around visual inspection of improved aesthesis pre and post surgery, which might not be valid study designs to assess clinical efficacy. The current review suggested scarce evidence to support the use of clinical effectiveness of PMMA in DC. It would have been prudent to use interventional study with a comparator/control group with high study power to assess PMMA in DC. Patients requiring DC should be as per the prior laid inclusion and exclusion criteria. Standardization of interventions (PMMA technology and surgical protocols) and clinical outcome measures like Glasgow Coma Scale (GCS), aesthetics, patient satisfaction, and postoperative complications should be clearly defined. Due to limited and varying study participants in one health institute, a multicentric study with standardized protocols could be planned to reach out required sample size.

## Conflict of Interest

None declared.

## References

- Hutchinson PJ, Kolia AG, Tajsic T, et al. Consensus statement from the International Consensus Meeting on the Role of Decompressive Craniectomy in the Management of Traumatic Brain Injury: consensus statement. *Acta Neurochir (Wien)* 2019;161(07):1261–1274
- National Institute for Health and Care Excellence. Stroke and transient ischaemic attack in over 16s: diagnosis and initial management [Internet]; 2019. Available at: <https://www.nice.org.uk/guidance/ng128/resources/stroke-and-transient-ischaeic-attack-in-over-16s-diagnosis-and-initial-management-pdf-66141665603269>
- Avanali R, Gopalakrishnan MS, Devi BI, Bhat DI, Shukla DP, Shanbhag NC. Role of decompressive craniectomy in the management of cerebral venous sinus thrombosis. *Front Neurol* 2019;10:511
- Hemphill JC III, Greenberg SM, Anderson CS, et al; American Heart Association Stroke Council Council on Cardiovascular and Stroke Nursing Council on Clinical Cardiology. Guidelines for the management of spontaneous intracerebral hemorrhage: a guideline for healthcare professionals from the American Heart Association/American Stroke Association. *Stroke* 2015;46(07):2032–2060
- Monro A. Observations on the structure and functions of the nervous system. *Lond Med J* 1783;4(02):113–135
- Di Ieva A, Gaetani P, Matula C, Sherif C, Skopec M, Tschabitscher M. Berengario da Carpi: a pioneer in neurotraumatology. *J Neurosurg* 2011;114(05):1461–1470
- Panourias IG, Skiadas PK, Sakas DE, Marketos SG. Hippocrates: a pioneer in the treatment of head injuries. *Neurosurgery* 2005;57(01):181–189, discussion 181–189
- Kshetry VR, Mindea SA, Batjer HH. The management of cranial injuries in antiquity and beyond. *Neurosurg Focus* 2007;23(01):E8
- Honeybul S, Morrison DA, Ho KM, Lind CRP, Geelhoed E. A randomised controlled trial comparing autologous cranioplasty with custom-made titanium cranioplasty: long-term follow-up. *Acta Neurochir (Wien)* 2018;160(05):885–891
- Honeybul S, Morrison DA, Ho KM, Lind CRP, Geelhoed E. A randomized controlled trial comparing autologous cranioplasty with custom-made titanium cranioplasty. *J Neurosurg* 2017;126(01):81–90
- Li LM, Timofeev I, Czosnyka M, Hutchinson PJA. Review article: the surgical approach to the management of increased intracranial pressure after traumatic brain injury. *Anesth Analg* 2010;111(03):736–748
- Shah AM, Jung H, Skirboll S. Materials used in cranioplasty: a history and analysis. *Neurosurg Focus* 2014;36(04):E19
- Wiggins A, Austerberry R, Morrison D, Ho KM, Honeybul S. Cranioplasty with custom-made titanium plates–14 years experience. *Neurosurgery* 2013;72(02):248–256, discussion 256
- Kwarcinski J, Boughton P, Ruys A, Doolan A, van Gelder J. Cranioplasty and craniofacial reconstruction: a review of implant material, manufacturing method and infection risk. *Appl Sci (Switzerland)* 2017;7(03):276
- Ganau M, Cebula H, Fricia M, et al. Surgical preference regarding different materials for custom-made allograft cranioplasty in patients with calvarial defects: results from an internal audit covering the last 20 years. *J Clin Neurosci* 2020;74:98–103
- Al-Tamimi YZ, Sinha P, Trivedi M, et al. Comparison of acrylic and titanium cranioplasty. *Br J Neurosurg* 2012;26(04):510–513
- Konofaos P, Thompson RH, Wallace RD. Long-term outcomes with porous polyethylene implant reconstruction of large craniofacial defects. *Ann Plast Surg* 2017;79(05):467–472
- Basu B, Bhaskar N, Barui S, et al. Evaluation of implant properties, safety profile and clinical efficacy of patient-specific acrylic prosthesis in cranioplasty using 3D binderjet printed cranium model: a pilot study. *J Clin Neurosci* 2021;85:132–142
- Gopal S, Rudrappa S, Sekar A, Preethish-Kumar V, Masapu D. Customized and cost-effective 3D printed mold for cranioplasty: India's first single center experience. *Neurol India* 2021;69(03):611–617
- Shastri S, Sathyanarayana S, Nagaraja SB, et al. The journey to antiretroviral therapy in Karnataka, India: who was lost on the road? *J Int AIDS Soc* 2013;16(01):18502
- Pandey A, Ploubidis GB, Clarke L, Dandona L. Trends in catastrophic health expenditure in India: 1993 to 2014. *Bull World Health Organ* 2018;96(01):18–28
- Dwivedi R, Pradhan J, Athe R. Measuring catastrophe in paying for healthcare: a comparative methodological approach by using National Sample Survey, India. *Int J Health Plann Manage* 2021;36(05):1887–1915
- Dabak SV, Pilasant S, Mehndiratta A, et al. Budgeting for a billion: applying health technology assessment (HTA) for universal health coverage in India. *Health Res Policy Syst* 2018;16(01):115
- Arksey H, O'Malley L. Scoping studies: towards a methodological framework. *Int J Soc Res Methodol* 2005;8(01):19–32

- 25 Tricco AC, Lillie E, Zarin W, et al. PRISMA extension for scoping reviews (PRISMA-ScR): checklist and explanation. *Ann Intern Med* 2018;169(07):467–473
- 26 Sahoo M, Pradhan J. Using three delay model to understand the social factors responsible for neonatal deaths among displaced tribal communities in India. *J Immigr Minor Health* 2021;23(02):265–277
- 27 Desai JB. Cost-effective technique of fabrication of polymethyl methacrylate based cranial implant using three-dimensional printed moulds and wax elimination technique. *J Craniofac Surg* 2019;30(04):1259–1263
- 28 Sahoo N, Roy ID, Desai AP, Gupta V. Comparative evaluation of autogenous calvarial bone graft and alloplastic materials for secondary reconstruction of cranial defects. *J Craniofac Surg* 2010;21(01):79–82
- 29 Thakur A, Chauhan D, Viswambaran M, Yadav RK, Sharma D. Rapid prototyping technology for cranioplasty: a case series. *J Indian Prosthodont Soc* 2019;19(02):184–189
- 30 Chauhan D, Chattopadhyay PK, Thakur A. Reconstruction of cranial defect with patient-specific implants: four different cost-effective techniques. *Natl J Maxillofac Surg* 2022;13(01):136–142
- 31 Kaur H, Nanda A, Koli D, et al. An alternate vista in rehabilitation of cranial defects: combining digital and manual techniques to fabricate a hybrid cranioplast. *J Craniofac Surg* 2015;26(04):1313–1315
- 32 Goyal S, Goyal MK. Restoration of large cranial defect for cranioplasty with alloplastic cranial implant material: a case report. *J Indian Prosthodont Soc* 2014;14(02):191–194
- 33 Hallur N, Goudar G, Sikkerimath B, Gudi SS, Patil RS. Reconstruction of large cranial defect with alloplastic material (bone cement-cold cure polymethyl-methacrylate resin). *J Maxillofac Oral Surg* 2010;9(02):191–194
- 34 Gupta L, Aparna I, Balakrishnan D, Deenadayalan L, Hegde P, Agarwal P. Cranioplasty with custom made alloplastic prosthetic implant: a case report. *World J Clin Cases* 2014;2(09):482–487
- 35 Simon P, Mohan J, Selvaraj S, Saravanan BS, Pari P. Craniofacial prosthetic reconstruction using polymethyl methacrylate implant: a case report. *J Indian Prosthodont Soc* 2014;14 (Suppl 1):303–307
- 36 Da Costa GC, Aras MA, Chalakkal P. A unique flask design for processing cranial prosthesis using heat cured acrylic - a case report. *J Clin Diagn Res* 2016;10(09):ZD14–ZD16
- 37 Klemenc-Ketis Z, Bacovnik-Jansa U, Ogorevc M, Kersnik J. Outcome predictors of Glasgow Outcome Scale score in patients with severe traumatic brain injury. *Ulus Travma Acil Cerrahi Derg* 2011;17(06):509–515
- 38 Broekema AEH, Molenberg R, Kuijlen JMA, Groen RJM, Reneman MF, Soer R. The Odom Criteria: validated at last: a clinimetric evaluation in cervical spine surgery. *J Bone Joint Surg Am* 2019; 101(14):1301–1308
- 39 Quinn JV, Wells GA. An assessment of clinical wound evaluation scales. *Acad Emerg Med* 1998;5(06):583–586
- 40 Santiago GF, Terner J, Wolff A, et al. Post-neurosurgical temporal deformities: various techniques for correction and associated complications. *J Craniofac Surg* 2018;29(07):1723–1729
- 41 Randazzo M, Pisapia JM, Singh N, Thawani JP. 3D printing in neurosurgery: a systematic review. *Surg Neurol Int* 2016;7 (Suppl 33):S801–S809
- 42 Lannon M, Algird A, Alsunbul W, Wang BP. 209 Novel 3D printing for complex cranial reconstruction in neurosurgery - a case series. *Canadian J Neurol Sci* 2021;48(s3):S80
- 43 Levac D, Colquhoun H, O'Brien KK. Scoping studies: advancing the methodology. *Implement Sci* 2010;5(01):69