



Hepatocellular Carcinoma Presenting as Extension of Tumor Thrombus into the Right Atrium from the Portal Vein through Inferior Vena Cava Treated with Chemoembolization: A Rare Case Report

Kashish Khurana¹ Saket Toshniwal¹  Nikhil Pantbalekundri¹ Sunil Kumar, MD, PhD¹
Sourya Acharya¹

¹Department of Medicine, Jawaharlal Nehru Medical College, Datta Meghe Institute of Higher Education and Research (Deemed to be University), Sawangi (Meghe), Wardha, Maharashtra, India

Address for correspondence Sunil Kumar, MD, PhD, Department of Medicine, Jawaharlal Nehru Medical College, Datta Meghe Institute of Higher Education and Research (Deemed to be University), Sawangi (Meghe), Wardha 442001, Maharashtra, India (e-mail: sunilkumarmed@gmail.com).

J Health Allied Sci^{NU} 2024;14:566–569.

Abstract

Patients with tumor thrombosis in the portal vein due to hepatocellular carcinoma (HCC) are uncommon, and the majority of these cases is thought to be in an advanced stage with a bad prognosis. The right atrium and the inferior vena cava may be impacted by the intravascular tumor thrombus, with the latter having a bad prognosis. Portal vein involvement is one of the most serious consequences of HCC. For both systemic and locoregional therapy, targeting many pathways in the HCC cascade using a mix of medications and additional modalities like transarterial chemoembolization, transarterial radioembolization, radiation, and hepatic arterial infusion chemotherapy appears to be helpful.

Keywords

- ▶ tumor thrombosis
- ▶ right atrium
- ▶ transarterial chemoembolization
- ▶ transarterial radioembolization

Portal vein tumor thrombosis, which affects 35 to 50% of patients, is a strong predictor of poor prognosis due to the higher likelihood of tumor migration into the bloodstream and the subsequent increased risk of recurrence. This case report highlights about a 60-year-old female who presented with HCC with portal vein tumor thrombosis not willing for chemo- and radiotherapy successfully treated with transarterial chemoembolization as a palliative management.

Introduction

One of the most significant primary malignant liver diseases is hepatocellular carcinoma (HCC). The portal vein and its branches are the most prevalent sites of macrovascular invasion in patients with advanced stages of HCC. Less frequently, the hepatic veins, the inferior vena cava (IVC), and the right atrium are also invaded by HCC.

Patients who have tumor thrombus in right atrium typically have a worse prognosis than those who have tumor thrombus in the portal veins, and this is frequently because

the major hepatic vein has spread to the right atrium via the IVC.¹ The presence of underlying chronic liver disorders is frequently the underlying cause of HCC.

HCC diagnosis can be difficult, and it is typically necessary to use one or more imaging modalities. Tumors should preferably be detected when they are less than 2 cm in size to provide all therapeutic options. Advanced HCC cases usually show vascular invasion and tumor thrombus formation because hemostasis has been activated.¹

After pancreatic cancer, liver carcinoma is currently the second-most deadly tumor. Chronic hepatitis B virus

article published online
November 22, 2023

DOI <https://doi.org/10.1055/s-0043-1777020>.
ISSN 2582-4287.

© 2023. The Author(s).

This is an open access article published by Thieme under the terms of the Creative Commons Attribution License, permitting unrestricted use, distribution, and reproduction so long as the original work is properly cited. (<https://creativecommons.org/licenses/by/4.0/>)

Thieme Medical and Scientific Publishers Pvt. Ltd., A-12, 2nd Floor, Sector 2, Noida-201301 UP, India

Table 1 Laboratory parameter of the patient with normal reference range

Parameter	Value	Normal value
Hemoglobin	9.6 g/dL	12–15 g/dL
Total leukocyte count	14,800	4,000–11,000 cu.mm
Platelet count	1.48	1.5–4.1 lakhs/ cu.mm
Mean corpuscular volume	72.5	83–101 fl
Alkaline phosphatase	231	38–126 U/L
Alanine aminotransferase	142	<35 U/L
Aspartate aminotransferase	247	14–36 U/L
Blood urea	91	15–36
Serum creatinine	1.4	0.52–1.04
Serum potassium	4.6	3.5–5.1 mEq/L
Total bilirubin	1.3	0.2–1.3 mg/dL
Conjugated bilirubin	0.6	0–0.3 mg/dL
Serum ammonia	39	9–30 micromole/L
CK-MB	32	<16U/L
Troponin-I	6.13	<15pg/mL
Prothrombin time	12.3	11.9 seconds
Activated partial thromboplastin time	31.7	29.5 seconds
Alpha fetoprotein	788	<40 ng/mL
Hepatitis B virus quantitative PCR	1,13,363	<40 IU/mL

Abbreviations: CK-MB, creatine kinase MB; PCR, polymerase chain reaction.

infection is one of the most frequent causes of liver cancer, but in Western nations, chronic alcohol use, nonalcohol-related steatohepatitis, and chronic hepatitis B and C virus infection are the most frequent causes.²

Case Presentation

A 60-year-old female came to the hospital in conscious state with complaints of abdominal pain that was insidious in onset, gradually progressive in nature, and associated with abdominal distension. There was no history of vomiting, loose stools, fever, chest pain, palpitations, and breathlessness. Physical examination was normal. On arrival to the hospital, the patient had no symptoms of right sided heart failure or pulmonary thromboembolism. All routine investigations were done and the patient was found to be positive for hepatitis B surface antigen with hepatitis B virus quantitative polymerase chain reaction also raised as shown in **Table 1**. Her ultrasound of abdomen pelvis revealed an irregular hyperechoic mass lesion noted in segment VIII and IVa that measured around 7.5 × 7 cm in size and the lesion was extending into right hepatic vein and portal vein causing tumor thrombus with gross ascites. Upper gastrointestinal endoscopy was done that was suggestive of large esophageal varices which had undergone ligation. Two-dimensional echo was suggestive of large 30 × 15 mm of thrombus at IVC and right atrium junction with mild tricuspid regurgitation with good biventricular function. Contrast-enhanced computed tomography (CT) abdomen and pelvis was done that was suggestive of abnormal arterial flow involving

segment VI and VII of liver with abnormal ill-defined lesion in same segment with altered parenchyma of liver involving segment VIII, VII, VI, V of right lobe of liver with multiple nodularity. Thrombus was seen extending into the intrahepatic portion of IVC. The lesion showed abnormal enhancement on arterial phase with early washout on venous phase. There was extension seen on femoral thrombus into the portal vein. CT-guided hepatic biopsy was taken that was suggestive of HCC (well-differentiated) with tumor thrombosis (**Fig. 1**). Patient was advised chemotherapy as well as other adjuvant

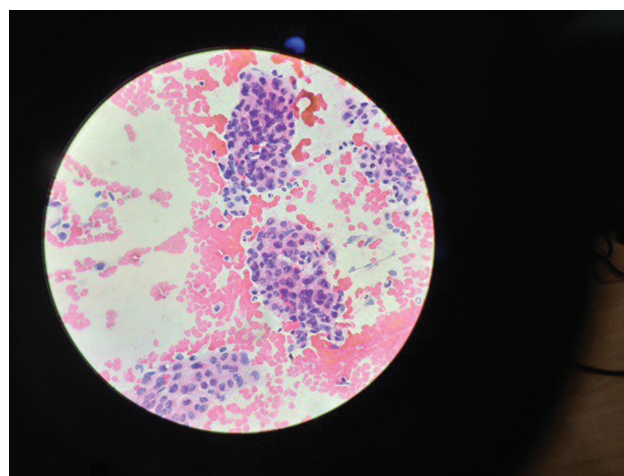


Fig. 1 Computed tomography-guided hepatic biopsy suggestive of hepatocellular carcinoma (well-differentiated) with tumor thrombosis.

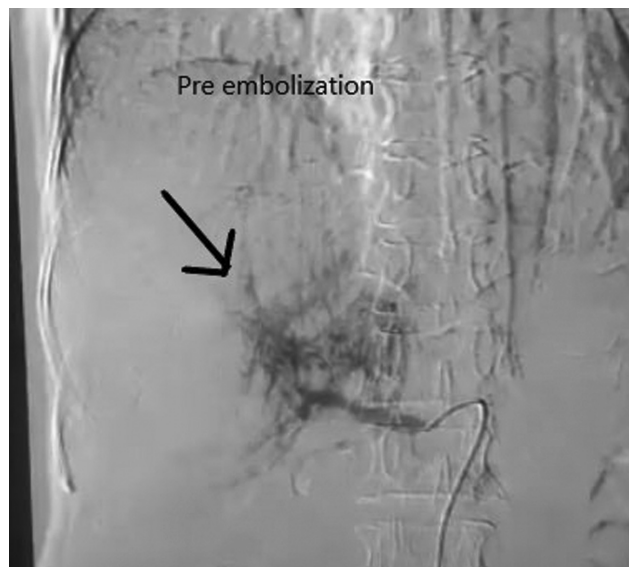

Fig. 2 Computed tomography angiography showing tumor thrombus status before transarterial chemoembolization done using doxorubicin and lipiodol.

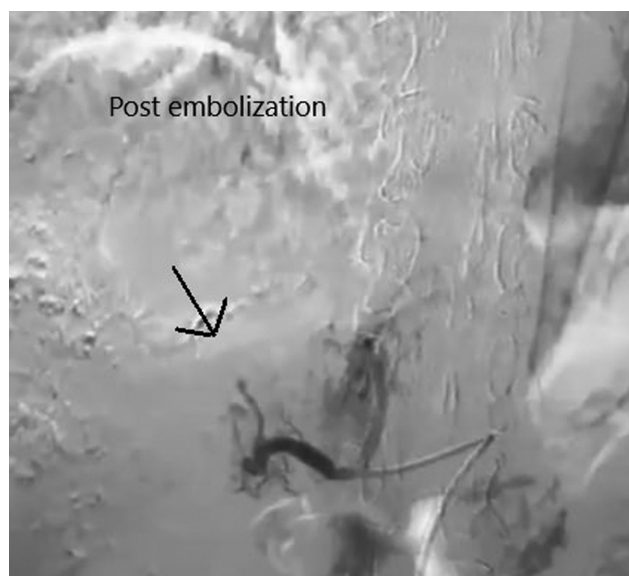

Fig. 3 Computed tomography angiography showing tumor thrombus status after transarterial chemoembolization done using doxorubicin and lipiodol.

therapies (immunotherapy), but the patient and her relatives refused. Transarterial chemoembolization was done using doxorubicin and lipiodol as shown in ►Fig. 2. Postembolization scan of the liver is shown in ►Fig. 3. Patient was started on antihepatitis B drugs (tab entecavir 0.5 mg once daily), oral propranolol, and other palliative treatment. On follow-up after 1 month, patient was doing well.

Discussion

The most prevalent primary hepatic neoplasm is HCC. In the entire world, it is the fifth most common cancer to be

diagnosed in men and the ninth most common cancer to be diagnosed in women. Chronic liver disease has a direct correlation to the development of HCC.² To consider all treatment options, the size of the tumor should be less than 2 cm when it is detected for the first time. HCC diagnosis can be challenging, and one or more imaging techniques are frequently needed.

Advanced HCC cases frequently show vascular invasion and tumor thrombus development as a result of hemostasis activation. Chances of vascular invasion in case of HCC are directly proportional to the size of the tumor. Higher rates of vascular invasion are present in patients with serum α -fetoprotein levels more than 1,000 g/L and size of tumor more than 5 cm. IVC thrombosis is frequently asymptomatic; however, ascites, upper gastrointestinal hemorrhage, and stomach pain are all signs of portal hypertension.² On the other hand, HCC's intra-atrial growth could result in pulmonary thrombosis and pulmonary metastases even if it does not directly cause any symptoms.

Rarely, as reported in 0.67 to 4.1% of autopsies, do HCC patients have tumor thrombi that extend through the main hepatic veins and IVC into the right atrium. Most of these cases are in advanced stages with a bad prognosis. Our patient is elderly and has a tumor thrombus in the femoral vein that has invaded the portal vein with further thrombosis in the right atrium via the IVC. This was a rare occurrence with a poor prognosis due to elevated systemic metastatic risk and the potential for imminent mortality from pulmonary embolism or abrupt heart failure. The most successful treatment was thought to be hepatic resection together with the excision of the tumor thrombus. In contrast, the patient in our case had a severely cirrhotic liver and was a hepatitis B virus carrier. The left and anterior segments of the liver were involved as seen on the CT abdomen that if resected could have led to liver insufficiency.

On the other hand, it might cause abrupt death because the development of tumor thrombosis, heart failure, and pulmonary thromboembolism would be unavoidable. As a result, even if the tumor cannot be removed, it is still vital to get rid of the tumor thrombus for the patient's benefit. With the advancement in surgical procedures, there have been instances where a primary liver tumor has been removed with simultaneous removal of tumor thrombosis. Because the major hepatic vein has commonly extended to the right atrium via the IVC, patients who have tumor thrombus in the right atrium typically have a worse prognosis than patients who have tumor thrombus in the portal veins. The underlying cause of HCC is typically the existence of liver parenchymal disease. HCC diagnosis can be difficult, and it is typically necessary to use one or more imaging modalities. Tumors should preferably be detected when they are less than 2 cm in size to provide all therapeutic options.³ Advanced HCC cases usually show vascular invasion and tumor thrombus formation because hemostasis has been activated. The median patient survival time in the absence of medication has been estimated to be between 2.7 and 4 months, but it can also range from 5 months to 5 years, demonstrating the tremendously wide range of circumstances.

These findings suggested that compared with other non-surgical treatments, surgery, either thrombus removal together with hepatectomy or only tumor thrombus extraction, may improve survival.⁴ Our case was consistent with people who simply had tumor thrombus extraction survive.

Conclusion

HCC is one of the most common and aggressive malignant tumors. It commonly results in tumor thrombosis in its advanced phases, which primarily impacts the portal vein and less frequently the hepatic veins. The staging of primary liver tumors and the diagnosis of HCC both rely heavily on noninvasive imaging. Dynamic explorations that reveal a typical diagnostic pattern eliminate the need for additional invasive diagnostic tests. IVC and right atrium HCC tumor thrombus growth is uncommon and implies a poor prognosis.

Conflict of Interest

None declared.

References

- 1 Md Radzi AB, Tan SS. A case report of metastatic hepatocellular carcinoma in the mandible and coracoid process: a rare presentation. *Medicine (Baltimore)* 2018;97(04):e8884
- 2 Luo X, Zhang B, Dong S, Zhang B, Chen X. Hepatocellular carcinoma with tumor thrombus occupying the right atrium and portal vein: a case report and literature review. *Medicine (Baltimore)* 2015;94(34):e1049
- 3 Gomez-Puerto D, Mirallas O, Vidal-González J, Vargas V. Hepatocellular carcinoma with tumor thrombus extends to the right atrium and portal vein: a case report. *World J Hepatol* 2020;12(11):1128–1135
- 4 Fujii T, Takayasu K, Muramatsu Y, et al. Hepatocellular carcinoma with portal tumor thrombus: analysis of factors determining prognosis. *Jpn J Clin Oncol* 1993;23(02):105–109