



Place of Plasma Argon Coagulation in the Treatment of Vascular Abnormalities of the Digestive Tract in Adults

Samir Mrabti¹ Ahlame Benhamdane¹ Asmae Sair¹ Tarik Addajou¹ Réda Berrida¹ Sara Sentissi¹
 Ilham Koti¹ Fedoua Rouibaa¹ Ahmed Benkirane¹ Hassan Seddik¹

¹Hepato-gastroenterology Department II, Mohammed V Military Instruction Hospital, Mohammed V University, Rabat, Morocco

J Coloproctol 2023;43(4):e292–e299.

Address for correspondence Samir Mrabti, Medical Specialty in Hepatogastroenterology, Hepato-gastroenterology Department II, Mohammed V Military Instruction Hospital/Mohammed V University, Avenue the royal armed forces riad district, Rabat/Postal code 1018, Morocco (e-mail: doc.mrabti@gmail.com).

Abstract

The aim of our study is to evaluate the value of Argon Plasma Coagulation in the treatment of gastrointestinal vascular abnormalities.

Patients and methods This is a descriptive and analytical retrospective study, from January 2009 to September 2020. 198 patients who have benefited from treatment with Argon Plasma Coagulation for vascular anomalies of the digestive tract divided into 2 groups:

-Group A: Patients with radial rectitis lesions (n = 107).

-Group B: Patients with lesions of digestive angiodysplasia (n = 91).

Results The mean age of our patients was 64.95 ± 9.88 years [43 - 83] in group A, while in group B the mean age was 65.19 ± 14.29 years [40 - 91] with a clear male predominance in 72.5%. The majority of patients in group A were followed for prostate cancer in 33,8%, and 26.3% of patients in group B had chronic renal failure, followed by stomach cancer in 15.8%, and esophageal cancer in 10.5%. Clinical symptomatology was dominated by rectories in 40.2% in group A versus 46.8% in group B. Rectal involvement was dominated in group A in 98.1%, whereas in group B the lesions were mainly located in the stomach in 60.5%. The endoscopic evolution was favorable in all our patients with a clear improvement of rectal lesions and digestive angiodysplasia lesions. The total complication rate in our series was nil.

Conclusion Plasma Argon coagulation is a very effective method in the endoscopic treatment of digestive haemorrhages with good tolerability and a low complication rate.

Keywords

- ▶ argon plasma coagulation
- ▶ radiation rectitis
- ▶ intestinal angiodysplasia

received
 December 12, 2022
 accepted after revision
 October 24, 2023

DOI <https://doi.org/10.1055/s-0043-1776886>.
 ISSN 2237-9363.

© 2023. Sociedade Brasileira de Coloproctologia. All rights reserved.

This is an open access article published by Thieme under the terms of the Creative Commons Attribution-NonDerivative-NonCommercial-License, permitting copying and reproduction so long as the original work is given appropriate credit. Contents may not be used for commercial purposes, or adapted, remixed, transformed or built upon. (<https://creativecommons.org/licenses/by-nc-nd/4.0/>)

Thieme Revinter Publicações Ltda., Rua do Matoso 170, Rio de Janeiro, RJ, CEP 20270-135, Brazil

Introduction

Digestive angiodysplasias are vascular malformations whose pathogenesis is poorly known. They are a rare cause of upper and lower occult or externalized digestive hemorrhages. Most of them are of acquired origin, most often affecting the right colon and the cecum, but can sit on the entire digestive tract.

On the other hand, radiation proctitis is a frequent complication, of variable severity, occurring a few months after the radiation of the pelvic-perineal organs has stopped, but which can manifest itself several years later.

Argon plasma coagulation (APC) is the technique of choice in the treatment of digestive vascular abnormalities, improving the quality of life of patients and reducing the need for repeated transfusions.^{1,2}

The objective of our study is to evaluate the value of Argon Plasma Coagulation in the treatment of gastrointestinal vascular abnormalities.

Materials and Methods

Method

Type of study:

This is a descriptive and analytical retrospective study over an 11-year period, from January 2009 to September 2020.

Instruments

The equipment required to perform the APC includes:

-The Argon bottle: Argon can be easily ionized at high electrical frequency and is then transformed into a stable plasma of a pale yellow color.

-The electric scalpel with APC program.

-The pedal: connected to the unit and allowing the control of the electric arc.

-The APC probe: this is a teflon catheter in which a tungsten electrical guide is inserted. This electrode is connected at its distal end with a ceramic inserted in the catheter lumen. Some catheters are perforated laterally at their distal end their diameters are 1.5 mm, 2.3 mm, and 3.2 mm. The standard length is 220 cm, up to 300 cm for use in enteroscopy.

-The endoscope: The endoscopes used for the treatment of gastroduodenal and colonic lesions were video endoscopes. The lesions of the small bowels that were not accessible of oesogastroduodenal fibroscopy or colonoscopy were treated by high or low enteroscopy, depending on the case.

Deep coagulation by APC is directly dependent on the power and time of coagulation, so a perforation is possible. The ideal distance between the APC probe and the tissue is 3 to 5 mm. The contact time should be in periods of 0.5 to 2 seconds (0.5 seconds for the colon).

The average power used is 70 to 90 W for a recommended argon flow rate of 0.8 to 1.2 liters per minute.

Flow rate (power //flux):

-Colon, Duodenum and Small Intestine: 40W// 0.6L/min.

-Esophagus and Stomach: 50W// 0.8L/min.

Patients:

198 patients who have benefited from treatment with Argon Plasma Coagulation (APC) for vascular anomalies of the digestive tract, divided into 2 groups:

-Group A: Patients with radial rectitis lesions (n = 107).

-Group B: Patients with lesions of digestive angiodysplasia (n = 91).

Positive diagnosis was established by endoscopic examinations (Fibroscopy, enteroscopy, colonoscopy) or by endoscopic videocapsule.

All patients included in the study had a pre-anesthetic consultation. They were given a complete clinical examination and a biological assessment, mainly the hemostasis assessment.

They were informed about the course of the examination and all gave their consent for the procedure. The operation was performed on patients fasting, under sedation or general anesthesia in dorsal or lateral decubitus position.

All patients who were going to benefit from a colonoscopy or low enteroscopy were given a preparation per 4 liters of polyethylene glycol.

A clinical and biological control in 15 days to one month was systematic in order to stratify the patients requiring a second APC session.

Inclusion Criteria

For Group A:

-Age >18 years.

-Pelvic radiotherapy

-Presence of rectorragies.

-To have a diagnosis of radiation rectitis established on the basis of the anamnesis data and the endoscopic aspect of the rectal mucosa.

For Group B:

-Age >18 years.

-Any patient presenting an externalized (upper/lower) or occult digestive hemorrhage, with the presence of angiodysplasia lesions during the endoscopic assessment of the digestive tract (esogastroduodenal fibroscopy, colonoscopy, enteroscopy, videocapsule).

Data Collection

The data collection was done on the medical records of the patients, who are hospitalized either 24 hours before the procedure, or on the same day (day hospital), on the other hand the technical part relating to the endoscopic procedure was filled in by the operator explaining the different steps of the endoscopic procedure.

The data that have been exploited are:

*Demographic data: -Age

-Sex

-Surgical history (Gastrectomy, operated gastric ulcer, lung cancer, prostate cancer, esophageal cancer, cervical cancer, rectal cancer, anal cancer, colon cancer, system disease, kidney failure, cirrhosis).

-Indication: Anemic syndrome, rectorragy, melena, hematemesis, epigastralgia.

***Endoscopic data:** -Number of lesions.

-Site of injury (Oesophagus, fundus, antrum, bulb, duodenum, jejunum, ileum, gastric stump, oeso-jejunal or gastro-jejunal anastomosis, afferent or efferent loop, cecum, colon, rectum).

-Presence or not of active bleeding

-Use of complementary endoscopic hemostasis (Clip) or not.

***Number of APC sessions**

***Prescription of an adjuvant medical treatment** (Corticotherapy or 5-aminosalicylated enemas) or not.

Statistical Analysis

We performed a two-step statistical analysis:

1. **A descriptive analysis** of our population including the different demographic, clinical and endoscopic variables:

a. **Qualitative:** in numbers and percentage

*Sex

*Clinical signs

*Site of the vascular malformation.

*Presence or not of active bleeding

*Use of complementary endoscopic hemostasis maneuvers

*Adjuvant medical treatment

b. Quantitative:

*Age (Mean \pm standard deviation)

*Number of lesions (Median [Interquartile range])

*Number of APC sessions (Median [Inter-quartile range])

2. **An analytical study was then carried out:**

The comparison of the quantitative variables with normal distribution was done by the Student's test.

The comparison of quantitative variables with an unsymmetrical distribution was done by the Man Whitney test.

The comparison of qualitative variables between two groups was done by the Chi-square or Fisher test.

A value of $p < 0.05$ was considered statistically significant.

The statistical analysis was performed using SPSS version 24.0 software.

Table 1 Patient Demographics:

Characteristics	Group A (n = 107)	Group B (n = 91)	p
Age	64,95 \pm 9,88	65,19 \pm 14,29	0,89
Sex: -Men	48(45,3%)	66(73,3%)	<0,0001
-Woman	58(54,7%)	24(26,7%)	

Our study has been approved by our hospital's ethics committee.

Results

The mean age of our patients was 64.95 \pm 9.88 years [43 - 83] in group A, with a sex ratio M/F of 0.82, while in group B the mean age was 65.19 \pm 14.29 years [40 - 91] with a clear male predominance in 72.5%. (**► Table 1**)

The majority of group A patients were followed for prostate cancer in 33.8% (n = 28), followed by cervical cancer in 33.8% (n = 22), while 13.8% (n = 9) and 4.6% (n = 3) had cancer of the rectum and bladder, respectively; and one patient had squamous cell carcinoma of the anus.

On the other hand, 26.3% (n = 5) of patients in group B had chronic renal failure, followed by cancer of the stomach in 15.8% (n = 3), and cancer of the esophagus in 10.5% (n = 2) (**► Table 2**).

The clinical symptomatology was dominated in group A by rectorragies in 40.2% (n = 43), an anemic syndrome in 3.7% (n = 4) and only one patient had melena of low abundance.

On the other hand, in group B, 46.8% (n = 49) of the patients had rectorragies, 35.8% (n = 33) had iron deficiency anemia, 32.6% (n = 30) had melenas, two patients had hematemesis and one patient had epigastralgia. (**► Table 3**).

The median number of APC sessions in both groups was 2.^{1,2}

The median number of lesions in each patient was 2.¹⁻³

The rectal injury was dominated in group A in 98.1% (n = 105), whereas in group B the lesions were mainly located in the stomach in 58.3% (n = 55), followed by the caecum in 30.9% (n = 25), the jejunum in 19.1% (n = 13) and the duodenum in 17.7% (n = 16).

The presence of active bleeding was without significant difference between the two groups: 10.7% in group A versus 11% in group B.

The use of adjuvant corticosteroid therapy or 5-ASA enema was only in group A in 4.7% (n = 5). Use of hemostatic clip was only in group B in 3.3% (n = 3) (**► Table 4**).

The endoscopic evolution was favorable in all our patients with a clear improvement of rectal lesions and digestive angiodysplasia lesions. The total complication rate in our series was nil.

Discussion

Vascular abnormalities of the gastrointestinal tract are a rare cause of digestive hemorrhage and pose a diagnostic and

Table 2 Patient medical and surgical history

Background	Group A (n = 107)	Group B (n = 91)	p
Gastrectomy		3(15,8%)	
Gastric ulcer operated		1(5,3%)	
Lung cancer		1(5,3%)	
Prostate cancer	28(43,1%)		
Cancer of the esophagus		2(2,2%)	<0,0001
Cervical cancer	22(33,8%)		
Rectal cancer	9(13,8)		
Anal cancer	1(1,5%)		
Colon cancer		1(1,1%)	
System disease		2(2,2%)	
Kidney failure		5(5,5%)	
Cirrhosis		1(1,1%)	

Table 3 Reason for patient hospitalization:

Clinical signs	Group A (n = 107)	Group B (n = 91)	p
Anemic Syndrome	4(3,7%)	33(35,8%)	
Melena	1(2,2%)	30(32,6)	
Rectragies	43(40,2)	49(46,8)	0,25
Hematemesis		2(2,2%)	
Epigastralgies		1(1,1%)	

Table 4 Endoscopic characteristics of patients

Characteristics	Group A (n = 107)	Group B (n = 91)	p
Number of lesions	2 [1-3]	2 [1-4]	0,019
Esophagus		4(4,4%)	
Fundus		27(29,7%)	
Antre		22(24,2%)	
Bulb		6(6,6%)	
Duodenum		10(11,1%)	
Jejunum		13(19,1%)	
Gastric stump		4(4,4%)	
Related/efferent handle		5(5,6%)	
Oeso-jejunal anastomosis		1(1,3%)	
Coecum		25(30,9)	
Straight colon		7(8,6%)	
Transverse colon		4(4,9%)	
Left colon	5(4,7%)	5(5,6%)	
Rectum	105(98,1%)	6(6,7%)	
Active bleeding	11(10,7)	9(11%)	0,9
Complementary endoscopic haemostasis maneuvers		3(3,3%)	0,09

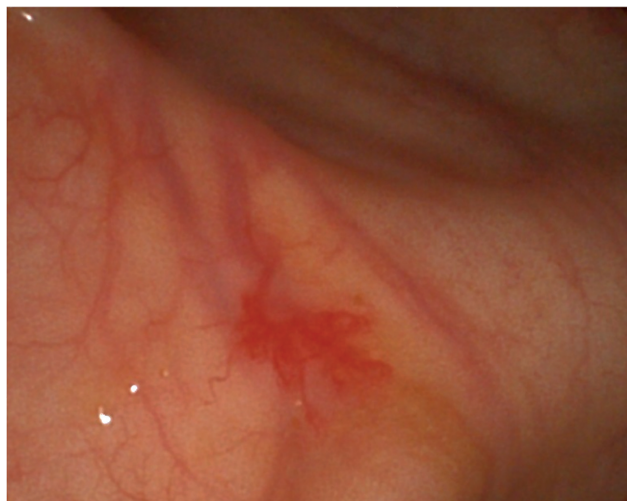

Fig. 1 Right colonic angiodysplasia (Image from the Hepato-Gastroenterology II department of Mohammed V Military Hospital).

therapeutic problem. They were first described in 1839, and in 1974 the term intestinal angiodysplasia (IA) was defined as a single or multiple superficial acquired vascular lesion developed in the mucosa and/or submucosa of the gastrointestinal tract wall, without being associated with a cutaneous or visceral angiomatous lesion.^{3,4}

Their prevalence in the general population is 0.83%,⁵ they are equally present in both sexes and are more frequent after the sixties.⁶

Various equivalent terms can be found in the literature: “arteriovenous malformation”, “telangiectasia” or “vascular ectasia”. On the other hand, intestinal angiodysplasias are to be differentiated from benign vascular tumors called hemangiomas or malignant tumors called angiosarcomas.

The typical appearance of an IA is that of a bright red, rounded, irregularly contoured, slightly raised, bright red “spot”, usually small, less than 10 mm in size (→ **Fig. 1**). A halo around the lesion is sometimes described, corresponding to a paler peri-lesional mucosa.

An IA corresponds histologically to a dilatation of the mucosal capillaries in communication with ectasic and tortuous submucosal veins (→ **Fig. 2**).

They account for 4% of the aetiologies of upper digestive haemorrhages.⁸

Gastric and/or duodenal localization is preferred, but they are more frequent in the small intestine⁹ and the colon, particularly in the ascending portion and in the cecum.

In our study the lesions were mainly located in the stomach in 58.3% followed by the coecum in 30.9%, the jejunum in 19.1% and the duodenum in 17.7%.

The development of endoscopy techniques and the quality of the video endoscopes used, particularly in terms of image resolution, make endoscopy the first avenue to follow for the diagnosis of IA; when located in the small intestine, diagnosis is made using endoscopic videocapsule or high or low enteroscopy.

It is not uncommon to miss some IA due to localization behind a fold or in the small intestine which is highly mobile, so there should be no hesitation to repeat endoscopic examinations when clinical suspicion is strong.¹⁰

Approximately 90% of IAs stop bleeding spontaneously,¹¹ but the risk of recurrence is high. This risk is between 25% and 65% depending on the studies.^{12,13} Surgical treatment is infrequent, up to 12% in some studies.¹³ Mortality from hemorrhagic IA is approximately 2%.¹⁴

In another retrospective study,¹⁵ haemorrhagic angiodysplasia was reported in 50% of the 261 patients investigated by double-balloon enteroscopy for unexplained digestive bleeding who were treated with argon plasma hemostatic therapy. The rate of hemorrhagic recurrence at 3 years was 46%, with a high number of vascular lesions and the presence of rhythmic and/or valvular heart disease being predictive factors for recurrence. In the colon, the rate of hemorrhagic recurrence after coagulation with argon plasma treatment ranged from 7% to 15% with a median follow-up of 6 to 20 months.¹⁶⁻¹⁸

In our study active bleeding was present in 11% of our patients; thus the use of hemostatic clip was present in only 3.3%.

The endoscopic evolution was favorable in all our patients with a clear improvement of rectal lesions and digestive angiodysplasia lesions. The total complication rate in our series was nil.

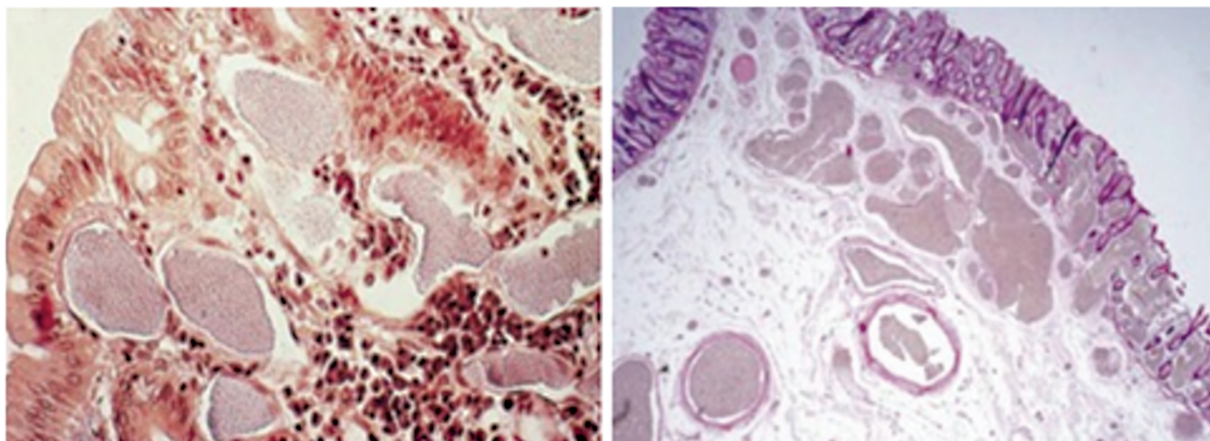


Fig. 2 Histological section of digestive angiodysplasia.⁷

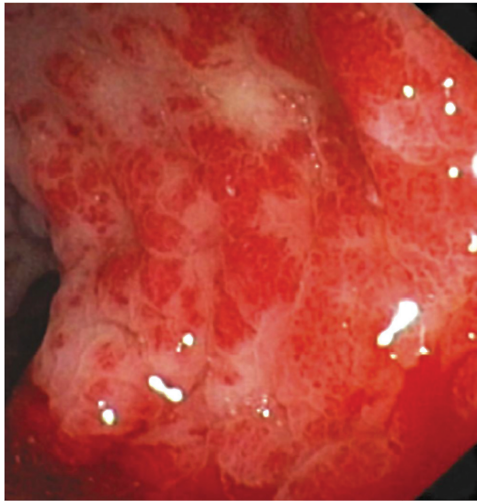


Fig. 3 Endoscopic aspect of a telangiectatic radiolucent rectitis.²³

On the other hand, the risk of occurrence of radiation rectitis increases above all with the dose of irradiation administered, the threshold dose is 45 grays. The risk is also influenced by the volume irradiated, the mode of radiotherapy (external irradiation or curietherapy), time fractionation and dose spread.^{19–21}

The main symptom of chronic radiation rectitis is rectorrages, but it can also be revealed by mucousy diarrhoea secondary to the chronic irritative phenomenon of the rectal wall, and can also be accompanied by anal incontinence or an anaemic syndrome.²²

The diagnosis of radiation rectitis is primarily endoscopic. The appearance of the rectal mucosa is variable. It may present in two ways: either by a mucosa covered with telangiectasia taking on the appearance of more or less regular, dilated and fragile, disseminated neo-vessels (► **Fig. 3**); or it may be diffusely congestive, friable and hemorrhagic at the slightest contact or spontaneously (► **Fig. 4**). In extreme cases one may find scattered ulcerations that may be superficial or deepening (► **Fig. 5**).

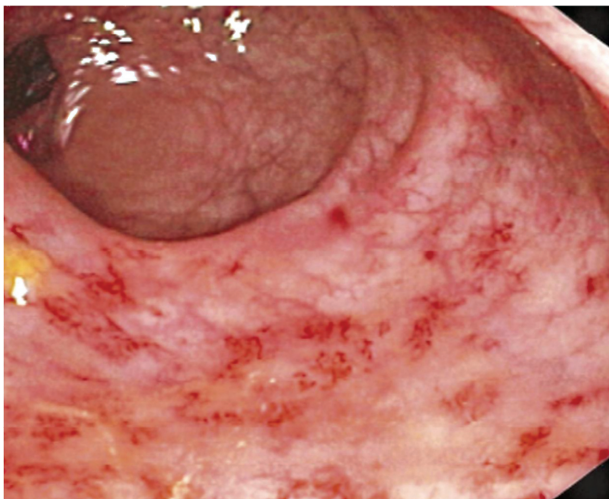


Fig. 4 Endoscopic aspect of diffuse congestive radioconjugate rectitis²³

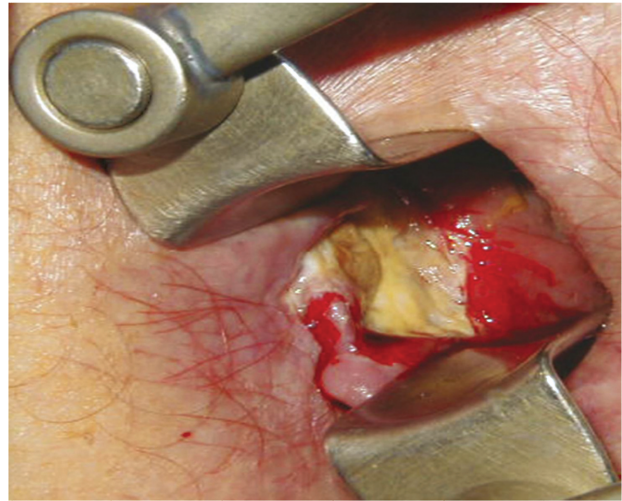


Fig. 5 Endoscopic appearance of an ulcerated radionuclide rectitis.³

Sometimes recto-vaginal or recto-vesical fistulas may occur secondary to the mucosal remodeling of the rays and its healing.

The treatment of choice for both digestive angiodysplasias and radiation rectitis is Argon Plasma Coagulation (APC),²⁴ except for asymptomatic non-haemorrhagic AIs, of incidental discovery, where therapeutic abstention is well recommended.²⁵ The main goal is to control bleeding and prevent recurrence.

The principle is based on the transformation of the energy produced by a high electric current into thermal energy, resulting in coagulation, debridement and/or desiccation of the tissues,²⁶ as the simultaneous release of an electric current and a gas argon, which in its ionized form will destroy, in a targeted and non-contact manner (3 to 5 mm of distance), the superficial mucosa (0.5 to 3 mm deep) by means of an electric arc (► **Figs. 6 and 7**).

The power of the generator should be adjusted according to the location of the angiodysplasia.²⁷ The recommended settings are (expert opinion): in the stomach: 0.8 L/min,

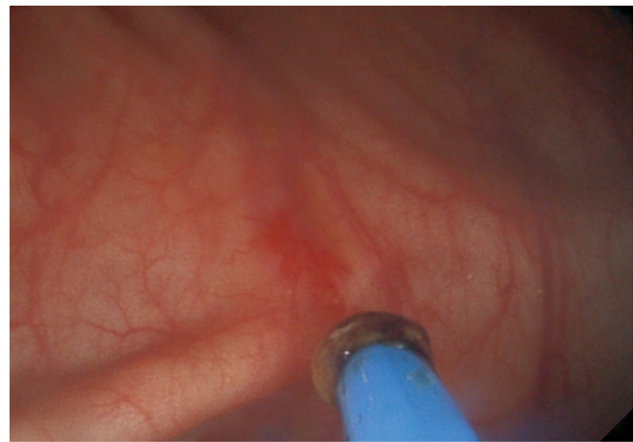

Fig. 6 APC probe at a distance from the mucosa (Image from the Hepato-Gastroenterology II department of Mohammed V Military Hospital).

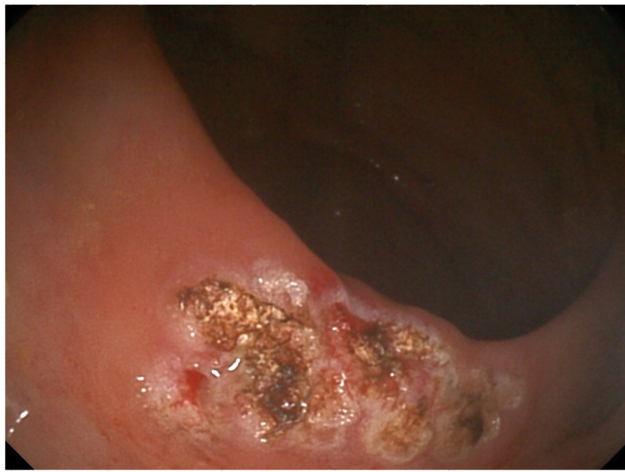


Fig. 7 Coagulated colonic angiodysplasia at the APC (Image from the Hepato-Gastroenterology II department of Mohammed V Military Hospital).

50W; in the esophagus, duodenum, small intestine, and right colon/cecum: 0.6 L/ min, 40W; in the left colon: 0.8 to 1 L/min, 50W.

May and al²⁸ showed in a recent retrospective series a significant reduction in transfusion requirements in 50 patients treated with argon plasma coagulation. However, recurrence of bleeding occurred in 42% of patients after a mean follow-up of 4.5 years.

Gerson and al²⁹ showed a similar rate of hemorrhagic recurrence (45%) 30 months after treatment of angiodysplasias.

Other studies³⁰⁻³² involving at least 300 patients have all reported argon plasma coagulation efficacy rates in the treatment of radiation proctitis of more than 80% on bleeding after an average of 1 to 3 sessions (extremes of 1 to 8), with complete or partial cessation of bleeding. Several sessions are often required, with a correlation between the number of sessions and the extent of the lesions to be treated.³³

However, a minimum delay of two to four weeks between two sessions is preferable in order to allow sufficient healing time.

The complication rate of argon plasma coagulation treatment ranges from 1.7% to 7% and includes fever with bacteremia, urinary disorders, ulceration, bleeding from pressure ulcer, rectal stenosis, microrectitis, recto-vaginal fistula, perforation, and intracolonic explosion.³⁴⁻³⁷

Perforation occurs preferentially in the cecum where the wall is thin. Some authors have proposed injecting saline, with or without adrenaline, into the submucosa to elevate the angiodysplasia before argon coagulation.^{38,39}

Finally, exceptional cases of explosions have been reported with the use of argon in ill-prepared patients.⁴⁰ It is therefore recommended that patients be prepared orally in order to obtain a perfectly clean colonic lumen.

Conclusion

Endoscopic treatment of digestive vascular abnormalities by argon plasma coagulation gives good results in terms of

efficacy, tolerance and safety, which proves its first-line indication in the management of digestive angiodysplasia and chronic haemorrhagic rectitis.

Conflict of Interest

No conflicts of interest

References

- Canard JM, Védrenne B, Bors G, Claude P, Bader R, Sondag D. [Long term results of treatment of hemorrhagic radiation proctitis by argon plasma coagulation]. *Gastroenterol Clin Biol* 2003;27(05): 455-459
- Roman S, Saurin JC, Dumortier J, Perreira A, Bernard G, Ponchon T. Tolerance and efficacy of argon plasma coagulation for controlling bleeding in patients with typical and atypical manifestations of watermelon stomach. *Endoscopy* 2003;35(12):1024-1028
- Gordon FH, Watkinson A, Hodgson H. Vascular malformations of the gastrointestinal tract. *Best Pract Res Clin Gastroenterol* 2001; 15(01):41-58
- Athanasoulis CA, Galdabini JJ, Waltman AC, Novelline RA, Greenfield AJ, Ezpeleta ML. Angiodysplasia of the colon: a cause of rectal bleeding. *Cardiovasc Radiol* 1977-19781(01):3-13
- Foutch PG, Rex DK, Lieberman DA. Prevalence and natural history of colonic angiodysplasia among healthy asymptomatic people. *Am J Gastroenterol* 1995;90(04):564-567
- Boley SJ, Brandt LJ. Vascular ectasias of the colon-1986. *Dig Dis Sci* 1986;31(9, Suppl)26S-42S
- Gordon FH and al. *Best Pract Res Clin Gastroenterol* 2001;15(01): 41-58
- Moretó M, Figa M, Ojembarrena E, Zaballa M. Vascular malformations of the stomach and duodenum: an endoscopic classification. *Endoscopy* 1986;18(06):227-229
- Leclaire S, Iwanicki-Caron I, Di-Fiore A, et al. Yield and impact of emergency capsule enteroscopy in severe obscure-overt gastrointestinal bleeding. *Endoscopy* 2012;44(04):337-342
- Sidhu R, Sanders DS, Morris AJ, McAlindon ME. Guidelines on small bowel enteroscopy and capsule endoscopy in adults. *Gut* 2008;57(01):125-136
- Richter JM, Christensen MR, Colditz GA, Nishioka NS. Angiodysplasia. Natural history and efficacy of therapeutic interventions. *Dig Dis Sci* 1989;34(10):1542-1546
- Junquera F, Feu F, Papo M, et al. A multicenter, randomized, clinical trial of hormonal therapy in the prevention of rebleeding from gastrointestinal angiodysplasia. *Gastroenterology* 2001;121(05):1073-1079
- Gupta N, Longo WE, Vernava AM III. Angiodysplasia of the lower gastrointestinal tract: an entity readily diagnosed by colonoscopy and primarily managed nonoperatively. *Dis Colon Rectum* 1995; 38(09):979-982
- Cappell MS, Gupta A. Changing epidemiology of gastrointestinal angiodysplasia with increasing recognition of clinically milder cases: angiodysplasia tend to produce mild chronic gastrointestinal bleeding in a study of 47 consecutive patients admitted from 1980-1989. *Am J Gastroenterol* 1992;87(02):201-206
- Samaha E, Rahmi G, Landi B, et al. Long-term outcome of patients treated with double balloon enteroscopy for small bowel vascular lesions. *Am J Gastroenterol* 2012;107(02):240-246
- Olmos JA, Marcolongo M, Pogorelsky V, Herrera L, Tobal F, Dávalos JR. Long-term outcome of argon plasma ablation therapy for bleeding in 100 consecutive patients with colonic angiodysplasia. *Dis Colon Rectum* 2006;49(10):1507-1516
- Olmos JA, Marcolongo M, Pogorelsky V, Varela E, Dávalos JR. Argon plasma coagulation for prevention of recurrent bleeding from GI angiodysplasias. *Gastrointest Endosc* 2004;60(06):881-886
- Rolachon A, Papillon E, Fournet J. Is argon plasma coagulation an efficient treatment for digestive system vascular malformation

- and radiation proctitis? *Gastroenterol Clin Biol* 2000;24(12):1205–1210
- 19 Hayne D, Vaizey CJ, Boulos PB. Anorectal injury following pelvic radiotherapy. *Br J Surg* 2001;88(08):1037–1048
 - 20 Reis ED, Vine AJ, Heimann T. Radiation damage to the rectum and anus: pathophysiology, clinical features and surgical implications. *Colorectal Dis* 2002;4(01):2–12
 - 21 Johnston MJ, Robertson GM, Frizelle FA. Management of late complications of pelvic radiation in the rectum and anus: a review. *Dis Colon Rectum* 2003;46(02):247–259
 - 22 Chutkan R and al, The argon plasma coagulation: a new and effectiveness modality for treatment of radiation proctitis, 1997, p. 45: AB27
 - 23 de Parades V, Bauer P, Girodet J, Marteau P, Parisot C, Atienza P. Traitement non chirurgical des rectites radiques chroniques. *Gastroenterol Clin Biol* 1998;22(8-9):688–696
 - 24 Vargo JJ. Clinical applications of the argon plasma coagulator. *Gastrointest Endosc* 2004;59(01):81–88
 - 25 Foutch PG. Angiodysplasia of the gastrointestinal tract. *Am J Gastroenterol* 1993;88(06):807–818
 - 26 Curtiss LE. High frequency currents in endoscopy: a review of principles and precautions. *Gastrointest Endosc* 1973;20(01):9–12
 - 27 Watson JP, Bennett MK, Griffin SM, Matthewson K. The tissue effect of argon plasma coagulation on esophageal and gastric mucosa. *Gastrointest Endosc* 2000;52(03):342–345
 - 28 May A, Friesing-Sosnik T, Manner H, Pohl J, Ell C. Long-term outcome after argon plasma coagulation of small-bowel lesions using double-balloon enteroscopy in patients with mid-gastrointestinal bleeding. *Endoscopy* 2011;43(09):759–765
 - 29 Gerson LB, Batenic MA, Newsom SL, Ross A, Semrad CE. Long-term outcomes after double-balloon enteroscopy for obscure gastrointestinal bleeding. *Clin Gastroenterol Hepatol* 2009;7(06):664–669
 - 30 Védrenne B, Canard JM, Denis B, Gay G, Sautereau D, Letard JC, and al. Endoscopic treatment of radiation proctitis. *Acta Endoscopica* 2005;35:703–35:704
 - 31 Maroy B, et al. Endoscopic treatment of rebellious hemorrhagic and ulcerated radiation proctitis by a new technique of electrocoagulation. *Gastroenterol Clin Biol* 1998;22:556–557
 - 32 Canard JM, Védrenne B. Clinical application of argon plasma coagulation in gastrointestinal endoscopy: has the time come to replace the laser? *Endoscopy* 2001;33(04):353–357
 - 33 Tjandra JJ, Sengupta S. Argon plasma coagulation is an effective treatment for refractory hemorrhagic radiation proctitis. *Dis Colon Rectum* 2001;44(12):1759–1765, discussion 1771
 - 34 KE., Grund. KE., Grund. 1997, *Endoscopy*, pp. 29:196–8
 - 35 Venkatesh KS, Ramanujam P. Endoscopic therapy for radiation proctitis-induced hemorrhage in patients with prostatic carcinoma using argon plasma coagulator application. *Surg Endosc* 2002;16(04):707–710
 - 36 Ravizza D, Fiori G, Trovato C, Crosta C. Frequency and outcomes of rectal ulcers during argon plasma coagulation for chronic radiation-induced proctopathy. *Gastrointest Endosc* 2003;57(04):519–525
 - 37 Sebastian S, O'Connor H, O'Morain C, Buckley M. Argon plasma coagulation as first-line treatment for chronic radiation proctopathy. *J Gastroenterol Hepatol* 2004;19(10):1169–1173
 - 38 Suzuki N, Arebi N, Saunders BP. A novel method of treating colonic angiodysplasia. *Gastrointest Endosc* 2006;64(03):424–427
 - 39 Norton ID, Wang L, Levine SA, et al. Efficacy of colonic submucosal saline solution injection for the reduction of iatrogenic thermal injury. *Gastrointest Endosc* 2002;56(01):95–99
 - 40 Ladas S-D, Karamanolis G, Ben-Soussan E. Colonic gas explosion during therapeutic colonoscopy with electrocautery. *World J Gastroenterol* 2007;13(40):5295–5298