



# Mandibular Advancement Appliances in Pediatric Obstructive Sleep Apnea: An Umbrella Review

Carolina Cozzi-Machado<sup>1</sup>  Fátima Rosana Albertini<sup>2</sup> Silvana Silveira<sup>1</sup> Almiro José Machado-Júnior<sup>3</sup>

<sup>1</sup>Postgraduate Program in Surgical Sciences, Department of Otorhinolaryngology, Head and Neck Surgery, Faculdade de Ciências Médicas (FCM), Universidade Estadual de Campinas (UNICAMP), Campinas, SP, Brazil

<sup>2</sup>Postgraduate Program in Child and Adolescent Health, Centro de Investigação em Pediatria (CIPED), Faculdade de Ciências Médicas (FCM), Universidade Estadual de Campinas (UNICAMP), Campinas, SP, Brazil

<sup>3</sup>Department of Otorhinolaryngology, Head and Neck Surgery, Faculdade de Ciências Médicas (FCM), Universidade Estadual de Campinas (UNICAMP), Campinas, SP, Brazil; Institute of Science and Technology, Universidade Estadual de São Paulo (UNESP), São José dos Campos, SP, Brazil

Address for correspondence Carolina Cozzi-Machado, MD, Postgraduate Program in Surgical Sciences, Faculdade de Ciências Médicas (FCM), Universidade Estadual de Campinas (Unicamp), Campinas, SP, Brazil (e-mail: cozzimachado@yahoo.com.br).

Sleep Sci 2023;16(4):e468–e475.

## Abstract

**Introduction** Obstructive sleep apnea (OSA) is defined as intermittent partial or complete collapse of the upper airway during sleep. It is a common condition in childhood, with an incidence ranging from 1.2% to 5.7%, and it can harm several aspects of children's life, such as cognitive, metabolic and cardiovascular functions, among others.

There are treatment options, such as adenotonsillectomy, myofunctional therapy, mandibular advancement appliances (MAAs), rapid maxillary expansion, and positive airway pressure devices, but there is still doubt about which method is more suitable for the treatment of OSA in children.

**Objective** To analyze the effectiveness of MAAs in the treatment of pediatric OSA.

**Materials and Methods** The search was conducted in August 2021 in different electronic databases, such as PubMed, EBSCO (Dentistry & Oral Sciences Source), LILACS, Ovid, SciELO, Web of Science, EMBASE BIREME, BBO BIREME, and the Cochrane Library.

**Results** Only three systematic reviews and two meta-analyses were included in the present study. All studies showed improvement in the score on the apnea-hypopnea index after using MAAs in the treatment of pediatric OSA.

**Conclusion** Although more randomized studies are needed, based on the present umbrella review, MAAs must be considered part of the multidisciplinary treatment for pediatric OSA.

## Keywords

- ▶ mandibular advancement
- ▶ obstructive sleep apnea
- ▶ children

## Introduction

Obstructive sleep apnea (OSA) is defined as intermittent partial or complete collapse of the upper airway during

sleep.<sup>1</sup> It is a common condition in childhood, with an incidence ranging from 1.2% to 5.7%,<sup>2</sup> and it can harm several aspects of children's life, resulting in attention deficit, learning delay, memory consolidation impairment, aggressive

received  
May 16, 2022  
accepted  
January 31, 2023

DOI <https://doi.org/10.1055/s-0043-1776747>.  
ISSN 1984-0659.

© 2023. Brazilian Sleep Association. All rights reserved.  
This is an open access article published by Thieme under the terms of the Creative Commons Attribution-NonDerivative-NonCommercial-License, permitting copying and reproduction so long as the original work is given appropriate credit. Contents may not be used for commercial purposes, or adapted, remixed, transformed or built upon. (<https://creativecommons.org/licenses/by-nc-nd/4.0/>)  
Thieme Revinter Publicações Ltda., Rua do Matoso 170, Rio de Janeiro, RJ, CEP 20270-135, Brazil

behavior,<sup>3,4</sup> metabolic disorders, cardiovascular disease, and nocturnal enuresis, for example.

Unlike the cases in adults, pediatric OSA is most related to adenotonsillar hypertrophy, which narrows the upper airway. Obesity is also among the main causes of pediatric OSA, but its complexity can also be explained by other factors, such as craniofacial type and neuromuscular tone.<sup>5</sup>

The choice of treatment for pediatric OSA considers age, severity of symptoms, clinical findings, presence of comorbidities and polysomnographic results.<sup>6</sup> Nowadays, there are many treatment options, such as adenotonsillectomy, myofunctional therapy, mandibular advancement appliances (MAAs), rapid maxillary expansion (RME), and positive airway pressure, but not all of them have the same efficacy and tolerance.

Adenotonsillectomy is still the most performed treatment in cases of pediatric OSA, and it has been highly effective throughout the years in non-obese children, even resulting in an improvement in oximetry results.<sup>7</sup> However, some studies<sup>8-10</sup> have reported that adenotonsillectomy is curative in 25% to 75% of the patients.

Continuous positive airway pressure (CPAP) is considered the first-line treatment in pediatric OSA without adenotonsillar hypertrophy, although with low tolerance (25% to 50%)<sup>11-13</sup> and risk of craniofacial sequels after long-term use.<sup>14,15</sup> Myofunctional therapy helps tongue repositioning, improves nasal breathing, and increases muscle tone, preventing residual apnea after adenotonsillectomy and increasing CPAP adherence.<sup>16</sup>

Another therapeutic resource can be found in MAAs: mandibular advancement is well established in adult OSA treatment; in children, the aim is to correct mandibular retrognathia through redirection and stimulation of anterior mandibular growth, in a passive or active manner, which can be achieved through different appliances, such as the Herbst, Frankel II, twin-block, and others.<sup>17</sup>

Functional orthopedic appliances have been used to treat mandibular retrognathia in children and teenagers and, recently, to treat OSA. They are able to increase upper airway space, reduce airway collapsibility, and improve muscle tone.<sup>18,20</sup> Thus one risk factor for adult OSA may have been solved.

The main goal of the present umbrella review was to analyze the effectiveness of MAAs in the treatment of pediatric OSA by means of apnea-hypopnea index (AHI) variability.

## Materials and Methods

The present umbrella review followed the checklist of the Preferred Reporting Items for Systematic Reviews and Meta-Analyses (PRISMA) statement.

### Inclusion Criteria

- Population: children and adolescents (age  $\leq$  18 years) diagnosed with OSA without craniofacial syndromes.
- Intervention: MAAs.

- Comparison: with and without a control group.
- Outcome: AHI.
- Study design: systematic review and meta-analysis.

### Search Strategy

A systematic search was conducted until August 2021 in the following electronic databases: PubMed, EBSCO (Dentistry & Oral Sciences Source), LILACS, Ovid, SciELO, Web of Science, EMBASE BIREME, BBO BIREME, and the Cochrane Library. The search terms were *sleep apnea, obstructive, OSA, sleep disordered breathing, mandibular advancement, oral appliances, mandibular protractor, orthodontic treatment, children, and pediatric*.

### Study Selection

Two reviewers (CCM and FRA) independently selected the articles, and only full-text articles were included.

### Data Collection

The following data were extracted from each study included: author, year of publication, study design, age of the sample, treatment, and AHI before and after MAAs.

### Risk of Bias in Individual Studies

To evaluate the risk of bias in individual studies, the University of Bristol's Risk of Bias in Systematic Reviews (ROBIS) tool was used. Two reviewers (CCM and FRA) independently evaluated the quality of the studies.

Both in terms of the criteria for the eligibility of studies and the methods, the articles included were considered to have low potential for bias. In the synthesis and results criterion, only one article was classified as presenting an unclear risk of bias. In the overall risk of bias assessment, the articles were classified as low risk, as they considered the heterogeneity of the data (**►Table 1**).

## Results

The flow chart of the selection process is illustrated in **►Figure 1**. A total of 36 articles were identified: 4 in EBSCO, 8 in PubMed, 8 in LILACS, 9 in EMBASE BIREME and BBO BOREME, 6 in the Cochrane Library, and 1 through other sources; 32 articles remained after duplicates were removed. Then, 27 articles were excluded after screening the titles, abstracts, study designs, and full text availability. Five articles remained: three systematic reviews and two meta-analyses.

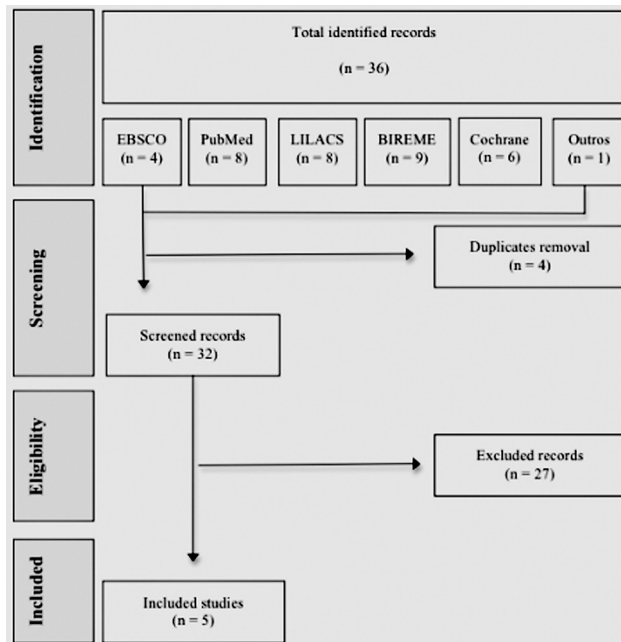
The results of the present umbrella review are organized in **►Table 2**, followed by the studies included in each systematic review and meta-analysis, in **►Table 3**. The selected articles were published between 2015 and 2021. The sample sizes ranged from 32 to 269 individuals aged between 3.5 and 14 years.

Several types of MAAs were used, such as single acrylic plate, twin-block, two acrylic plates (Planas), Herbst + RME, Bioadjusta X, modified monoblock, Myobrace/MyOSA, Andresen activator, Frankel II, and a thermoplastic intraoral appliance.

**Table 1** Risk of bias in the included studies according to the ROBIS tool.

Author/year	Eligibility	Identification and selection	Data collection	Synthesis and results	Risk of bias
Yanyan et al., 2019 <sup>17</sup>	Y/Y/Y/Y/PY Low	PY/NI/Y/Y/Y Low	Y/PY/Y/Y/Y Low	Y/Y/Y/PY/PN/PY Low	Low
Bariani et al., 2021 <sup>18</sup>	Y/PY/Y/Y/PY Low	PY/NI/Y/Y/Y Low	Y/Y/Y/NI/NI Low	Y/N/PY/Y/PN/N Unclear	Low
Nazarali et al., 2015 <sup>19</sup>	Y/Y/Y/Y/PY Low	PY/NI/Y/Y/Y Low	Y/Y/PY/Y/PY Low	Y/Y/PY/Y/PY/PY Low	Low
Carvalho et al., 2016 <sup>20</sup>	Y/Y/Y/Y/PY Low	PY/NI/Y/PY/Y Low	Y/Y/Y/Y/Y Low	Y/Y/Y/Y/Y/Y Low	Low
Huynh et al., 2015 <sup>21</sup>	Y/Y/Y/Y/PY Low	PS/S/S/S/S Low	Y/PY/PY/Y/PY Low	Y/Y/PY/Y/PY/Y Low	Low

Abbreviations: N, no; NI, no information; PN, probably no; PY, probably yes; ROBIS, Risk of Bias in Systematic Reviews; Y, yes.

**Fig. 1** Flow chart of the selection process of studies.

In addition, different protocols regarding the period of use were established, ranging from 3 weeks to 20 months. In most studies, the MAAs treatment had a minimum duration of 6 months, with the exception of a subgroup treated for 3 weeks in the study by Yanyan et al.<sup>17</sup> Long-term treatment (6 to 12 months) was more effective than short-term treatment. In general, MAAs were well tolerated in the pediatric population, with only 14 treatment dropouts (6 controls and 8 patients treated with MAAs), in the included studies.

All studies presented a reduction in the AHI after treatment with MAAs, except those in the study by Rădescu et al.<sup>31</sup> In two studies,<sup>18,19</sup> although there was a reduction in the AHI, it could not be statistically analyzed due to the considerable heterogeneity of the data. In the other 3 studies,<sup>17,20,21</sup> a reduction of at least 50% in the AHI was observed, which was considered as therapeutic success, even if the scores were not within the normal range.

## Discussion

In the last decade, several studies<sup>19,21</sup> have reported that multidisciplinary (including orthodontic) treatments for pediatric OSA can really improve not only snoring, but also apnea through growth balance correction.

Mandibular advancement combined with RME is an alternative treatment method for pediatric patients with sleep respiratory disturbances.<sup>17,21</sup>

In 1860, RME was reported for the first time as an orthodontic treatment for the correction of maxillary constriction. However, RME was linked to OSA treatment, since it was able to reduce, in children, nocturnal enuresis, a common OSA symptom. Nowadays, RME is often performed through a fixed intraoral orthodontic appliance, gradually adjusted throughout the treatment.<sup>21</sup>

According to Yanyan et al.,<sup>17</sup> high-quality meta-analyses support mandibular advancement in OSA patients, even in severe cases, as long as the treatment is established before pubertal peak. Long-term treatment (of at least 6 months) is superior to the short-term treatment. Mandibular advancement appliances improve the AHI and increase posterior airway space, reducing airway collapsibility. From the orthodontic perspective, MAAs also promote dentoalveolar changes and bone growth.<sup>17</sup>

Several factors contribute to OSA occurrence, such as obesity and adenotonsillar hypertrophy, conditions that narrow the superior airway. Other conditions are abnormalities in craniofacial growth, such as atresic maxilla, mandibular retrognathia, increased vertical growth, and neuromuscular disorders.<sup>18,20</sup>

A significant number of children do not respond to adenotonsillectomy, which is still the primary treatment for OSA, and most of them do not tolerate CPAP therapy. Therefore, functional orthopedic appliances, if correctly prescribed, are well tolerated and are able to increase airway space during sleep, reduce airway collapsibility, and improve muscle tone.<sup>18,20</sup>

As the functional appliance brings the jaw forward, an increase in the superior airway space occurs. Therefore, the

**Table 2** Characteristics of the meta-analyses and systematic reviews included in the present study.

Study	Study design	Age	Treatment duration	$\Delta$ AHI	AHI reduction (%)	Conclusion
Yanyan et al., 2019 <sup>17</sup>	Meta-analysis	No significant subgroup difference ( $I^2 = 0\%$ ; $p = 0.59$ )	Difference in treatment duration was observed: 3 weeks, 6 months, 10-12 months ( $I^2 = 65.9\%$ ; $p = 0.05$ ); long-term treatment (6 months, 10-12 months) may be more effective	-1.75 events/h (95% confidence interval: -2.07-1.44; $p = 0.00001$ )	50% for mild (1.72/3.5), 57% for moderate (4.27/7.5), and 76% for severe (10.69/14.08) cases	MAAs can be effective for mild to severe OSA before the end of pubertal peak; long-term treatment (of at least 6 months) may be more effective
Bariani et al., 2021 <sup>18</sup>	Systematic review	7.61 $\pm$ 1.99 years	7.71 $\pm$ 5.13 months	12 studies reported reduced AHI after treatment (could not be statistically analyzed due to the considerable heterogeneity of pooled data)	Could not be statistically analyzed due to the considerable heterogeneity of pooled data	FOA can be considered a potential additional treatment in children with OSA
Nazarali et al., 2015 <sup>19</sup>	Systematic review	8.71 $\pm$ 1.67 years	9.6 $\pm$ 2.89 months	Could not be statistically analyzed due to heterogeneity of pooled data	$\geq 50\%$ (1 study used RDI)	MAAs may improve AHI scores
Carvalho et al., 2016 <sup>20</sup>	Systematic review	7.1 $\pm$ 2.6 years	6 months	-4.5 events/h ( $p < 0.001$ )	50% in 9 of the 14 subjects	64.2% of success
Huynh et al., 2015 <sup>21</sup>	Meta-analysis	6.37 $\pm$ 1.72 years	6 months	-4.5 events/h; $p < 0.001$ (Villa et al. <sup>15</sup> ); -4.22 events/h; $p = 0.0003$ (Cozza et al. <sup>32</sup> )	$\geq 50\%$	MAAs can help in the management of pediatric snoring and OSA

Abbreviations: AHI, apnea-hypopnea index; FOA, functional orthodontic appliance; MAAs, mandibular advancement appliances; OSA, obstructive sleep apnea; RDI, respiratory disturbance index.

**Table 3** Characteristics of the studies included in the meta-analyses and systematic reviews selected for the present study.

Study	Study design	Subjects	Age	Interventions	Wearing time	Drop-out	Outcomes
Villa et al. 2002 <sup>22</sup>	Randomized controlled trial	MAAs: 19; control: 13	6.86 ± 2.34 years; 7.34 ± 3.10 years	An acrylic plate; no treatment	6 months (24h) –	5 4	MAAs: AHI from 7.1 to 2.6; control: unchanged
Nunes and Francisco-Mion, 2009 <sup>23</sup>	Randomized controlled trial	MAAs: 24; control: 16	6-9 years	Bioajusta X appliance; no treatment	6 months –	0 0	MAAs: improvements in breathing and snoring (questionnaire), airway space volumetric gain; control: airway space reduction
Machado- Júnior et al., 2016 <sup>24</sup>	Randomized controlled trial	MAAs: 8; control: 8	8.13 ± 0.99 years; 8.39 ± 1.31 years	Two acrylic plates; no treatment	12 months (24h)	0 2	MAAs: AHI from 1.66 to 0.30; control: AHI from 1.58 to 1.97
Idris G. et al., 2018 <sup>25</sup>	Crossover- Randomized controlled trial	MAAs: 9; control: 9	9.8 ± 1.1 years	Twin-block; sham MAAs	3 weeks overnight	3 0	MAAs: AHI from 2.8 to 1.9; control: AHI from 2.4 to 3.7
Cozza et al., 2004 <sup>26</sup>	Non-randomized controlled trial (prospective)	20	5.91 ± 1.14 years	Modified monobloc	6 months overnight	0	AHI from 7.88 to 3.66
Schütz et al., 2011 <sup>27</sup>	Non-randomized controlled trial (prospective)	16	12.6 years ± 11.5 months	Herbst + RME	12 months (24h)	0	AHI from 4.8 to 1.3 and airway space improvement
Zhang et al., 2013 <sup>28</sup>	Non-randomized controlled trial (prospective)	46	9.7 ± 1.5 years	Twin-block	10.8 months (24h)	0	AHI from 14.08 to 3.39 and airway space improvement
Levrini et al., 2018 <sup>29</sup>	Non-randomized controlled trial (prospective)	9	4-8 years	Myobrace /MyOSA	3 months	0	AHI reduction was statistically significant ( $p = 0.0425$ )
Maspero et al., 2015 <sup>30</sup>	Non-randomized controlled trial (prospective)	MAAs: 40; control: 10	9-14 years; 9-14 years	Andresen activator	16 months	0	AHI and airway space improvements
Rădescu et al., 2017 <sup>31</sup>	Case report	1	8 years	Twin-block	12 months	0	AHI increased from 2.6 to 10.2
Rose and Schessl, 2006 <sup>32</sup>	Case report	1girl and 1 boy	8 years and 6.5 years	Frankel II	20 Months and 9 months	0	Girl: AHI normalized; boy: less apnea and oxygen desaturation
Schessl et al., 2006 <sup>33</sup>	Case report	1	3.5 years	Frankel II	14 months	0	RDI from 66 to 2
Modesti- Vedolin et al., 2018 <sup>25</sup>	Pilot study	18	8.3 ± 2.3 years	Thermoplastic intraoral device (superior and inferior)	2 months	0	RDI from 10 to 4.5

Abbreviations: AHI, apnea-hypopnea index; MAAs, mandibular advancement appliances; RDI, respiratory disturbance index; RME, rapid maxillary expansion.

AHI will be improved, as long as the patient is wearing the appliance. Yet, if the etiology of the problem is retrognathia or maxillary constriction, skeletal and dentoalveolar correction must be achieved to complete correction of the malocclusion and stability of results.

If these changes are accomplished permanently, pediatric patients no longer need to wear the MAAS, since the skeletal growth is complete and this important OSA predisposing factor will be solved.<sup>19</sup>

Obstructive sleep apnea is related to many diseases and social problems. Many adults begin snoring and experiencing other respiratory disturbances, such as OSA, in childhood; hence, the relevance of early diagnosis and treatment to prevent long-term complications in adult life. These measures also contribute to reduce costs to the healthcare system and improve quality of life.<sup>20</sup>

The diagnosis of OSA is based on anamnesis, physical examination, and laboratory tests, and, to date, polysomnography is the gold-standard examination. Although adenotonsillectomy is widely performed to treat pediatric OSA around the world, recurrence is very common, particularly in children with skeletal deformities, such as mandibular retrognathia, maxillary constriction, or both.<sup>20</sup>

All studies included in the present review showed AHI reduction, except for Rădescu et al.,<sup>31</sup> who observed an AHI increase. An early orthodontic treatment with a functional appliance appeared to be an accurate device to correct the molar relationship and reduce overjet in children with retrognathic mandible, but, in this study,<sup>31</sup> the results were lower than expected, and the authors highlighted that pharyngeal surgery should be considered after anti-inflammatory therapies, and consultation with an otolaryngologist should be mandatory before the orthodontic treatment.<sup>31</sup> Nevertheless, we should emphasize that Rădescu et al.,<sup>31</sup> report a single case in their study.

Studies<sup>17-21</sup> were carried out with children who had not undergone adenotonsillar surgery. Zhang et al.<sup>28</sup> and Rose and Schessl<sup>32</sup> excluded children with adenotonsillar hypertrophy. Modesti-Vedolin et al.,<sup>34</sup> treated children in the Otolaryngology Service who were in the waiting list for amygdalotomy, and they observed a reduction in the respiratory disturbance index from 10 to 4.5/h. Villa et al.<sup>22</sup> included children with adenotonsillar hypertrophy and they still observed an improvement in the AHI, from 7.1 to 2.6/h, as well as a reduction in adenotonsillar hypertrophy after 6 months.<sup>22</sup>

Pediatric OSA often has a multifactorial etiology, which could justify cases of residual apnea in patients only submitted to one treatment modality, such as adenotonsillectomy. Nowadays, there are many treatment options, such as myofunctional therapy, adenotonsillectomy, CPAP, MAAs, and/or RME.

To establish an adequate treatment plan for pediatric OSA, the factors involved in airway obstruction must be identified, such as obesity, adenotonsillar hypertrophy, facial skeleton abnormalities etc.<sup>35</sup> According to what is found, it may be necessary to combine therapies to achieve cure.

Mandibular advancement appliances are well tolerated, even in treatments longer than 6 months, according to the

results of previous studies.<sup>28,30</sup> The Herbst appliance, for example, has intermaxillary anchorage; therefore, as it advances the mandible, it causes a contrary reaction of equal intensity in the upper dental arch. Since it is partially fixed to the teeth, it can work 24 hours a day and eliminate the chances of poor adherence to treatment. The two acrylic plates (Planas) consist of indirect tracks supported by metallic arches joining the upper and lower parts, which ensures the preservation of mandibular posture.

On the other hand, the twin-block consists of two (upper and lower) bite blocks with inclined planes, which are designed to fit together so that the mandible adopts an anterior position. The Frankel II appliance, unlike the Andresen activator, was not designed to move teeth by exerting pressure, but by controlling muscle pressures, thus inducing therapeutic changes.

Some possible side-effects related to the MAAs are more likely to happen in patients with Angle class-I and III malocclusion, because the mandibular advancement can lead class-I patients to class III, and, in the condition of class-III patients can be worsened by the mandibular advancement.<sup>36</sup> Mandibular advancement appliances may cause posterior dental disocclusion, orofacial and temporomandibular joint pain, and tooth breakage during mastication. All these undesirable effects are most common in the long-term treatment (of at least 5 years),<sup>36</sup> which exceeds the treatment period of the studies included in the present umbrella review.

Another aspect that should be considered is that MAAs may decrease the intraoral space for the tongue, which can be displaced backwards, leading to a collapse of the tongue base. Machado-Júnior et al.,<sup>24</sup> for example, took this aspect into account in their study, so their appliance, despite being based on the Planas device, was modified to minimize this possible undesirable effect. Occlusion between the plates and, consequently, mandibular advancement was achieved by means of two tracks built on the occlusal part of the apparatus, not on the lingual part, as recommended by Planas. Union between the two upper half arches was achieved not by means of an expansion screw as recommended by Planas, but by means of a Cofen spring.<sup>24</sup>

As a rule, functional orthopedics aims to guide the natural growth of the craniofacial skeleton, using the devices as translators of the forces of the muscles against the basal bones and the alveolar process.

The herein data obtained show that MAAs are a viable and complementary therapeutic resource for the treatment of OSA in children and adolescents with craniofacial disorders, such as those with Angle class-II malocclusion, maxillary narrowing, and mandibular retrognathia, which are very frequent alterations in mouth breathers. This emphasizes the importance of multidisciplinary treatment involving Otorhinolaryngology and Dentistry.

Although none of the studies included reported a cure for OSA (AHI < 1 event/h) after the use of MAAS, the reduction of at least 50% in respiratory events in children who had not undergone adenotonsillar surgery, associated with adherence, shows its effectiveness. However, the few studies

analyzed had small samples, except for the one by Bariani et al.,<sup>18</sup> in which the sample was larger, but the statistical analysis was not possible due to the heterogeneity of the data. Therefore, the results must be analyzed carefully. This is a relatively new field within sleep medicine, with many questions to be explained.

## Conclusion

Although more randomized studies are needed, based on the present umbrella review, MAAs must be considered part of a multidisciplinary treatment for children with OSA.

## Highlights

- Pediatric OSA often has a multifactorial etiology.
- It may be necessary to combine therapies to achieve cure.
- Mandibular advancement appliances are well tolerated and result in a reduction of at least 50% in respiratory events.
- Long-term treatment (from 6 to 12 months) is more effective.
- There is a lack of statistically significant data in this field.

### Conflict of Interests

The authors have no conflict of interests to declare.

## References

- 1 Tsara V, Amfilochiou A, Papagrigorakis JM, et al. Guidelines for diagnosing and treating sleep related breathing disorders in adults and children (Part 3: obstructive sleep apnea in children, diagnosis and treatment). *Hippokratia* 2010;14(01): 57–62
- 2 Marcus CL, Brooks LJ, Draper KA, et al; American Academy of Pediatrics. Diagnosis and management of childhood obstructive sleep apnea syndrome. *Pediatrics* 2012;130(03):e714–e755. Doi: 10.1542/peds.2012-1672
- 3 Lewin DS, Rosen RC, England SJ, Dahl RE. Preliminary evidence of behavioral and cognitive sequelae of obstructive sleep apnea in children. *Sleep Med* 2002;3(01):5–13. Doi: 10.1016/s1389-9457(01)00070-3
- 4 O'Brien LM, Mervis CB, Holbrook CR, et al. Neurobehavioral implications of habitual snoring in children. *Pediatrics* 2004; 114(01):44–49. Doi: 10.1542/peds.114.1.44
- 5 Behrents RG, Shelgikar AV, Conley RS, et al. Obstructive sleep apnea and orthodontics: An American Association of Orthodontists White Paper. *Am J Orthod Dentofacial Orthop* 2019;156(01): 13–28.e1. Doi: 10.1016/j.ajodo.2019.04.009
- 6 American Academy of Sleep Medicine. International classification of sleep disorders. 3rd ed. Darien, IL: American Academy of Sleep Medicine; 2014
- 7 Mitchell RB, Kelly J. Outcome of adenotonsillectomy for obstructive sleep apnea in obese and normal-weight children. *Otolaryngol Head Neck Surg* 2007;137(01):43–48. Doi: 10.1016/j.otohns.2007.03.028
- 8 Brietzke SE, Gallagher D. The effectiveness of tonsillectomy and adenoidectomy in the treatment of pediatric obstructive sleep apnea/hypopnea syndrome: a meta-analysis. *Otolaryngol Head Neck Surg* 2006;134(06):979–984. Doi: 10.1016/j.otohns.2006.02.033
- 9 Friedman M, Wilson M, Lin HC, Chang HW. Updated systematic review of tonsillectomy and adenoidectomy for treatment of pediatric obstructive sleep apnea/hypopnea syndrome. *Otolaryngol Head Neck Surg* 2009;140(06):800–808. Doi: 10.1016/j.otohns.2009.01.043
- 10 Tauman R, Gulliver TE, Krishna J, et al. Persistence of obstructive sleep apnea syndrome in children after adenotonsillectomy. *J Pediatr* 2006;149(06):803–808. Doi: 10.1016/j.jpeds.2006.08.067
- 11 Roberts SD, Kapadia H, Greenlee G, Chen ML. Midfacial and Dental Changes Associated with Nasal Positive Airway Pressure in Children with Obstructive Sleep Apnea and Craniofacial Conditions. *J Clin Sleep Med* 2016;12(04):469–475. Doi: 10.5664/jcsm.5668
- 12 Hawkins SM, Jensen EL, Simon SL, Friedman NR. Correlates of Pediatric CPAP Adherence. *J Clin Sleep Med* 2016;12(06): 879–884. Doi: 10.5664/jcsm.5892
- 13 Xanthopoulos MS, Kim JY, Blechner M, et al. Self-Efficacy and Short-Term Adherence to Continuous Positive Airway Pressure Treatment in Children. *Sleep* 2017;40(07):. Doi: 10.1093/sleep/zsx096
- 14 Tsuda H, Almeida FR, Tsuda T, Moritsuchi Y, Lowe AA. Craniofacial changes after 2 years of nasal continuous positive airway pressure use in patients with obstructive sleep apnea. *Chest* 2010;138(04): 870–874. Doi: 10.1378/chest.10-0678
- 15 Villa MP, Pagani J, Ambrosio R, Ronchetti R, Bernkopf E. Mid-face hypoplasia after long-term nasal ventilation. *Am J Respir Crit Care Med* 2002;166(08):1142–1143. Doi: 10.1164/ajrccm.166.8.257c
- 16 Koka V, De Vito A, Roisman G, et al. Orofacial Myofunctional Therapy in Obstructive Sleep Apnea Syndrome: A Pathophysiological Perspective. *Medicina (Kaunas)* 2021;57(04):323. Doi: 10.3390/medicina57040323
- 17 Yanyan M, Min Y, Xuemei G. Mandibular advancement appliances for the treatment of obstructive sleep apnea in children: a systematic review and meta-analysis. *Sleep Med* 2019; 60:145–151. Doi: 10.1016/j.sleep.2018.12.022
- 18 Bariani RCB, Bigliuzzi R, Cappellette Junior M, Moreira G, Fujita RR. Effectiveness of functional orthodontic appliances in obstructive sleep apnea treatment in children: literature review. *Rev Bras Otorrinolaringol (Engl Ed)* 2022;88(02):263–278. Doi: 10.1016/j.bjorl.2021.02.010
- 19 Nazarali N, Altalibi M, Nazarali S, Major MP, Flores-Mir C, Major PW. Mandibular advancement appliances for the treatment of paediatric obstructive sleep apnea: a systematic review. *Eur J Orthod* 2015 Dec;37(06):618–626. Doi: 10.1093/ejo/cju101. Epub 2015 Feb 12. PMID: 25681125
- 20 Carvalho FR, Lentini-Oliveira DA, Prado LB, Prado GF, Carvalho LB. Oral appliances and functional orthopaedic appliances for obstructive sleep apnoea in children. *Cochrane Database Syst Rev* 2016 Oct 5;10(10):CD005520. Doi: 10.1002/14651858.CD005520.pub3. PMID:27701747;PMCID: PMC6458031
- 21 Huynh NT, Desplats E, Almeida FR. Orthodontics treatments for managing obstructive sleep apnea syndrome in children: A systematic review and meta-analysis. *Sleep Med Rev* 2016 Feb;25:84–94. Doi: 10.1016/j.smr.2015.02.002. Epub 2015 Feb 17. PMID: 26164371
- 22 Villa MP, Bernkopf E, Pagani J, Broia V, Montesano M, Ronchetti R. Randomized controlled study of an oral jaw-positioning appliance for the treatment of obstructive sleep apnea in children with malocclusion. *Am J Respir Crit Care Med* 2002 Jan 1;165(01): 123–127. Doi: 10.1164/ajrccm.165.1.2011031. PMID: 11779741
- 23 Nunes WR, Francesco-Mion RCD. Early treatment and preventive strategies for obstructive sleep apnea and hypopnea with the bioajusta x orthodontic-orthopedic treatment. *Sleep Med* 2009; 10:541–542
- 24 Machado-Júnior AJ, Signorelli LG, Zancanella E, Crespo AN. Randomized controlled study of a mandibular advancement appliance for the treatment of obstructive sleep apnea in children: A pilot study. *Med Oral Patol Oral Cir Bucal* 2016 Jul 1;21(04):e403–e407. Doi: 10.4317/medoral.21072. PMID: 26946208; PMCID: PMC4920451
- 25 Idris G, Galland B, Robertson CJ, Gray A, Farella M. Mandibular advancement appliances for sleep-disordered breathing in children: A randomized crossover clinical trial. *J Dent* 2018

- Apr;71:9–17. Doi: 10.1016/j.jdent.2018.01.006. Epub 2018 Jan 31. PMID: 29357293
- 26 Cozza P, Polimeni A, Ballanti F. A modified monoblock for the treatment of obstructive sleep apnoea in paediatric patients. *Eur J Orthod* 2004 Oct;26(05):523–530. Doi: 10.1093/ejo/26.5.523. PMID: 15536841
- 27 Schütz TC, Dominguez GC, Hallinan MP, Cunha TC, Tufik S. Class II correction improves nocturnal breathing in adolescents. *Angle Orthod* 2011 Mar;81(02):222–228. Doi: 10.2319/052710-233.1. PMID: 21208073
- 28 Zhang C, He H, Ngan P. Effects of twin block appliance on obstructive sleep apnea in children: a preliminary study. *Sleep Breath* 2013 Dec;17(04):1309–1314. Doi: 10.1007/s11325-013-0840-5. Epub 2013 Apr 6. PMID: 23558604
- 29 Levrini L, Salone GS, Ramirez-Yanez GO. Efficacy of a Pre-Fabricated Myofunctional Appliance for the Treatment of Mild to Moderate Pediatric Obstructive Sleep Apnea: A Preliminary Report. *J Clin Pediatr Dent* 2018;42(06):475–477. Doi: 10.17796/1053-4625-42.6.14. Epub 2018 Aug 7. PMID: 30085867
- 30 Maspero C, Giannini L, Galbiati G, Kairyte L, Farronato G. Upper airway obstruction in class II patients. Effects of Andresen activator on the anatomy of pharyngeal airway passage. Cone beam evaluation. *Stomatologija* 2015;17(04):124–130. PMID: 27189498
- 31 Rădescu OD, Albu S, Baciut M, Bran S, Coman AC, Bechir ES, et al. Results in the treatment with twin block polymeric appliance of the retrognathic mandible in sleep apnea patients. *Rev Mater Plast* 2017;54:473–476
- 32 Rose E, Schessl J. Orthodontic procedures in the treatment of obstructive sleep apnea in children. *J Orofac Orthop* 2006 Jan;67(01):58–67. English, German. . Doi: 10.1007/s00056-006-0534-8. PMID: 16447025
- 33 Schessl J, Rose E, Korinthenberg R, Henschen M. Severe obstructive sleep apnea alleviated by oral appliance in a three-year-old boy. *Respiration* 2008;76(01):112–116. Doi: 10.1159/000098407. Epub 2007 Jan 5. PMID: 17202808
- 34 Modesti-Vedolin G, Chies C, Chaves-Fagundes S, Piza-Pelizzer E, Lima-Grossi M. Efficacy of a mandibular advancement intraoral appliance (MOA) for the treatment of obstructive sleep apnea syndrome (OSAS) in pediatric patients: A pilot-study. *Med Oral Patol Oral Cir Bucal* 2018 Nov 1;23(06):e656–e663. Doi: 10.4317/medoral.22580. PMID: 30341264; PMCID: PMC6260994
- 35 Kaditis A, Kheirandish-Gozal L, Gozal D. Algorithm for the diagnosis and treatment of pediatric OSA: a proposal of two pediatric sleep centers. *Sleep Med* 2012 Mar;13(03):217–227. Doi: 10.1016/j.sleep.2011.09.009. Epub 2012 Feb 1. PMID: 22300748
- 36 Karadeniz C, Lee KWC, Lindsay D, Karadeniz EI, Flores-Mir C. Oral appliance -generated malocclusion traits during the long-term management of obstructive sleep apnea in adults: A systematic review and meta- analysis. 316.1