



Congenital Sodium Diarrhea: Antenatal Diagnosis May Prevent Unnecessary Surgery in the Neonate

Dana S. Berger, MD¹  Virginia Tancioco, MD¹ Vineet K. Shrivastava, MD²

¹ Department of Obstetrics and Gynecology, University of California, Irvine, Orange, California

² Department of Obstetrics and Gynecology, Miller Children's and Women's Hospital, Long Beach, California

Address for correspondence Dana S. Berger, MD, Department of Obstetrics and Gynecology, University of California, 101 The City Drive South, Orange, CA 92868 (e-mail: danasenderoff@gmail.com).

AJP Rep 2023;13:e61–e64.

Abstract

Congenital sodium diarrhea (CSD) is a rare, life-threatening condition characterized by intractable diarrhea, hyponatremia, and metabolic acidosis. It presents similarly to other congenital disorders and, therefore, is often misdiagnosed and mistreated.

We present a case of CSD that presented with dilated loops of bowel and polyhydramnios at 18 weeks and was thought to be a congenital bowel obstruction. The patient was therefore managed surgically after birth with a diverting ileostomy, however was later found to have elevated stool sodium levels and metabolic derangements consistent with CSD.

Our case demonstrates the need for high index of suspicion for congenital diarrheal disorders to prevent unnecessary surgery and a delay in appropriate medical management of this rare condition.

Keywords

- ▶ congenital diarrhea
- ▶ congenital sodium diarrhea
- ▶ polyhydramnios
- ▶ dilated fetal bowel

Congenital sodium diarrhea (CSD) is a rare congenital diarrheal disease. Three genes (*SLC9A3*, *GUCY2C*, and *SPINT2*) have been implicated with CSD,^{1,2} all of which cause impaired sodium absorption leading to profuse diarrhea, severe hyponatremia, and metabolic acidosis. In the antepartum period, the disease presents with diffusely dilated loops of fetal bowel and polyhydramnios. However, these ultrasound findings are not unique to CSD, as they can also be found in fetuses with congenital bowel obstruction (i.e., secondary to bowel atresia) and other conditions that are treated surgically. On the other hand, CSD is treated medically with total parenteral nutrition (TPN). Thus, in the setting of polyhydramnios and multiple dilated loops of bowel, it is important to consider congenital diarrheal diseases in the differential to avoid potentially unnecessary surgery in the neonate.

Case

A 23-year-old gravida 3 para 0 was transferred to the perinatal group at 20 weeks for suspected fetal bowel atresia and polyhydramnios. Diagnostic amniocentesis demonstrated normal karyotype and chromosomal microarray. At 20^{3/7} weeks, ultrasound noted a deepest vertical pocket of 9.9 cm and significant diffuse bowel dilation. The bowel wall itself was not echogenic or thickened (▶ **Fig. 1**). Growth and anatomy were otherwise normal.

At 24^{1/7} weeks, the patient presented to triage with worsening dyspnea and inability to lie supine. The patient underwent ultrasound-guided amnioreduction for symptomatic polyhydramnios with removal of 3,700 mL of clear amniotic fluid that was discarded. She received a course of betamethasone for fetal lung maturity at this time as well.

received
October 12, 2020
accepted after revision
August 8, 2023

DOI <https://doi.org/10.1055/s-0043-1776148>.
ISSN 2157-6998.

© 2023. The Author(s).

This is an open access article published by Thieme under the terms of the Creative Commons Attribution-NonDerivative-NonCommercial-License, permitting copying and reproduction so long as the original work is given appropriate credit. Contents may not be used for commercial purposes, or adapted, remixed, transformed or built upon. (<https://creativecommons.org/licenses/by-nc-nd/4.0/>)

Thieme Medical Publishers, Inc., 333 Seventh Avenue, 18th Floor, New York, NY 10001, USA

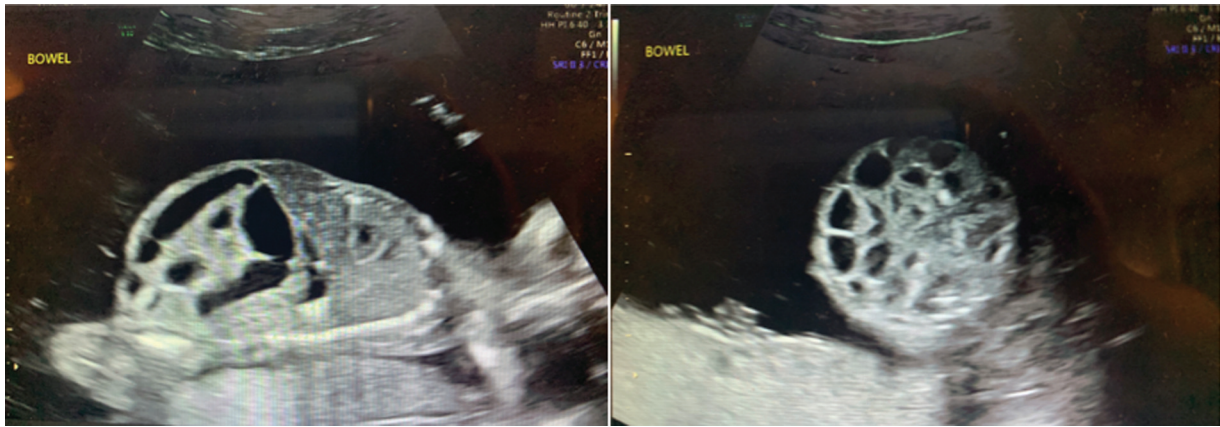

Fig. 1 Antenatal ultrasound at 20 3/7 weeks showing diffusely dilated fetal loops of bowel.

Serial amnioreductions were performed nine more times for maternal symptoms between 27^{4/7} and 31^{5/7} weeks, with amniotic fluid indices ranging from 25.7 to 47.4 cm and volume of amniotic fluid removed during the procedures ranging from 3,900 to 4,700 mL. Serial ultrasounds revealed normal fetal growth and continued to show diffusely dilated loops of bowel with normal peristalsis.

At 32^{0/7} weeks, the patient presented to triage for decreased fetal movement and was found to have fetal heart rate tracing with minimal variability and recurrent late decelerations. Given breech presentation, the patient underwent a primary low transverse cesarean delivery. A male infant weighing 2,605 g was born with Apgars of 3, 4, and 7 at 1, 5, and 10 minutes of life, respectively. The infant was found to have respiratory depression and severe abdominal distention (►Fig. 2).

On day of life 0, a transpyloric feeding tube was placed in the infant with return of 800 mL of serosanguinous fluid. Despite this intervention, the infant continued to have significant abdominal distention and on day of life 1 he underwent an exploratory laparotomy. Intraoperative findings included diffuse intestinal distention with fluid-filled

bowels without any areas of obstruction or atresia. The bowel was drained intraoperatively through a nasogastric tube and 1,500 mL of fluid were removed. There was no intraluminal meconium or stool noted. Ileal and rectal biopsies were sent to pathology who confirmed presence of ganglion cells. Given the peculiarity of the intraoperative findings, decision was made to perform diverting ileostomies with mucous fistulas. The intractable fluid that was removed was analyzed and found to have significantly elevated sodium levels (►Table 1).

The infant had persistent hyponatremia with a nadir of 122 (►Table 2) as well as metabolic acidosis with pH dropping to 6.72 on day of life 1 (►Table 3) requiring multiple boluses of normal saline and sodium bicarbonate.

Placenta pathology was significant for extensive dystrophic calcifications and subtrophoblastic basement membrane mineralization which has previously been described in certain cases of congenital abnormalities.^{3,4} After further genetic workup, the neonate was found to have a GUCY2C mutation and was diagnosed with nonsyndromic CSD. He was started on TPN, stabilized and transferred to a quaternary facility for a higher level of care, with eventual ostomy reversal.

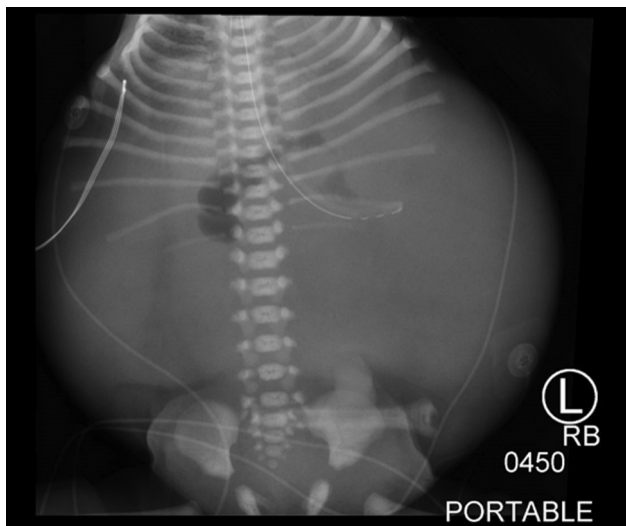


Fig. 2 Neonatal X-ray on day of life 0.

Discussion

CSD is a rare congenital diarrheal disease, with the first case described in 1985⁵ and less than 50 cases reported in the

Table 1 Intestinal fluid versus serum electrolyte levels

	Intraoperative (day of life 1)	Day of life 3	Day of life 7
Intestinal fluid			
Sodium level	142	139	153
Chloride level	99	103	105
Serum			
Sodium level	122	138	141
Chloride level	94	103	109

Note: All value are reported in mmol/L.

Table 2 Serum sodium versus chloride levels

	Day of life 0 09:15	Day of life 0 17:10	Day of life 1 04:45	Day of life 1 15:10	Day of life 1 19:55	Day of life 2 01:00	Day of life 2 06:00	Day of life 2 18:35
Sodium level	136	132	123	122	126	128	133	133
Chloride level	104	104	96	94	96	100	104	100

Note: Sodium reference range: 133–146 mmol/L. Chloride reference range: 96–111 mmol/L.

Table 3 Arterial blood gas showing metabolic acidosis

	Day of life 0	Day of life 1	Day of life 2
pH	7.11	6.72	7.25
pCO ₂ (mm Hg)	63	128	48
pO ₂ (mm Hg)	80	68	74
HCO ₃ (meq/L)	20	16	21
O ₂ saturation (%)	90	63	92

literature to date. The disease can further be differentiated into two forms: classical/nonsyndromic CSD and syndromic CSD. As Heinz-Erian et al described in 2009,¹ the syndromic form of CSD is caused by a loss of function mutation in *SPINT2* leading to CSD that is associated with choanal or anal atresia, hypertelorism, and corneal erosions. This is in contrast to the classical/nonsyndromic form of CSD, as diagnosed in this case. Nonsyndromic CSD is thought to be caused by a loss of function in the intestinal apical membrane Na⁺/H⁺ exchanger (NHE3)² as a result of mutations of *SLC9A3* or *GUCY2C*. NHE3 is responsible for sodium absorption in exchange for hydrogen and thus dysfunction of NHE3 leads to diarrhea, hyponatremia, and metabolic acidosis. Due to excessive diarrhea, neonates with CSD suffer from severe dehydration, electrolyte abnormalities, and metabolic acidosis that require immediate correction with TPN to improve morbidity and mortality.

CSD presents in the antenatal period as polyhydramnios with diffusely dilated loops of bowel; however, these findings are not unique to CSD and can also be found in fetuses with other types of congenital diarrheal diseases or structural abnormalities such as bowel atresia and intestinal obstruction. Although congenital diarrheas are rare, it is important that obstetricians consider this condition in patients who present with polyhydramnios and dilated loops of fetal bowel to optimize antenatal workup to aid in prenatal diagnosis.

On review of the literature there is some debate as to whether the diagnosis of CSD can be made antenatally. One author suggests that the degree of bowel dilation, whether it is focal or diffuse, can be predictive of either intestinal obstruction versus congenital diarrhea, respectively.⁶ Other authors propose that an assessment of the degree of peristalsis could be a discriminator, for example, increased peristalsis is suggestive of small bowel atresia where normal peristalsis is more consistent with a congenital

diarrhea. Furthermore, decreased or absent peristalsis maybe indicative of pseudo-obstruction.⁷ These evaluations are not ideal given their subjectivity; however, they may still provide insight that can guide antenatal workup. In our case, diffusely dilated loops of bowel with normal peristalsis were identified, which is more consistent with congenital diarrhea than intestinal obstruction by these measures.

Objective methods have also been proposed to aid in diagnosis of congenital diarrhea in the antenatal period. Mustafa and Al-Aali describe a honeycomb appearance of the fetal abdomen on ultrasound,⁸ representing diffuse dilation of the fetal bowel, which was observed in this patient (►Fig. 1B). Hirakawa et al successfully diagnosed congenital diarrhea antenatally using color Doppler sonography to demonstrate intraluminal streaming suggesting the frequent passage of stool (which is inconsistent with bowel obstruction).⁹ Another proposed method of antenatal detection is the use of fetal magnetic resonance imaging to evaluate the disappearance of the normal hypersignal in the colon on T1-weighted images that signifies meconium.¹⁰ This loss of signal is due to the replacement of normal meconium with heavily diluted watery diarrhea. One final method to consider in antenatal diagnosis of CSD is performing electrolyte analysis of the amniotic fluid. Elevated amniotic fluid sodium levels may suggest CSD; however, normal amniotic fluid sodium levels have been described in a prior case report of CSD and therefore should not rule out this diagnosis.⁷

Differentiating between congenital diarrhea and structural causes of polyhydramnios and dilated loops of bowel in the antepartum period is crucial given the importance of prompt medical management in the former versus surgical management in the later. Antepartum detection of congenital diarrhea has promise with both subjective and objective measures, however, requires initial clinical suspicion. We hope to increase awareness of the presentation of congenital diarrhea in the antenatal period to allow for earlier diagnosis and therefore improved neonatal outcomes in future cases.

Conflict of Interest

None declared.

References

- 1 Heinz-Erian P, Müller T, Krabichler B, et al. Mutations in *SPINT2* cause a syndromic form of congenital sodium diarrhea. *Am J Hum Genet* 2009;84(02):188–196

- 2 Janecke AR, Heinz-Erian P, Yin J, et al. Reduced sodium/proton exchanger NHE3 activity causes congenital sodium diarrhea. *Hum Mol Genet* 2015;24(23):6614–6623
- 3 Khan R, Sanders M, Ernst L, Egan J, Campbell W. Association between placental mineral deposition, villous architecture and fetal aneuploidy. *J Obstet Gynaecol* 2010;30(08):800–803
- 4 Ernst LM, Parkash V. Placental pathology in fetal Bartter syndrome. *Pediatr Dev Pathol* 2002;5(01):76–79
- 5 Holmberg C, Perheentupa J. Congenital Na⁺ diarrhea: a new type of secretory diarrhea. *J Pediatr* 1985;106(01):56–61
- 6 Langer JC, Winthrop AL, Burrows RF, Issenman RM, Caco CC. False diagnosis of intestinal obstruction in a fetus with congenital chloride diarrhea. *J Pediatr Surg* 1991;26(11):1282–1284
- 7 Lee DH, Park YK. Antenatal differential diagnosis of congenital chloride diarrhea: a case report. *J Obstet Gynaecol Res* 2012;38(06):957–961
- 8 Mustafa OM, Al-Aali WY. Honeycomb fetal abdomen: characteristic sign of congenital chloride diarrhea. *Ultrasound Obstet Gynecol* 2016;48(06):797–799
- 9 Hirakawa M, Hidaka N, Kido S, Fukushima K, Kato K. Congenital chloride diarrhea: accurate prenatal diagnosis using color Doppler sonography to show the passage of diarrhea. *J Ultrasound Med* 2015;34(11):2113–2115
- 10 Colombani M, Ferry M, Toga C, et al. Magnetic resonance imaging in the prenatal diagnosis of congenital diarrhea. *Ultrasound Obstet Gynecol* 2010;35(05):560–565