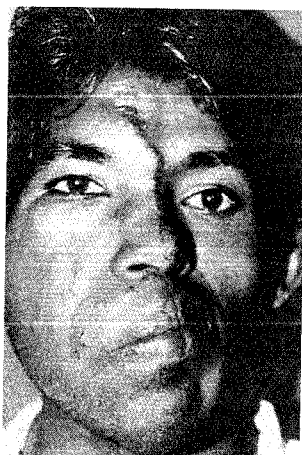



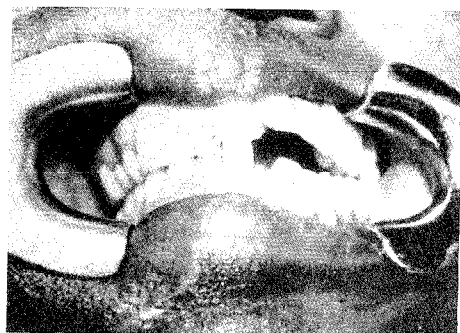## HEMIFACIAL HYPERPLASIA - A CASE REPORT

Sanjeev N Deshpande and Leena Deshpande  
Lokmanya Tilak Municipal Medical College and General Hospital, Bombay

**SUMMARY :** Hemifacial hyperplasia is a rare congenital deformity, affecting soft and bony tissues of one half of the face. The etiology of the condition is unknown and no pattern of heredity is described. A case of hemifacial hyperplasia and its management is described here.



(Fig - 1) Preoperative profile



(Fig - 2) Pre operative Dental Occlusion

### CASE REPORT

A 25 year old gentleman from the southern part of India presented with overgrowth of the right side of the face involving bony as well as soft tissues. The two sides of the face were clearly demarcated by a midline linear epidermal nevus seen on the forehead, dorsum of the nose, columella and upper lip. There were few epidermal growths on the right nasolabial area and right cheek (Fig. 1). Due to excess growth of the bony and soft tissues on the right side, the nose and mouth were deviated to the left side. The right angle of the mouth was shifted down. There was bulging of right side of forehead and right eye was placed high as compared to the left. The right auricle was normal in size and shape.

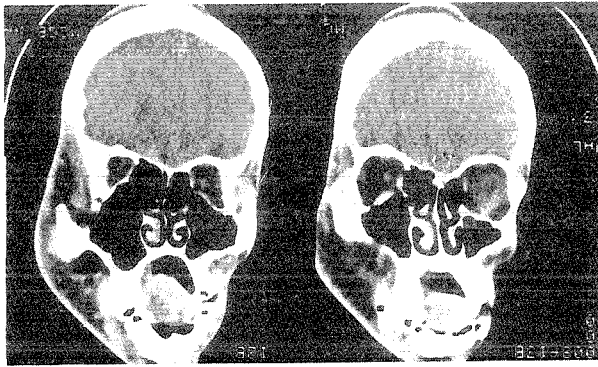
Intraoral examination revealed macrodontia of maxillary incisors and canines on affected side. Due to excess growth of maxilla and mandible, there was premature occlusion on the right side resulting in open bite deformity on left side (Fig. 2). There was macroglossia of right side of the tongue.

Plain x-rays of the skull and 2D CT scan confirmed excess growth of the frontal bone, zygoma, maxilla and mandible on the right side. The frontal sinus and the maxillary sinus were widened on the right side. Although the orbit size was equal on both sides, the right orbit was placed at a higher level as compared to the left side (Fig. 3).

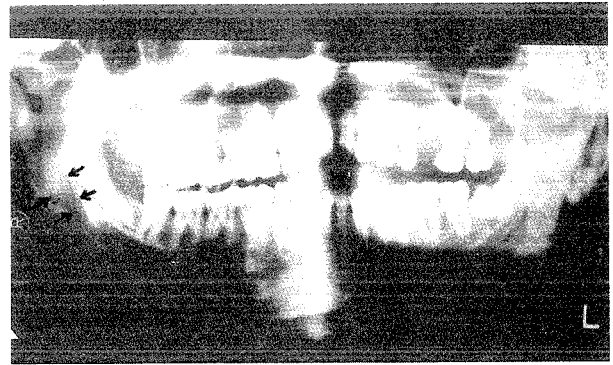
Orthopantomogram showed macrodontia of maxillary teeth (Fig. 4). There was hypertrophy of the condyle and coronoid process of mandible on the right side. There was gross widening of the inferior alveolar canal on the right side.

The following management was carried out:

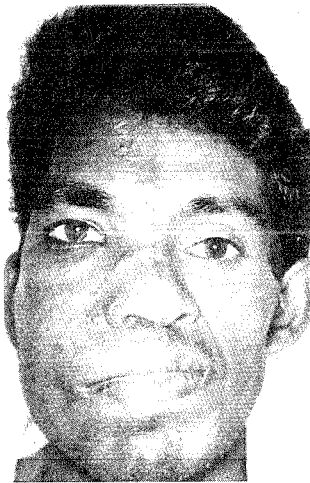- 1) LeFort 1 osteotomy with wedge resection was done on the right side of the maxilla, which



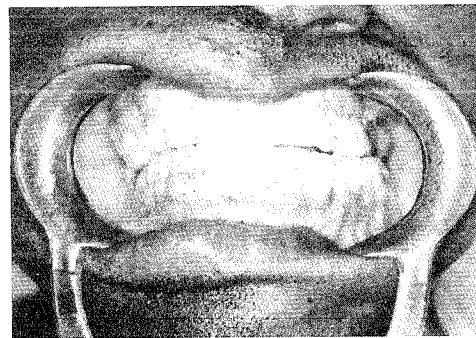
(Fig - 3) CT Scan showing hyperplastic skull bones, zygoma, maxilla and mandible on the right side. Widened ethmoid and maxillary sinuses are seen.



(Fig - 4) Orthopantomogram showing Hypertrophied Condyle and Coronoid Process of right side of mandible. Widened Inferior Alveolar Canal



(Fig - 5) Postoperative profile



(Fig - 6) Postoperative dental occlusion

corrected the open bite deformity on the left side. Since his dental anomalies were not amenable to any orthodontic correction, final dental occlusion was obtained by carrying out dental bridge work. Shaving of the frontal bone, lateral wall and floor of orbit, zygoma and lower border of mandible was done.

- 2) Debulking of the soft tissues on the right side of the face was done by excising excess skin and subcutaneous tissue. The midline naevus was excised by "Z" plasty technique. Excision of epidermal growths from right nasolabial area and cheek was done. To lift up the right angle of the mouth, a fascia lata sling was used from the angle of mouth to zygomatic arch.

Postoperatively reasonably good symmetry of the face was obtained (Fig. 5). Dental occlusion though acceptable was not ideal (Fig. 6).

Surgical correction of the deviated bony nasal framework and orbital discrepancy will improve the correction achieved.

## DISCUSSION

Hemifacial hyperplasia is a rare congenital anomaly of the face affecting the soft tissues and the bony tissues of the face. Sometimes it may be associated with excess growth of the upper extremity or lower extremity on the affected side or there may be hyperplasia of complete hemitorso. There are several conditions which resemble this condition like fibrous dysplasia of face, neurofibromatosis of the face or unilateral condylar hyperplasia<sup>1,2</sup>. Pollack et al<sup>3</sup> emphasized the fact that radiological identification of enlarged foramina of the craniofacial skeleton is the pathognomonic sign of true congenital hemifacial hyperplasia. Even though etiology of the condition is unknown and no

pattern of heredity is described, Pollack et al<sup>3</sup> postulated that hyperplasia of neural crest cells may be the likely cause of this condition. Rowe<sup>4</sup> in reviewing the literature on this subject found the condition more prevalent in males than females and also found that involvement of right side of the face was more common than the left side. The asymmetry worsens with the growth of face during puberty and then ceases with skeletal maturation around 17 to 18 years of age.

Identification of enlarged foramina of the craniofacial skeleton by radiological investigation confirms the diagnosis. CT scan helps in detecting hyperplasia of the body viscera. Lateral cephalogram and orthopantomogram are required for planning the treatment modalities.

Management of such cases is mainly carried out for aesthetic considerations and for correction of the dental malocclusion. Soft tissue debulking is done by excising excess skin and subcutaneous tissue. Superficial parotidectomy is done in some cases depending on the severity of hyperplasia. Bony correction consists of several procedures like shaping of the overgrown bones, orthognathic correction of jaws after orthodontic correction of malaligned teeth. Orbital dystopia needs major transcranial correction.

Even though perfect symmetry is difficult to achieve, reasonably good aesthetic correction can

be obtained with the above protocol. With the introduction of craniofacial techniques, there has been improvement in the correction of the asymmetry.

#### Acknowledgement

Our thanks to Hony Professor and Head, Department of Plastic and Reconstructive Surgery, Lokmanya Tilak Municipal Medical College and General Hospital, Sion, Bombay under whose supervision part of the surgical work was carried out.

#### References

- 1 McCarthy JG. Plastic Surgery; 2:part 1 Philadelphia WB Saunders Company; 1990:1300-1301
- 2 Hester TR. Hemifacial Hyperplasia In: Mustarde JC and Jackson IT Eds, Plastic Surgery in Infancy and Childhood 3rd Ed. Edinburgh: Churchill Livingstone, 1988:409-419
- 3 Pollack RA, Newman MH, Burdi AR and Condit DP. Congenital Hemifacial Hyperplasia: an Embryonic Hypothesis and Case Report. Cleft Palate J 1985; 22:173-181
- 4 Rowe NH. Hemifacial Hyperplasia. Oral Surgery 1962; 15:572-587

#### Authors

**Dr Sanjeev Deshpande, MS, M Ch**, Consultant Plastic & Craniofacial Surgeon

**Dr Leena Deshpande, MDS**, Consultant Dental Surgeon

Lokmanya Tilak Municipal Medical College and General Hospital, Bombay

Requests for reprints to Dr Sanjeev Deshpande, A/39 "Sneh Varsha", Parsiwada, Sahar Road, Andheri(E), Bombay 400 099