



## LOWER ABDOMINAL WALL RECONSTRUCTION WITH SUPERCHARGED REVERSE LATISSIMUS DORSI MUSCLE FLAP: A CASE REPORT

A K Gupta, B L Chitlangia and S Jain  
 Bombay Hospital and Medical Research Center, Bombay

**SUMMARY :** *Abdominal wall reconstruction entails usage of ingenious techniques to support and protect abdominal viscera as well as provide an aesthetic contour. This is a case report wherein the lower abdominal wall was reconstructed with an ipsilateral, supercharged, reverse latissimus dorsi muscle flap with skin graft.*

*Such innervated motor muscle transfer by its dynamic role ensures prevention of ventral herniation of the abdominal viscera. Supercharging of vascularity and innervation of an inferiorly based latissimus dorsi muscle is a useful addition to existing methods of abdominal wall reconstruction.*

### INTRODUCTION

Reconstruction of major defects of the anterior abdominal wall involves use of a strong autogenous tissue or synthetic material to provide the desired strength. Surgical techniques, using skin grafts<sup>1</sup> or local flaps<sup>2-5</sup> have been used with limited success. Use of fascio-cutaneous or muscle flaps from the thigh<sup>6-8</sup> have limitations of reach and strength.

Use of latissimus dorsi muscle or myocutaneous flap, based on thoracodorsal vessel, for upper/lower abdominal wall reconstruction has been described by various authors<sup>9-12</sup>. The arc of rotation of proximally based latissimus dorsi flap is limited, suitable for covering defects in the

supra-umbilical region (Fig.1).

A supercharged reverse latissimus dorsi muscle flap can be used for dynamic reconstruction of a massive total anterior abdominal wall defect in the infra-umbilical region.

### CASE REPORT

A 25 year old male presented with a massive abdominal wall defect with ventral hernia. The patient had a history of postoperative progressive synergistic gangrene (necrotizing fasciitis) following laparotomy for an acute abdominal pathology in childhood. The abdominal wall defect was then salvaged with skin grafts. Over a period of time he had developed a huge ventral hernia (Fig.2). The

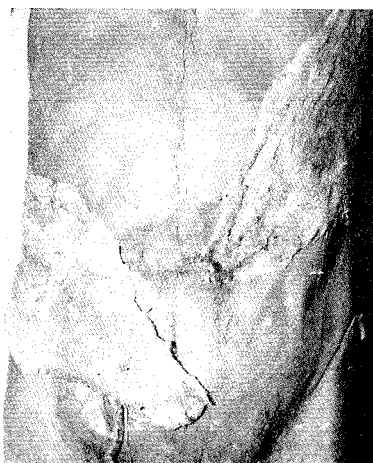

Fig.1 Cadaveric dissection showing the arc of rotation of latissimus dorsi muscle based on the thoracodorsal vessel. Left side : It covers supra-umbilical region based on paraspinal perforators. Right side: It reaches to the infra-umbilical region.

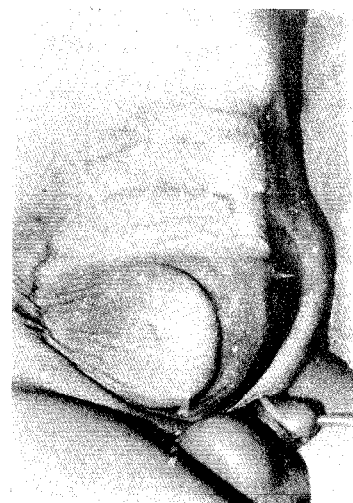


Fig.2 Preoperative photograph of the patient showing a huge ventral hernia

abdominal wall defect comprised of loss of external oblique muscle, internal oblique muscle, rectus abdominis and transversalis muscles on the right side and part of rectus abdominis muscle and its sheath on the left side. Movements of loops of small intestine could be visualized under the matured skin graft.

The reconstructive surgery was performed under continuous epidural anaesthesia with local anaesthetic supplementation in the axilla. Skin graft and fibrous tissue adhesions at the hernia site were fully excised and all peritoneal rents at various places were repaired using absorbable sutures. The peritoneum was then covered with a marlex mesh, which was secured to the part of external oblique and rectus abdominis muscles on the superior and medial aspects respectively. The lateral and inferior margins of the mesh were left unsutured at this stage. The patient was then turned to the lateral position for the dissection of latissimus dorsi muscle flap. By an incision along the posterior axillary fold, the latissimus dorsi muscle flap was raised, keeping its thoracodorsal pedicle and lumbar and paraspinal perforators intact. The entire length of the muscle was freed from its skin and sub-muscular attachments. A subcutaneous tunnel was created, connecting the lateral edge of the abdominal wall defect to the incision for harvesting of the latissimus dorsi muscle, along the posterior axillary fold. Haemostasis was achieved and the flap was wrapped in warm sponges. The patient was then turned supine and the marlex mesh was secured on to the lateral aspect of the abdominal wall defect. The thoracodorsal pedicle and tendinous insertion of the latissimus dorsi muscle were

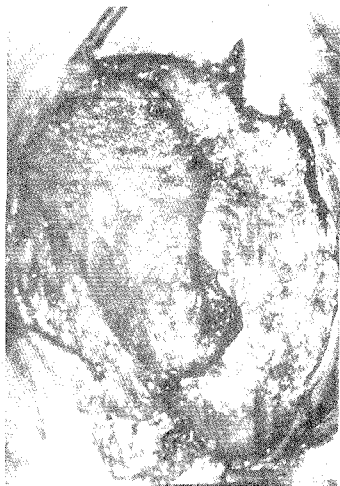

Fig.3 Intra-operative photograph showing distally based latissimus dorsi muscle tunneled into the abdominal wall defect

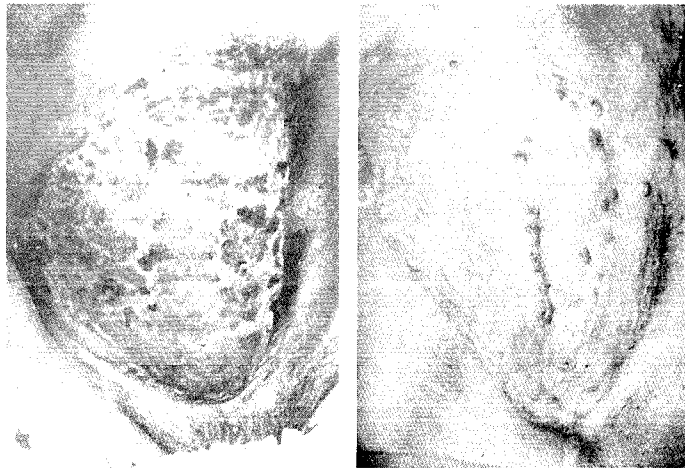
then cut and thereafter the flap was delivered into the abdominal wall defect, through the subcutaneous tunnel made earlier (Fig.3). Thereafter the incision on the chest for dissection of the latissimus dorsi muscle flap was sutured in layers.

The reversed latissimus dorsi muscle flap was sutured to part of the rectus abdominis muscle on the left side and thin remains of external oblique muscle superiorly. The flap was supercharged by anastomosing thoracodorsal vessels to femoral vessels (artery and vein : end to side), as both the superficial and the deep inferior epigastric arteries were not suitable for microvascular anastomosis on the affected side. The cyanosed and turgid appearance of the latissimus dorsi muscle (after division of its thoracodorsal pedicle) was immediately relieved on vascular supercharging. The neural supercharging was performed by microneural co-aptation between ilio-inguinal and ilio-hypogastric nerves and the nerve to latissimus dorsi muscle. Meshed unexpanded skin graft, without tie-over dressing, was applied on to the muscle flap. The postoperative period was uneventful. Skin graft take was good.

The patient underwent physiotherapy for strengthening the abdominal muscles and electrical stimulation to the transposed latissimus dorsi muscle, from 6 weeks onwards.

At one year follow up the patient presented with a small hernia in the inguinal region while in rest of the area there was no recurrence. The skin graft had matured fully and there were strong muscle contractions at the original abdominal wall defect site on voluntary contraction of the muscle. It was decided to explore and re-attach the lower edge of the mesh into the groin area, which was probably left loose at the site of microneurovascular supercharging, during the first operation. On exploration it was heartening to note the bulk of the transferred muscle and strong contractions on direct electrical stimulation. There was a small rent between the lower edge of the mesh and the fibrous tissue band simulating the inguinal ligament. The defect was reinforced with an additional piece of mesh and rotation advancement of the tendinous part of the latissimus dorsi muscle. Simultaneously, revision of abdominal scars was performed. At two years follow up there is no recurrence of abdominal hernia and the patient has got an excellent aesthetic contour (Fig. 4).

EMG studies performed on the transposed muscle showed signs of re-innervation and contractility comparable to the contralateral latissimus dorsi



(Fig - 4) Follow up pictures a) Early result b) at 2 years

muscle.

#### DISCUSSION

Reconstruction of small defects of lower abdominal wall has attracted use of a number of flaps from the thigh which have limitations of size and reach. Inferiorly based supercharged latissimus dorsi flap is a robust flap suitable for reconstruction of a relatively large defect of the abdominal wall. Possibility of motor reinnervation of this flap helps in maintaining its tone and bulk which are important for the prevention of recurrence of the hernia. Supercharging or enhancing the vascular and neural supply of reverse latissimus dorsi muscle flap has extended its reach and application for abdominal wall reconstruction from upper and middle abdominal wall to lower abdominal wall defects. Dual blood supply, strong distal attachments to lumbar spine and iliac crest and possible motor innervation through lumbar perforators and supercharged neural co-aptation have made this flap very useful in the repair of extensive abdominal wall defects. The donor site morbidity is insignificant and possibilities of complications are relatively negligible.

#### References

- 1 **Dervin AS and Fischer RP.** The Reconstruction of Abdominal Wall with Split Skin Graft. *Surg Gynaecol. Obstet* 1982; 55:413-414.
- 2 **Bogart JN, Rowe DS and Parsons RW.** Immediate Abdominal Wall Reconstruction with Bilateral Groin flaps after resection of large desmoid tumour. *Plast Reconstr Surg* 1976; 58:716-718.
- 3 **Taylor GI, Corlett RJ and Boyd JB.** The Extended Deep

Inferior Epigastric Flap - A Clinical Technique. *Plast Reconstr Surg* 1983;19:475-477.

- 4 **Iwahiro Y, Maruyama Y and Shiba T.** One Stage Abdominal Wall Reconstruction with Oblique Abdominal Fasciocutaneous Flaps. *Ann Plast Surg.* 1987;19:475-477.
- 5 **Mathes SJ and Bostwick J.** A Rectus Abdominis Flap to Reconstruct Abdominal Wall Defect. *Br J Plast. Surg.* 1977; 30:282-285.
- 6 **O'Hare PM and Leonard AG.** Reconstruction of Major Abdominal Wall Defects using Tensor Fascia Lata Myocutaneous Flap. *Br J Plast. Surg.* 1982;35:361-366.
- 7 **Cafe HH.** Reconstruction of Abdominal Wall by Variation of Tensor Fascia Lata Flap. *Plast. Reconstr. Surg.* 1983; 71:348-351.
- 8 **Siberman DA, Elliott LF and Hoffman GW.** Extended Myofacial Thigh Flaps for Repair of Large Full Thickness Abdominal Wall Defects. *Ann Plast Surg* 1985;15:170-176.
- 9 **Bostwick J.** The Reverse Latissimus Dorsi Muscle and Musculo-cutaneous flap - Anatomical and Clinical Considerations. *Plast Reconstr Surg* 1980;65:395-399.
- 10 **Houston CG, Drew GS and Vazquez B.** The Extended Latissimus Dorsi Flap in Repairs of Anterior Abdominal Wall Defect. *Plast Reconstr Surg* 1988;81:917-923.
- 11 **Sharma RK, Verma GR and Biswas G.** Reconstruction of a Major Abdominal and Chest Wall Defect using Latissimus Dorsi and Extended Deep Inferior Epigastric Artery Flap. *Ann Plast Surg* 1992;28:366-369.

#### Authors

**Dr Ashok Kumar Gupta, MS, M Ch, MNAMS,** Consultant Plastic Surgeon  
**Dr Bihari Lal Chitlangia, MS,** Consultant General Surgeon  
**Dr Sandip Jain**

Bombay Hospital and Medical Research Center, 12 Marine Lines, Bombay - 400 020.

Requests for reprints to Dr A K Gupta, Suite No.16, "Laud Mansion", 21 M Karve Road, Bombay 400 004