



AN INNOVATIVE TECHNIQUE FOR STATIC POST-OPERATIVE SPLINTAGE

Neeta Kulkarni Patel and Parag Sahasrabudhe

Dept of Plastic & Reconstructive Surgery, Lokmanya Tilak Municipal Medical College & Hospital, Bombay

SUMMARY : *Dental Impression Compound was found to be a useful material to fabricate immediate postoperative and maintenance splints after contracture release in 50 cases.*

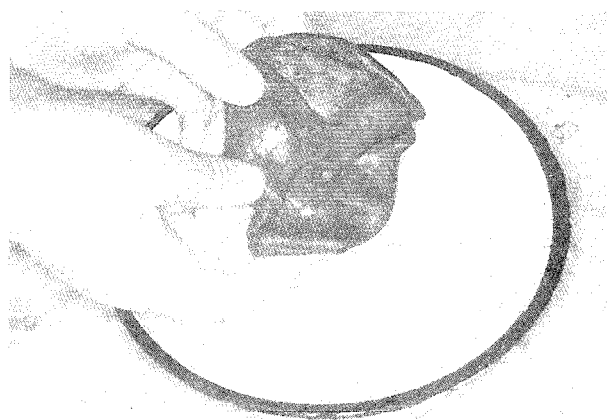
Early and appropriate post operative splintage forms an integral part of management of post burn contractures following their release to prevent recurrence of contractures and scar hypertrophy.

Commercially available custom made splints are relatively expensive, many times need adjustments and might be a cause for delay in initiating treatment. As an alternative Dental Impression Compound was tried by us for static splintage. The following is an early assessment of the initial 50 cases where these splints were used.

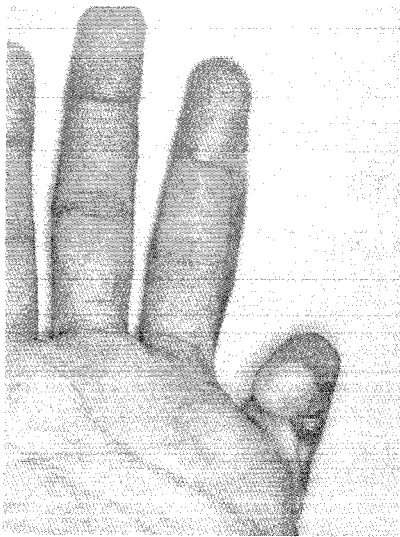
Dental Impression Compound being thermoplastic becomes pliable in hot water and can easily be moulded to the contour of the site following surgical release. Once cooled, it maintains the shape for prolonged periods till it is re-moulded.

The surgeon can give the splint in the operation theatre over the tie over dressings (as a POP) and once the tie-over is removed, the same splint can be remoulded into a static "splint" over the new contour. A few velcro straps and a layer of foam make these splints functionally equal to the commercially available ones.

Frequent readjustments that are necessary in growing children have now become an office procedure. Encouraged by the results obtained, we started using this splint for splinting the nasal bone following fracture reduction and as a pressure splint over various sites following excision of hypertrophic scars and as a stent for the neovagina following vaginoplasty. Accidental cracks or breaks may occur; however they can be welded to shape by the



(Fig - 1) Dental Impression Compound moulded after immersion in hot water



(Fig - 2) (L) Little finger contracture preop

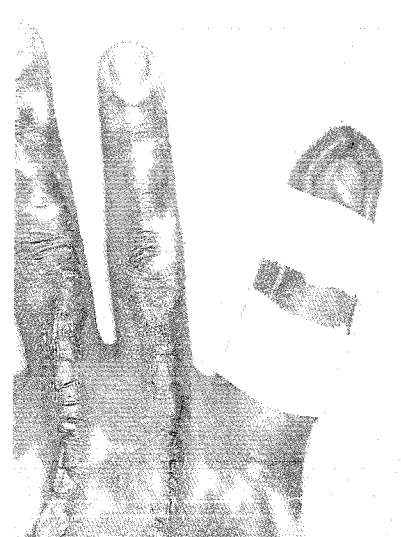
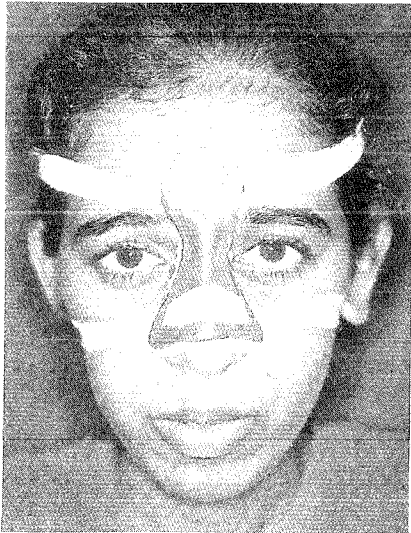
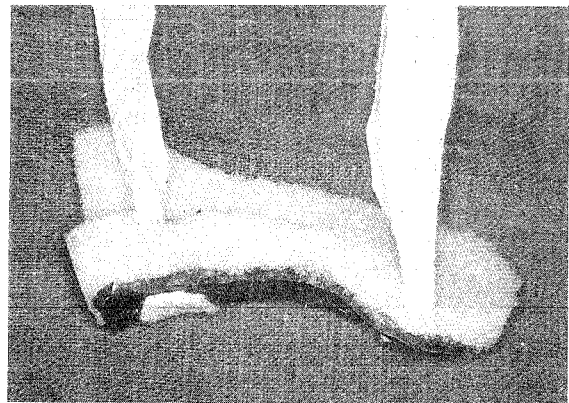
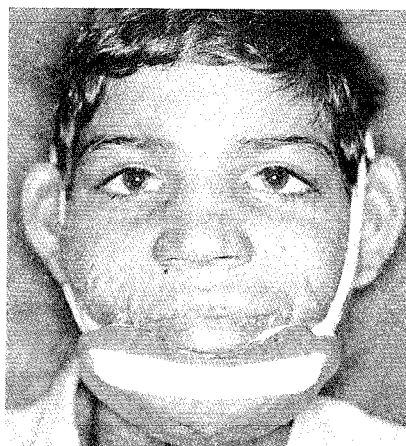
Fig - 3) (L) Little finger contracture with a temporary splint after surgical release




(Fig - 4) Nasal splint for hypertrophic scar over the nose



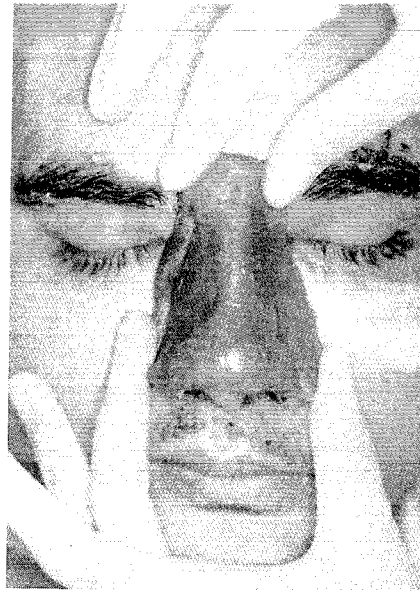(Fig - 5) Nasal splint



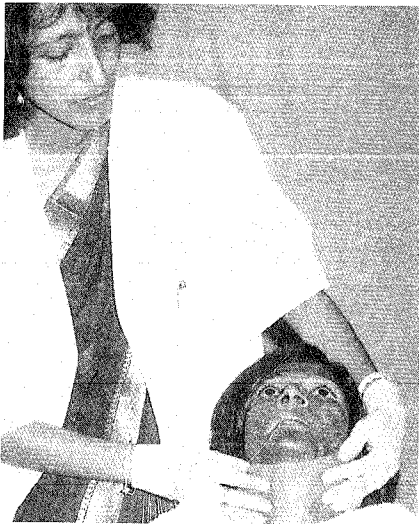(Fig - 6) Chin splint given after excision of postburns hypertrophic scar over the chin



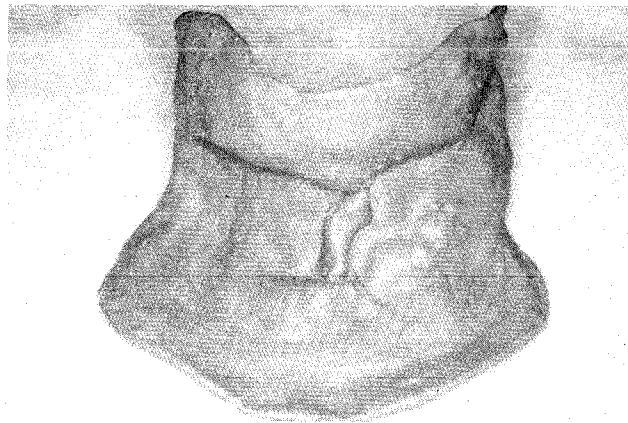
(Fig - 7) Splint given for the elbow following release of elbow contracture



(Fig - 8) Nasal splint moulded over the nose in a case of compound fracture of nasal bones



(Fig - 9) Neck splint - reused and modified after removal of tie-over dressings in the O.P.D.



(Fig - 10) Neck splint welded by the patient and reused after accidental break

clinician or by the patient with the help of the clinician.

Since most of our patients treated were poor, cost-effectiveness stood out as a major advantage of this innovation. A neck splint made from Dental Impression Compound costs only Rs.35/- as compared to a similar splint made from Orthoplast which costs nearly Rs.600/-, not to mention the additional cost of the POP splint given immediately after surgery.

Hence it is envisaged that this material will definitely have great potential as a material of construction for splints and its use, for static splintage is sure to stay.

Acknowledgement

The authors wish to thank Mr. Parshuram Pangerkar, Photographer, Department of Plastic Surgery, Lokmanya Tilak Municipal Medical College and Hospital, Sion, Bombay for the photographs.

Authors

Dr Neeta Kulkarni Patel, MS, M Ch, Senior Resident,
Dr Parag Sahasrabudhe, MS, Junior Resident,

Department of Plastic and Reconstructive Surgery, Lokmanya Tilak Municipal Medical College and Hospital, Sion, Bombay - 400 022.

Requests for reprints to Dr Neeta Kulkarni Patel, Darya Mahal - 'A'-63, 80 Nepean Sea Road, Bombay - 400 006