

Invited Article

THE SCOPE OF CRANIOFACIAL SURGERY

Ian T. Jackson and Ramesh Kumar Sharma,
Institute for Craniofacial and Reconstructive Surgery, Southfield, Michigan, U.S.A.

Craniofacial surgery is a logical extension of maxillofacial surgery. Paul Tessier in the mid-1960s, launched the era of craniofacial surgery. Initially, the speciality encompassed only the management of congenital craniofacial deformities but, with time, the principles of craniofacial surgery have been applied to the treatment of trauma, both in the acute stage and post-traumatic sequelae, and to tumours involving the base of the skull which in the past were virtually inaccessible. Presently, craniofacial philosophy has been integrated into aesthetic surgery of the face. This presentation is an introduction to the basic principles of craniofacial surgery and illustrates the incredible and explosive expansion that has taken place.

CRANIOFACIAL TEAM

Craniofacial surgery requires complex investigations and operative procedures which can be coordinated efficiently and safely only by a well-integrated and harmonious team consisting of a plastic surgeon, neurosurgeon, maxillofacial surgeon, an ophthalmic surgeon, an otolaryngologic surgeon, a neurologic surgeon, orthodontist, pedodontist, medical specialists: paediatrician, geneticist, internist and intensive care specialists, a speech pathologist, a social worker, a photographer, a dietitian, and nursing specialists. It can be seen from this array of specialists that all aspects of patient care are covered.

BASIC PRINCIPLES

Timing of a surgical intervention in a craniofacial case has always been a debatable issue. Early surgery is justified for raised intracranial pressure in craniosynostosis. Similarly, an early surgical procedure might be needed for protection of eyes. Improvement in airway in an Apert's syndrome is a poor indication because the degree of improvement is frequently disappointing. Although it is desirable to do early surgery in hypertelorism, the orbits cannot be totally osteotomized because of the tooth

buds which lie just under the infraorbital rim. It is better to wait until the teeth descend lower into the maxilla.

ANAESTHESIA

Current practice is to avoid tracheostomy if at all possible. With the help of fiberoptic endoscope, even difficult intubations can be done without too many problems. The surgeon and the anaesthesiologist should be aware of potential catastrophies during LeFort II and LeFort III osteotomies. The tube may be displaced or can be traumatized, the most significant being transection with the osteotome. If there is any doubt about the airway, the endotracheal tube can be kept in situ for as long as seven to ten days without any deleterious effects.

IMAGING

Plain x-rays are not of much help in a craniofacial case. The minimum requirement is axial and coronal CT scanning. For accurate assessment of complex, three-dimensional deformities, the 3D-computed tomographic imaging is of great help. It allows calculations of distance, area and volume. The facility allows correct orientation of the CT images. The technique allows mirror imaging to be accomplished which is of great help in treatment planning of asymmetries, especially old trauma and hemifacial syndromes. The surgeon can do "mock" surgery on the work station screen. The facility provides a unique opportunity for the patient as well as for trainee education. However, for most of the cases, coronal and axial CT scans are sufficient. Three-dimensional imaging is not indicated as a routine investigation.

Craniofacial surgical principles have been applied to a variety of situations.

ACUTE TRAUMA

With increasing experience and sophistication in craniofacial surgery, a fresh look has been taken at

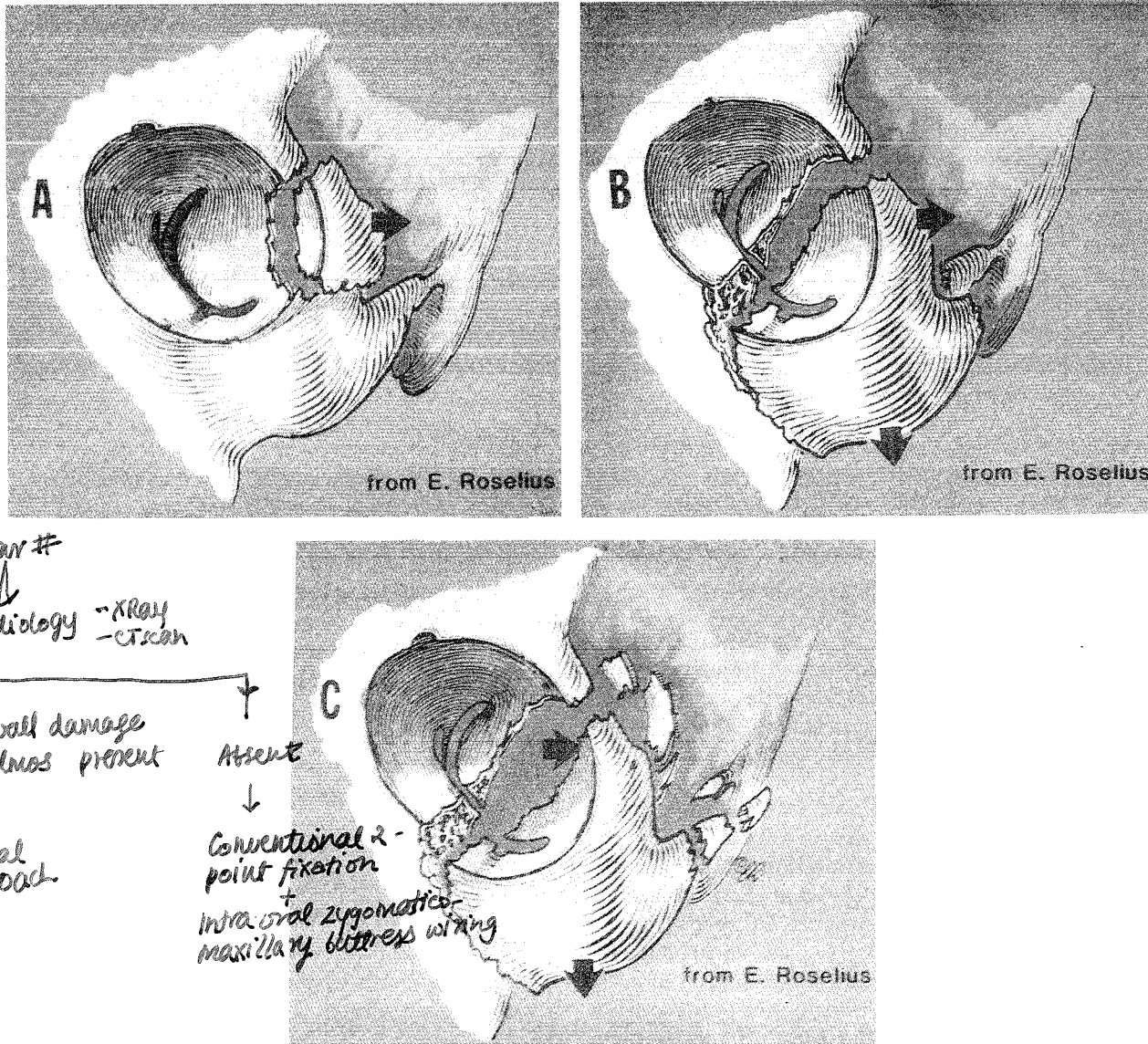
craniofacial trauma. Techniques have been examined and altered, and the results have been assessed more critically.

Malar Fracture

Malar fracture can be divided into four groups: Group I - undisplaced; Group II - segmental; Group III - undisplaced tripod (low velocity); and Group IV - severely displaced with or without comminution (high velocity) (Fig. 1). It is the Group IV type of fracture which has a tendency to relapse with globe displacement, enophthalmos and double vi-

sion. There is a posterior and inferior rotational displacement: the zygomatic arch is fractured at several places. Moreover, the lateral wall is fractured because of high velocity force of injury. This leads to herniation of fat and resulting enophthalmos. The conventional two-point fixation at the infraorbital rim and zygomaticofrontal suture in this type of fracture forms a hinge which is acted upon by fibrosis in the lateral wall area - setting the stage for relapse.

If there is no lateral wall damage on x-ray film and CT scan, and no enophthalmos, adequate fixation is provided by conventional two-point fixation



(Fig - 1) CLASSIFICATION OF ORBITOZYGOMATIC FRACTURES


(A) Localized lateral orbital wall fracture - segmental group 1, (B) Displaced Tripod type fracture group 4, (C) Displaced comminuted type fracture with comminution high velocity group 4

and intraoral exposure of the zygomaticomaxillary buttress with correction of displacement in this area, and application of wires or plates. If the CT scan shows a lateral orbital wall displacement or destruction with or without enophthalmos, a coronal approach is used. The lateral orbital wall and floor are reconstructed with cranial bone grafts. All zygomatic fractures are reduced and stabilized with wires or plates (Fig 2).

With this treatment regimen, relapse has not been a problem and the incidence and severity of enophthalmos have been considerably reduced.

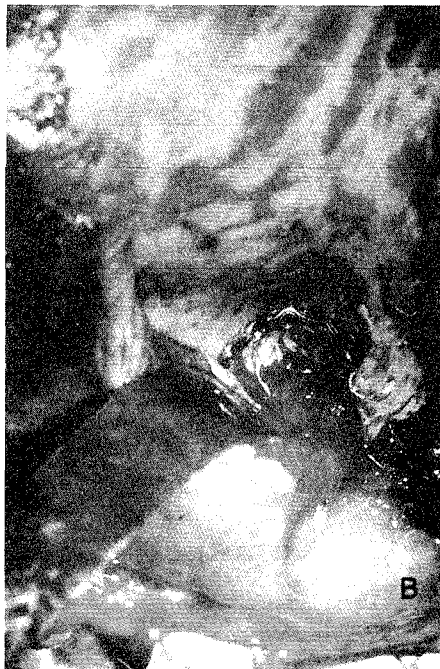Maxillary Fractures

In these fractures, the coronal incision is used almost routinely; it allows direct wiring or plating in the glabellar and zygomaticofrontal areas. Again, the lateral orbital walls are skull bone grafted if indi-



(FIG - 2) GROUP FOUR ORBITOZYGOMATIC FRACTURE

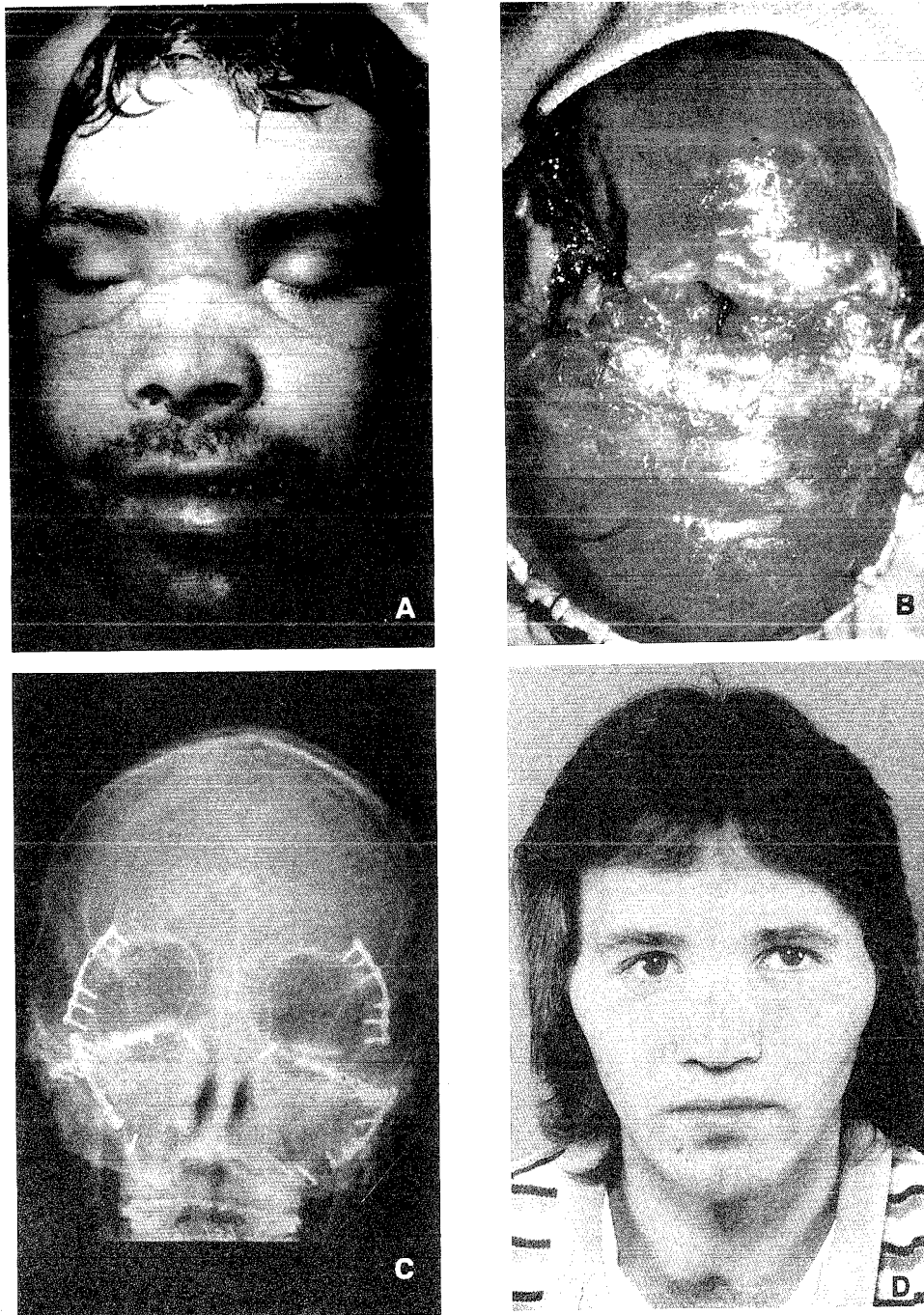
(A) The slight widening of the face in the zygomatic area indicates a displaced orbitozygomatic fracture associated with enophthalmos, (B) This was reduced, a cranial bone graft was placed in the lateral orbital wall, and a plate from the temporal area onto the lateral orbital wall holds the bone graft and the reduced fracture in good position, (C) Post-operative result.



cated, and the zygomatic arches are wired or plated. The LeFort I part of the fracture is explored through a buccal sulcus incision and reduced and wired or plated at the piriform aperture and zygomaticomaxillary buttress. If required, bone grafts are used. This avoids intermaxillary fixation. This particular approach is of great value in management of LeFort II and LeFort I situations where, using the conventional treatment with suspension wiring, facial height is frequently reduced (Fig.3).

Nasoorbitoethmoid Fractures

This is the term used to describe what was previously referred to as nasoethmoid fracture. Such fractures should always be approached through a coronal incision unless there is an extensive laceration over the fracture site. All the bone segments are wired or plated together accurately, and if needed, skull bone



(FIG - 3) LEFORT III FRACTURE

(A) Recent inadequately treated LeFort III fracture using a facial approach, (B) The coronal flap shows a considerable displacement between the lateral orbital wall and orbital roof on the right side, together with displacement of the nasal skeleton and the glabellar region. It was fixed with wires, plates and bone graft, (C) The x-ray showing the reduction and fixation. Bilateral orbital floor cranial bone grafts can be clearly seen, (D) Post-operative result. There is still some widening of the face at the zygomatic arch region.

grafts are employed. An important part of management of such fractures is relocation of the medial canthal ligaments. Two holes are drilled from the most solid portion of the nose down to the desired canthal position on the medial orbital wall; this is at the posterior lacrimal crest. A wire is double passed

through the canthal ligament and is guided into the two drill tracks with the help of a hypodermic needle or a Keith needle. The wire is now tightened on solid bone. This approach leads to a stable medial canthopexy and is much better than the conventional techniques (Fig. 4).

A fracture of the anterior wall of the frontal sinus requires removal of frontal sinus mucosa. The fracture is stabilized by multiple wires and any contour irregularities are filled with craniotome bone dust. In more extensive fractures the sinus is lined with a galeal frontalis flap and filled with bone dust.

More extensive fractures involving the supraorbital rim are explored by a coronal flap and are accurately wired in place. Orbital roof fractures are repositioned; if needed, skull bone grafts are used for reconstruction (Fig. 5).

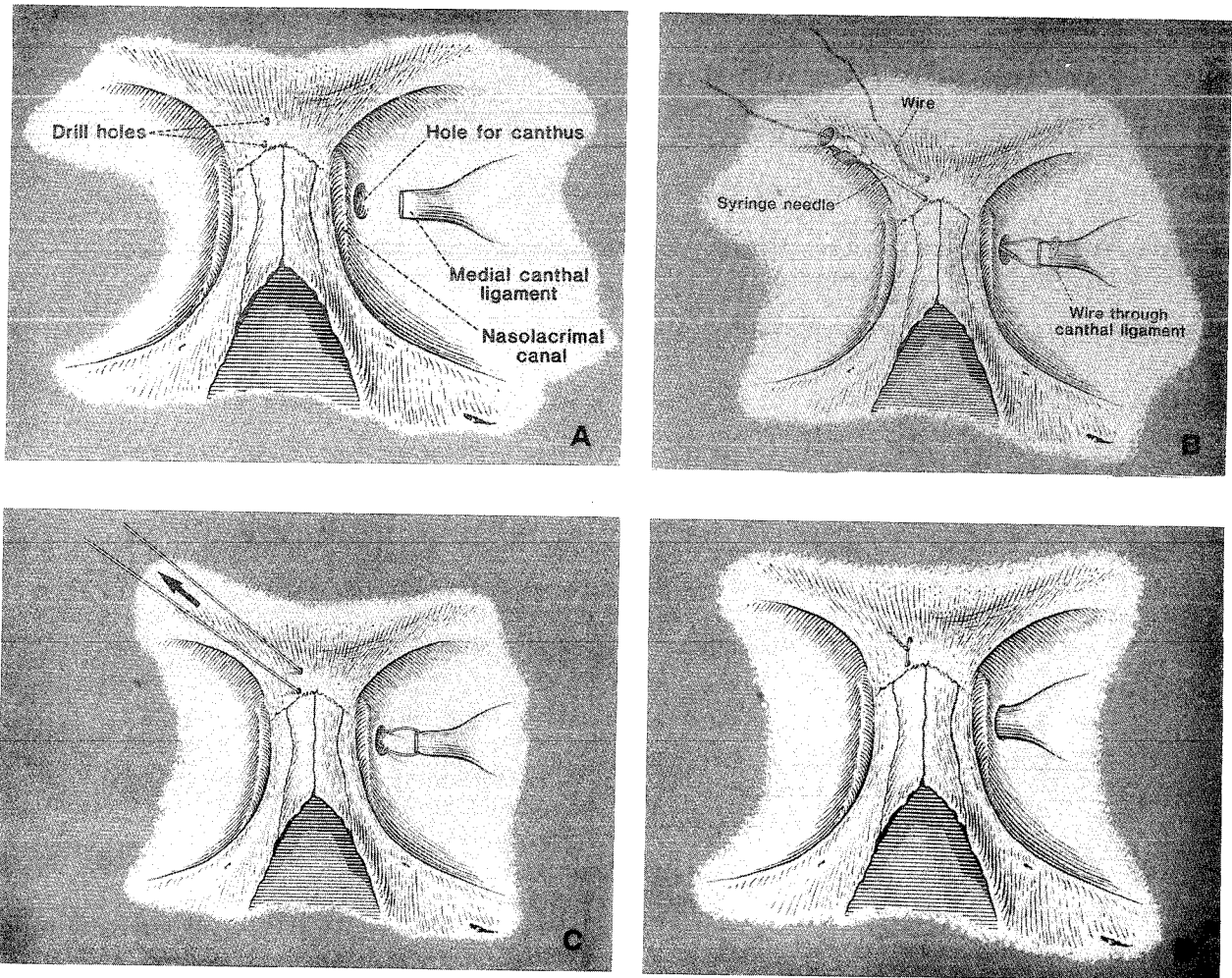
The main advances in the management of craniofacial trauma are two-plane CT scans, the coronal approach, the buccal sulcus approach, immediate bone grafting and accurate wiring or plating.

OLD CRANIOFACIAL TRAUMA

Secondary post-traumatic deformities occur due to poor assessment and treatment of the initial trauma, relapse or resorption of the primary correction, or lack of early treatment, because of the magnitude of other injuries.

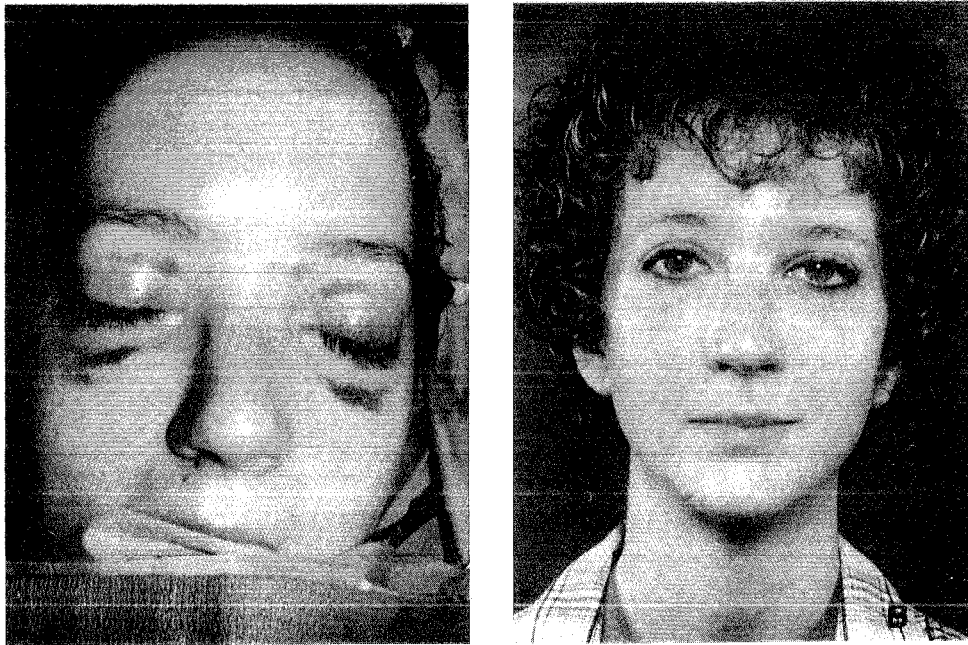Skull Defects

If a full thickness defect of the skull is present, the defect is reconstructed with cranial or rib bone grafts or prefashioned acrylic plates. Irregularities of contour are smoothed. If they are more significant, hip joint methylmethacrylate is used to overlay and contour the skull. Drill holes and trenches are cut in



(FIG - 4) MEDIAL CANTHOPEXY

(A) The anticipated position of the canthus is shown together with the drill holes for the canthal wire. Note that these are on solid portions of bone in the frontal area, (B) The wires have been introduced through the drill holes and double looped through the medial canthal ligament. A syringe needle or a Keith needle allow the wire to be passed easily through the drill tracks, (C) The medial canthal ligament is now pulled tightly into its final position, (D) The wire is tightened securely onto the thick frontal bone.



(FIG - 5) NASOORBITAL ETHMOID FRACTURE

(A) This patient shows the typical appearance of a patient having sustained a displaced naso-orbital ethmoid fracture, (B) The appearance after being treated with reduction fixation with microplates, medial canthopexy using the methods shown in figure 4 and a cranial bone graft to support the nasal bridge line.

the skull prior to cement application to ensure solid fixation.

Orbital Dystopia

There is usually a caudal displacement of the affected orbit. Small defects may be handled by contouring the upper orbit and performing an osteotomy of the floor and infraorbital rim with elevation of this segment. If dystopia is marked, correction is achieved by utilizing a "box osteotomy" for elevating the whole orbit into the correct position. Here again, a combined intra and extracranial approach is used.

Telecanthus

This is explored using a bicoronal flap; if necessary, a definitive medial orbital wall osteotomy, with removal of a central nasoglabellar segment, is used. The medial walls are shifted and a transnasal canthopexy is performed. The skin folds are corrected using the Mustarde "jumping man" technique.

Maxillary Retrusion

The method of correction of maxillary retrusion is based upon the clinical, cephalometric and dental assessment. A LeFort advancement osteotomy is carried out, the level is determined by the extent of the deformity.

Unreduced Malar Fracture

This is the most common post-traumatic deformity. Correction necessitates a wide exposure using a coro-

nal flap and lower blepharoplasty incisions. Corrective osteotomies are done and, if needed, bone grafts are paced in the lateral orbital wall and zygoma (Fig. 6).

TUMOURS

In the field of treatment of cranio-orbital and skull base tumours, craniofacial techniques have proved invaluable. Craniofacial osteotomies have been developed to facilitate exposure and resection of skull base tumours. A portion of the skeleton overlying the tumour is removed, the lesion is resected, and the removed bony structure is then replaced. These "osteotomies" have allowed the surgeons to deal with lesions that in the past were considered to be unresectable. Total en-bloc resection of deeply situated tumours is possible with very few complications. Co-operation with a neurosurgeon is very important. Adequate exposure using standard soft tissue approaches is essential - the coronal flap, the face split, the Weber-Fergusson incision, and the extended temporal preauricular incision. The last incision is used for exposing middle cranial fossa and others for lesions of the anterior cranial fossa. Frequently on these patients the floor of the anterior cranial fossa and medial orbital walls have been removed. When these have been reconstructed,

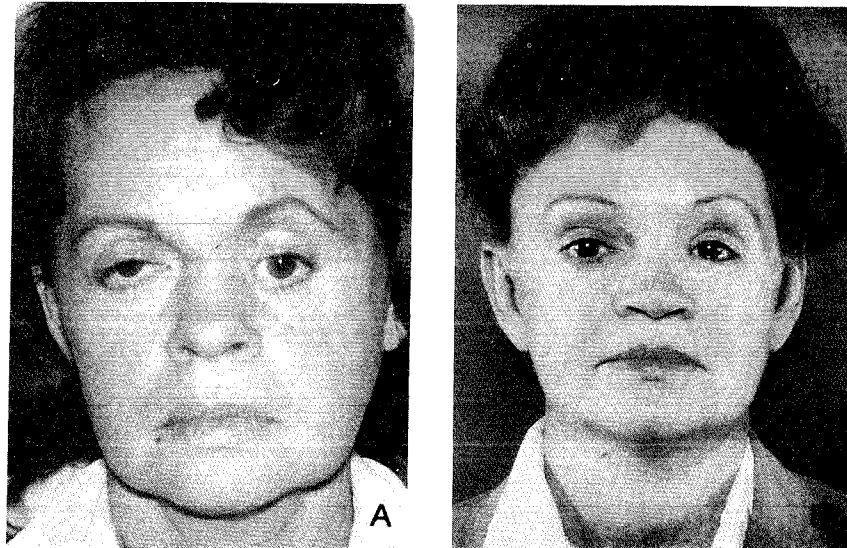

FIGURE 6: FACIAL DEFORMITY FOLLOWING POOR INITIAL TREATMENT OF FACIAL FRACTURES

(A) This patient shows post-traumatic nasal deformity, left enophthalmos and displacement of the orbitozygomatic segment, and an unreduced impacted LeFort I fracture. (B) Appearance after rhinoplasty with nasal bone graft, osteotomy of left orbitozygomatic area, repositioning of segment with bone grafting, correction of enophthalmos, repositioning of lower maxilla with LeFort I osteotomy, and a facelift to reposition displaced facial soft tissue.

these regions must be protected on the nasopharyngeal surface with a galeal frontalis musculofascial flap (Fig. 7). This is especially important when there has been a dural repair. In extensive soft tissue resections, it may be necessary to use a free vascularized tissue transfer.

ANTERIOR SKULL BASE TUMOURS

Orbital Tumours

These usually present as globe displacement. Nonmalignant tumours involving the medial, superior and lateral parts of the orbit should be approached by a coronal flap along with a periorbital dissection. These may be frontal or ethmoid, osteomata, muscle, nerve or fatty tumours. The tumours may be simply shelled out as in osteoma or may need to be dissected out. In plexiform neurofibroma exenteration may be the only possible form of treatment.

In malignant tumours or nonmalignant tumours deep in the orbit, it may be necessary to use a combined intra- and extracranial approach with the removal of frontal bone flaps, together with the supraorbital ridge and orbital roof. This allows adequate exposure. In malignant tumours of the orbital contents or sinuses, an exenteration or a block resection is performed.

Anterior Skull Base Tumours

Meningioma is relatively localized and can be excised totally. A similar situation exists with an osteoma or localized patch of fibrous dysplasia. After excision, the reconstruction is performed with split skull or split rib grafts. Should there be any doubt about excision, the reconstruction is deferred until a later date.

Malignant tumours are sarcomas, olfactory neuroblastomas, adenocarcinomas and squamous cell carcinomas, among others. These are widely resected with the skull base. Reconstruction is with galeofrontalis flaps or free tissue transfer.

Central Skull Base Tumours

These may arise as intracranial tumours and appear in the neck after escaping through one of the basal foramina. The most common type of tumours are the neurofibroma and meningioma. Alternatively, an extracranial tumour may involve the base of the skull, e.g. adenoid cystic carcinoma of parotid or middle or external ear squamous cell carcinoma.

It has been found helpful to classify the skull base into three areas in devising surgical approaches to this region. The anterior third contains anterior portion of the temporal lobe which relates directly to the posterior wall of the orbit. It has foramen rotundum,

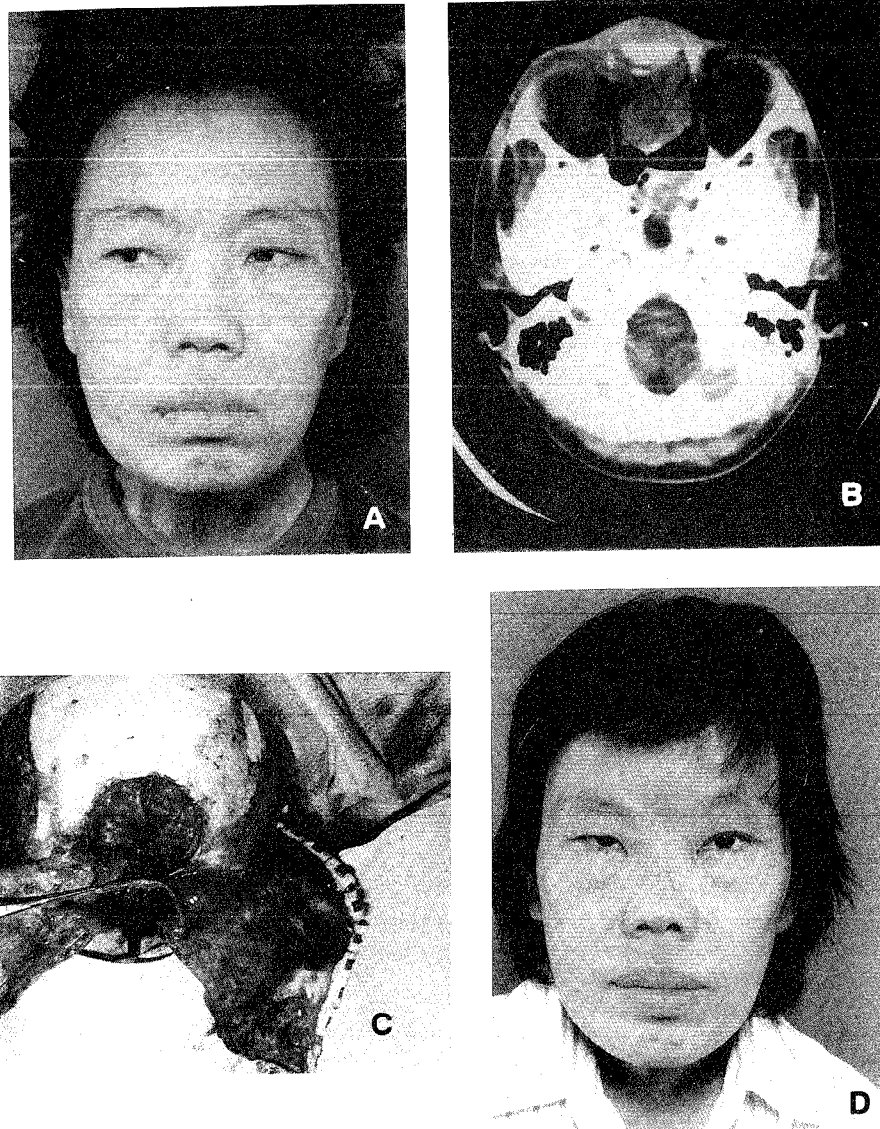
foramen ovale and the foramen spinosum in its floor. The optic foramen lies in the medial and anterior part of the fossa. The central third contains the middle ear within the petrous temporal bone, the foramen lacerum with the carotid artery and the cavernous sinus and the internal auditory meatus. The posterior third extends into the posterior cranial fossa. This contains the cerebellum and the jugular foramen.

The extracranial lesions present as swellings, ulcerations, ear discharge, deafness or facial palsy. The intracranial tumours exit through one of the foramina. From the anterior and middle third, these

enter the pterygoid space to appear as a temporal swelling or as masses behind the ascending ramus if they invade the temporal fossa. If these enter the orbit through the inferior orbital fissure, proptosis may occur. These may cause dysphagia or dyspnea if the spread is circumferential around the nasopharynx.

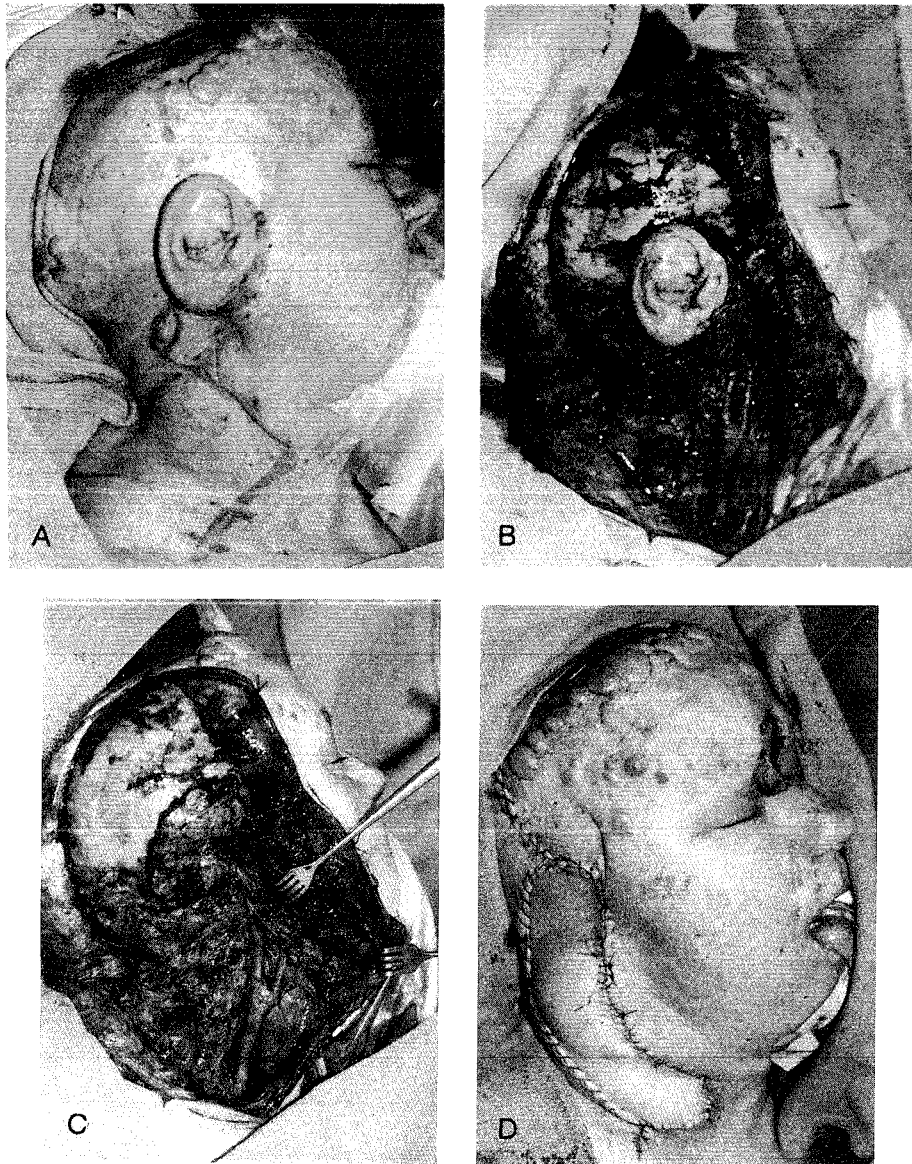
Posterior skull base tumours

Tumours in the posterior fossa can escape through the jugular foramen to present as deep lobe of parotid tumours. The involvement of glossopharyngeal, vagus, accessory and hypoglossal nerve by pressure may be present.



(FIG - 7) ADENOCARCINOMA OF THE ETHMOID SINUSES RECURRENCE POST RADIATION THERAPY

(A) Pre-operative appearance, (B) Axial CT scan showing the position and extent of tumour, (C) Approach using coronal flap and midfacial split with removal of trephine of frontal bone and glabellar and nasal skeleton. Following resection of tumour, anterior cranial base closed with galeal frontalis myofascial flap (held in forceps), (D) Post-operative appearance at 18 months.



(FIGURE - 8) MALIGNANT CYLINDROMA REQUIRING TOTAL PETROSECTOMY

(A) Appearance of external portion of tumour with the soft tissue resection outlined and the design for a neck dissection, (B) Neck dissection completed; great vessels are well displayed, (C) Total petrosectomy has been performed by an inter- and extracranial approach, (D) The resulting defect was closed with a pectoralis major myocutaneous flap.

TREATMENT OF CENTRAL SKULL BASE TUMOURS

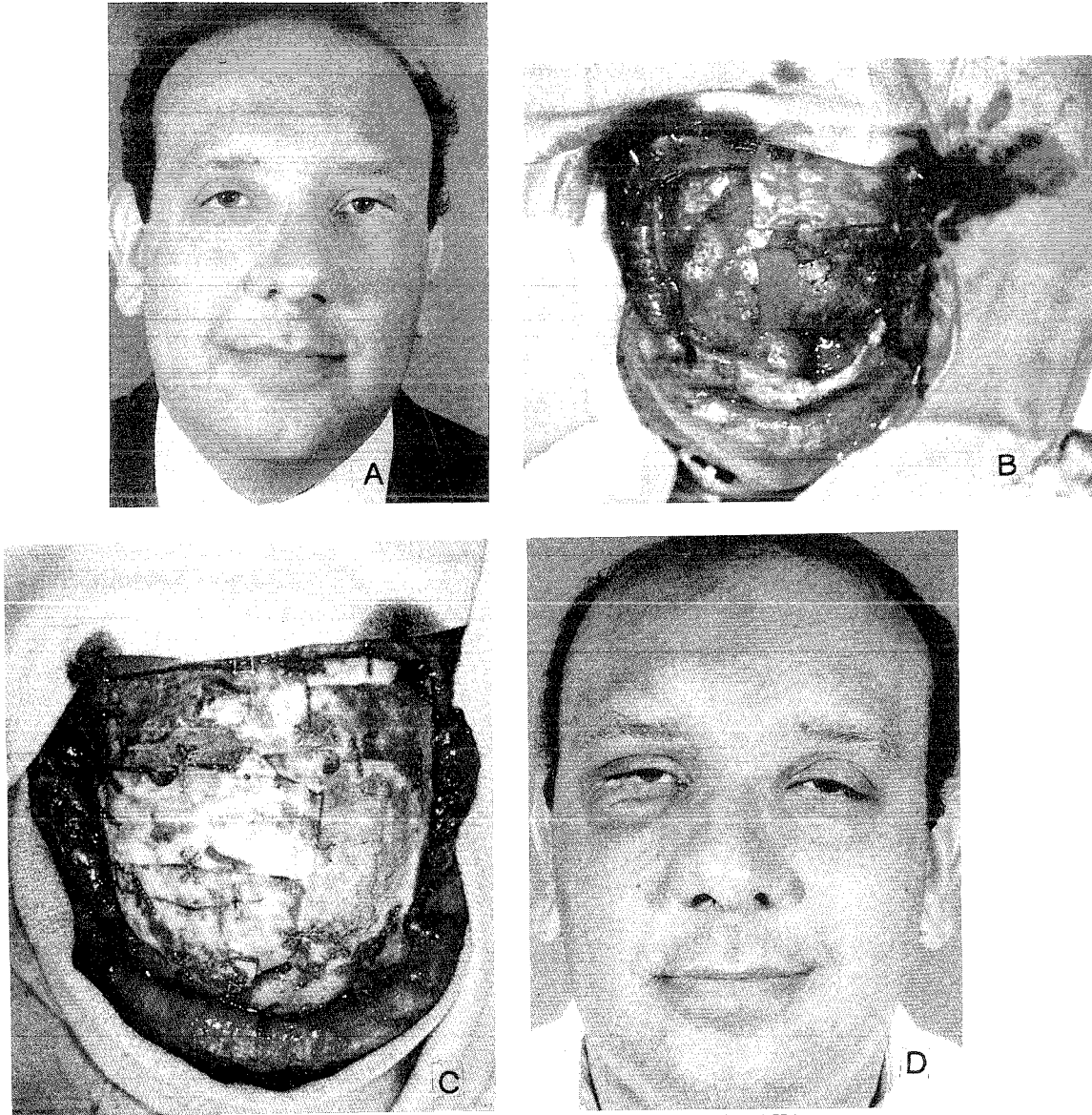Anterior Third

A half coronal incision is made with an extension down in the facelift position into the neck as required. A frontotemporal bone flap is raised and the involved area is explored. A total parotidectomy is performed, preserving the facial nerve. Zygomatic arch and ascending ramus are osteotomized to allow access to the pterygoid fossa, temporal fossa, orbit, bone of skull, and nasopharynx. The tumours can be

easily removed.

Central Third

The tumours are generally in the parotid or external or middle ear. The skin is usually involved and needs to be excised. A temporal scalp flap is outlined with the proposed skin excision and this may be extended down into the neck if neck dissection is needed. A temporal bone flap is lifted and the temporal lobe is retracted. This allows the floor of the middle cranial fossa to be resected as needed. The soft tissue defect needs to be covered with the same flap or with a flap from elsewhere (Fig. 8).



(FIGURE - 9) CRANIOORBITAL FIBROUS DYSPLASIA

(A) A patient with extensive fibrous dysplasia of the frontotemporal area and left orbit. The left temporal lobe is compressed by intracranial extension of the fibrous dysplasia. (B) Skull and orbital defect following resection of fibrous dysplasia, (C) Reconstruction with split skull grafts, (D) Early post-operative result with complete resolution of right arm paresis.

Posterior Third

The incidence of tumour is extremely low and this excision is primarily executed by the neurosurgeon.

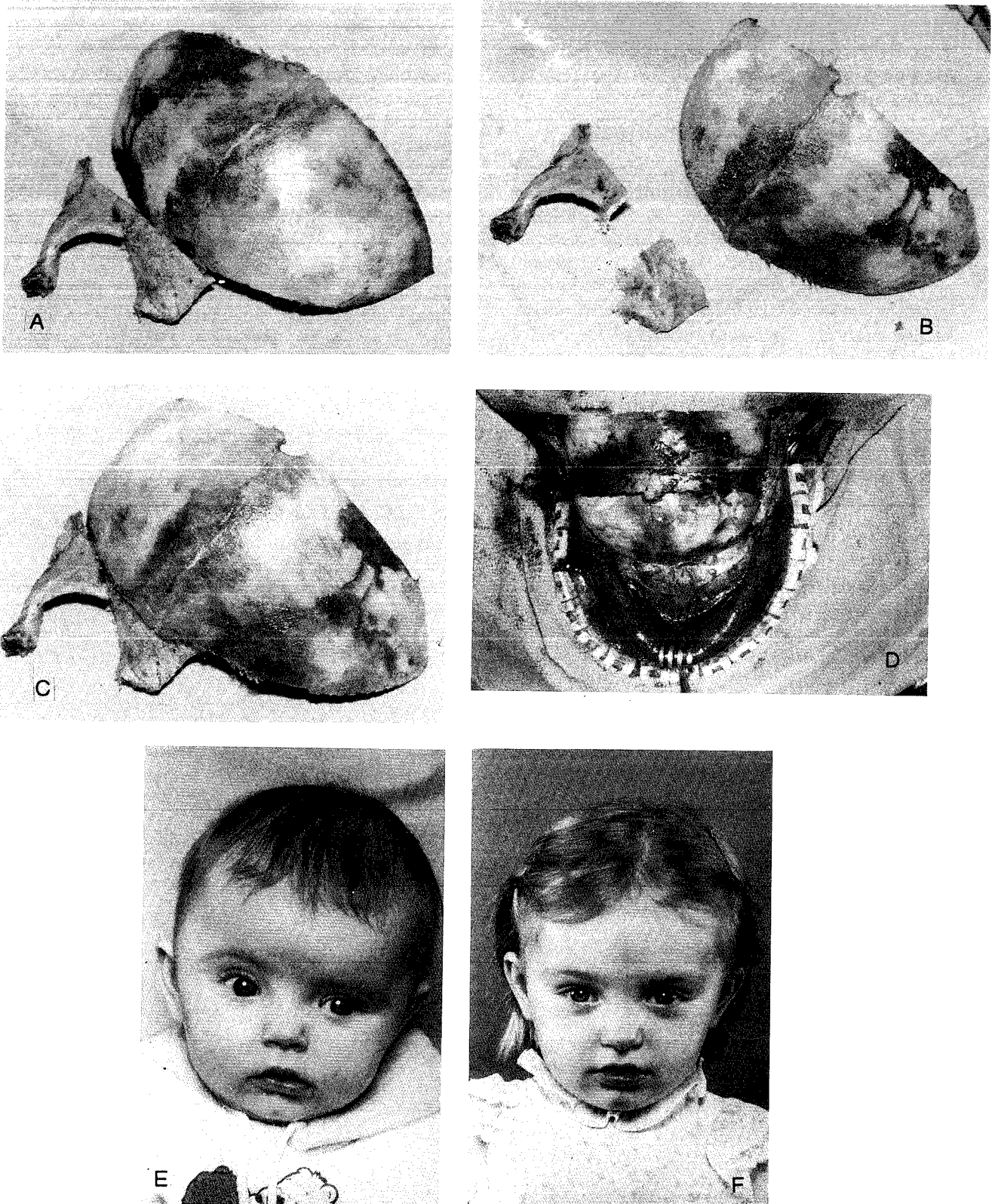
Fibrous Dysplasia

If this condition occurs in the mandible or maxilla, simple shaving is quite satisfactory. However, with skull and orbital involvement, it becomes a complex problem. In fronto-orbital disease, the patient may present with displacement of globe or orbit. The treatment recommended is total resection with reconstruction. Conservative treatment may lead to visual compromise (Fig.9).

CRANIOFACIAL DEFORMITIES

Craniosynostosis

Premature fusion of cranial sutures may occur in any location and in any number. This may lead to a rise in the intracranial pressure resulting in visual deterioration and mental retardation. The frequency (in decreasing order) of premature closure of sutures is sagittal, coronal (unilateral), coronal (bilateral), metopic, lambdoid, and Kleeblattschadel. The main indication for surgery is aesthetic. Investigations include x-rays of the face, CT scan or in selected cases, 3-D CT scan and ophthalmological work-up.



(FIGURE - 10) CORRECTION OF UNILATERAL CORONAL CRANIOSYNOSTOSIS

(A) The constricted orbit and flattened right frontal bone can be seen, (B) The frontal bone has been rotated 180° and the supraorbital rim has been osteotomized to enlarge the orbit, (C) Cranial bone graft has been placed in the supraorbital rim, (D) Appearance after the orbit and frontal bone have been replaced, (E) Pre-operative appearance, (F) Post-operative appearance

The optimal age for correction is three to six months. In selected patients, placement of a shunt might be needed before embarking upon the cranial correction.

Sagittal Craniosynostosis (Scaphocephaly)

The approach is by a coronal incision. In minor deformities, a strip of cranium about 2 cm wide taken out on either side of the sagittal suture will probably be effective. In most cases it is best to make anterior and posterior craniotomies just behind the coronal and in front of the lambdoid sutures. The parietal bones can be pried bilaterally and loosened, that is, hinged inferiorly. The bones are left loose so that the head can be expanded transversely. In more severe cases, the anterior cranial fossa is narrow and the orbits are rotated posteriorly. This requires a fronto-orbital osteotomy and anterior rotation of the lateral part of the frontal bone and orbital segments. This will flatten the forehead, thus effectively widening it. This shall also correct the orbital rotation.

Unilateral Coronal Craniosynostosis (Plagiocephaly)

This is a much more complex deformity than it was previously thought to be. It is now appreciated that more of the basal sutures surrounding the sphenoid and malar bone are involved, leading to constriction of the sphenoid wings. This leads to retrusion of the frontosupraorbital region and a smaller and misshaped orbit. The approach is through a coronal incision. The whole of the frontal bone is removed. The supraorbital rim, anterior part of the orbital roof, lateral rim, lateral orbital wall, and a portion of

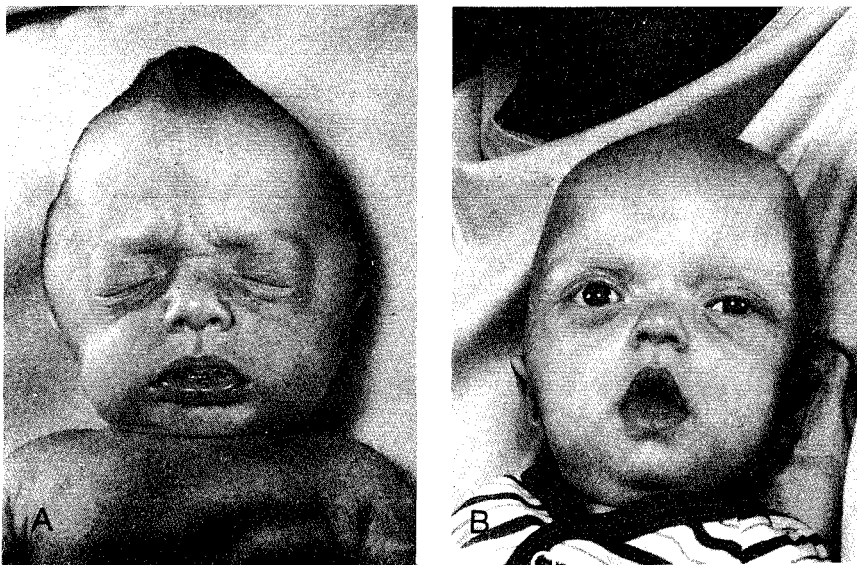
the zygoma are removed as a single unit, leaving a frontal band. If there is contraction of the orbit, the supraorbital rim and roof are divided in midline and bone grafts are inserted and fixed with microplates. The lateral rim and lateral walls are also corrected likewise by using bone grafts and microplates. The corrected orbital segment is aligned correctly to the normal side and fixed with a microplate. A similar fixatin is applied at the zygomatic area.

The deformed frontal bone must be rearranged. In mild cases, it may be turned through 180° and fixed to the frontal area only, leaving the posterior border without any fixation. In more severe cases, the frontal bone may need to be cut into smaller segments which are then fixed with the help of microplates to give an acceptable frontal bone (Fig 10).

The sphenoid wing constriction should also be released. A temporal craniotomy is done and the bone is reshaped by using a barrel staving technique.

Bilateral Coronal Craniosynostosis (Oxycephaly)

This is generally seen in patients with Crouzon's or Apert's syndrome. The supraorbital rims and lateral orbital walls are flat. These are removed and can be reshaped into the desired curvature. This segment is advanced as a whole by about 2 to 3 cm, and fixed with microplates. The frontal bone may be turned by 180° to give a better shape or completely reshaped using osteotomies and osteosynthesis. The middle cranial fossa is enlarged laterally in these patients leading to a bulge in temporal area, thus the lateral wall of the fossa is removed, reshaped and fixed securely with plates or screws (Fig 11).



(FIGURE - 11) CORRECTION OF BICORONAL CRANIOSYNOSTOSIS CROUZON'S SYNDROME

(A) Typical appearance of bicoronal craniosynostosis with Crouzon's syndrome. Note particularly the bulging in the temporal region, (B) Appearance after frontosupraorbital advancement and reduction of bitemporal width.

The midface may need corrections at a later date and frequently bimaxillary osteotomies are needed.

Metopic Craniosynostosis (Trigonocephaly)

There is a midline ridge and the frontal bones and orbits are rotated laterally. There is associated hypotelorism. The frontal bone, supraorbital rim, part of the orbital roof and lateral walls are removed. A midline osteotomy is made and angulation of the frontal bone and orbits are corrected as in scaphocephaly. In mild cases, hypotelorism does not need to be corrected.

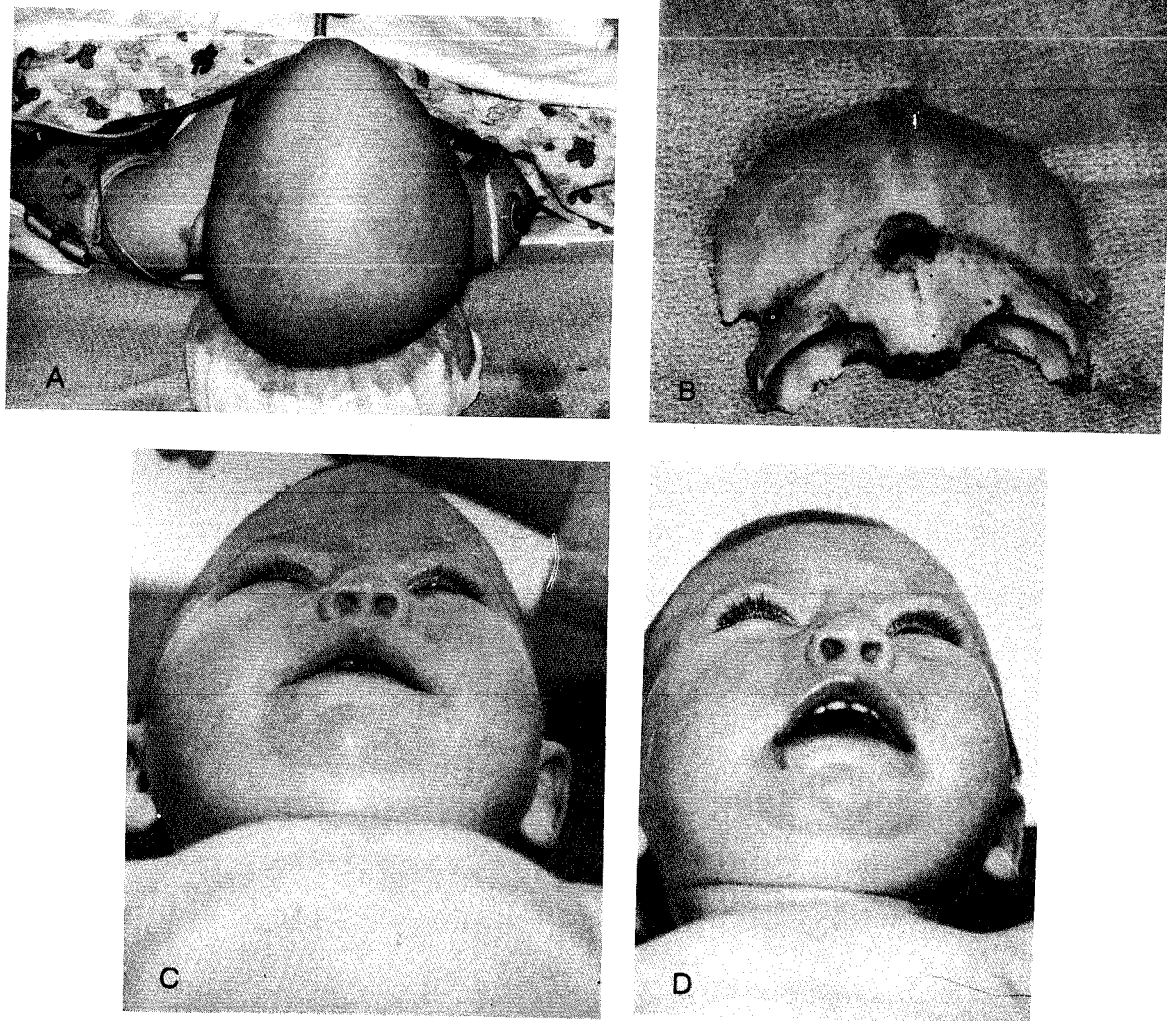
In more severe deformities, the midline osteotomy is used to widen the anterior cranial fossa and to correct

the hypotelorism. The central gap may or may not be reconstructed with bone grafts (Fig 12).

Hypertelorism

Hypertelorism is lateralization of the orbits and should not be confused with telecanthus where the orbits are in correct position but the medial walls are too far apart. The causes are midline cleft, an adjacent cleft, or frontonasal encephalocele. The ethmoid sinuses are enlarged leading to true separation of the orbits.

The basic aim of treatment is resection of the excessive central area and movement of the orbits together. The nose may be either long or short,


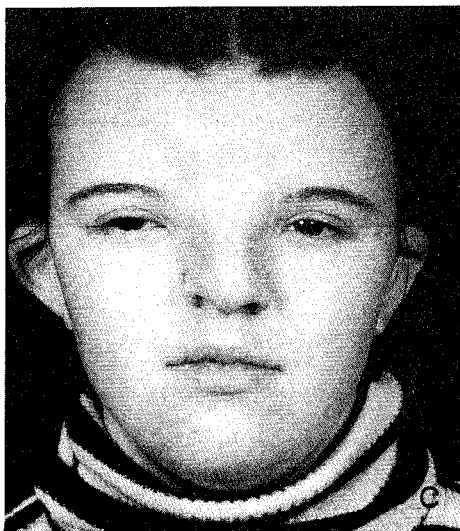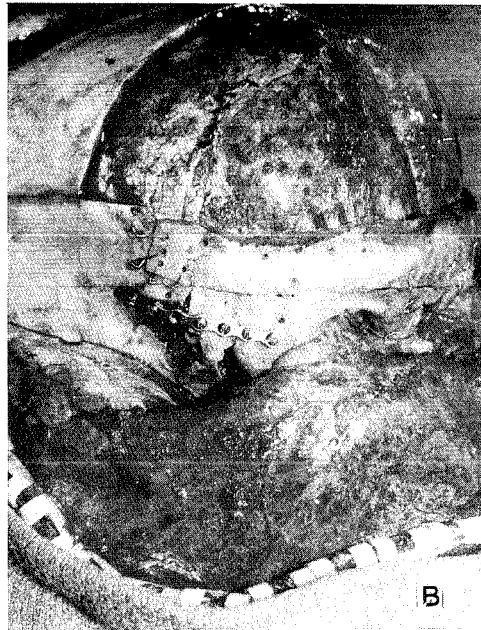
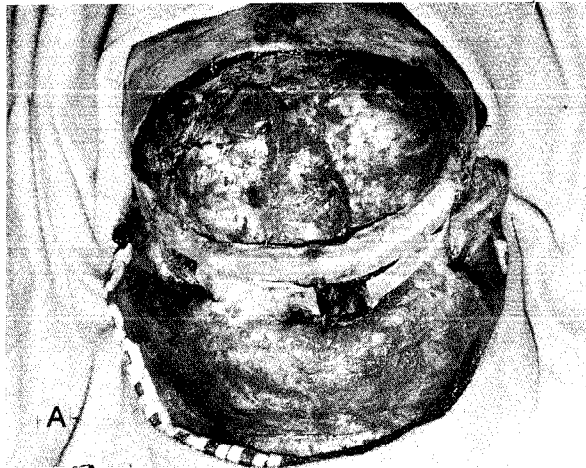

(FIGURE - 12) CORRECTION OF METOPIC CRANIOSYNOSTOSIS

(A) Typical appearance of patient with moderately severe metopic craniosynostosis, (B) Typical appearance of frontosupraorbital area prior to expansion, (C) Pre-operative appearance, (D) Post-operative appearance.

depending upon the basic cause of the hypertelorism. Correction may be achieved either by an extracranial or an intracranial approach. The extracranial approach is indicated only in minor cases. In most cases, the intracranial approach is used. The exposure is by the coronal flap. After frontal craniotomy, the frontal lobes are retracted to visualize the cribriform plate. The orbital contents are freed totally by subperiosteal dissection. The nose is also dissected subperiosteally up to the piriform aperture. The precalculated central segment of bone is resected,

preserving the nasal mucosa. The contents of the ethmoid sinus and the bone of the anterior cranial fossa floor are resected lateral to cribriform plates. An osteotomy is made horizontally across the frontal area, maintaining a frontal bar between the orbit and the frontal defect. The osteotomy is taken laterally into the temporal area down to the lateral orbital wall and across the maxilla under the infraorbital nerve to piriform aperture. The orbits are moved medially and plated together; the lateral orbital wall is bone grafted and stabilized with plates (Fig 13).



(FIGURE - 13) CORRECTION OF HYPERTELORISM

(A) The supraorbital band has been reconstructed since there was a defect in it. Total orbital osteotomy has been performed bilaterally, and widened glabellar nasal area has been resected, (B) The orbits have been brought together and the lateral defect has been bone grafted, secure fixation using miniplates, (C) Pre-operative result, (D) Post-operative result.

Frontonasal Encephalocele

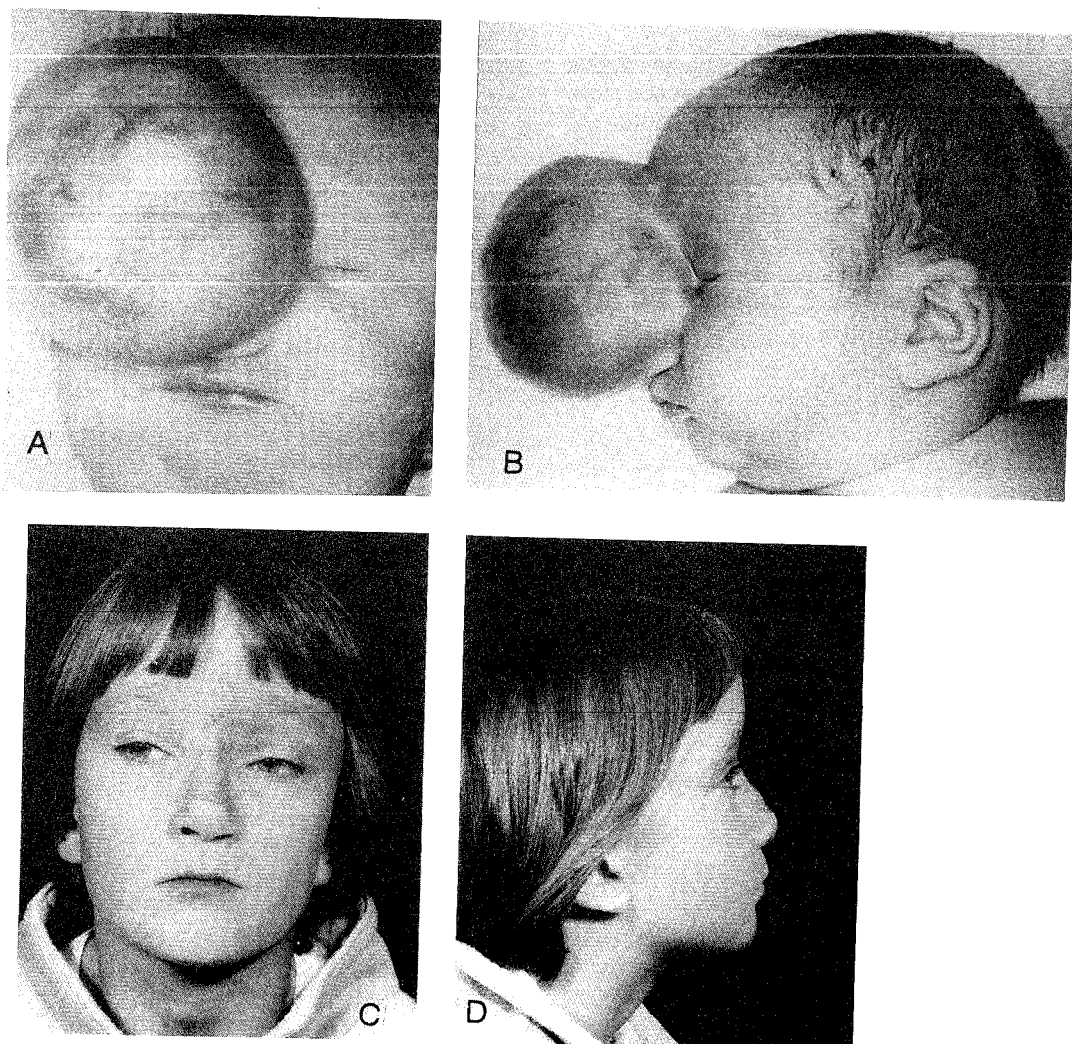
An encephalocele is a protrusion of part of the cranial contents through a defect in the skull. The contents may contain meninges, meninges and brain, or meninges, brain and the ventricular system.

The site of the cranial defect is between the frontal bone (membranous) and ethmoidal bone (cartilaginous). It corresponds to the foramen caecum, which represents the anterior neuropore of the embryo and is located anterior to the crista galli on the floor of the anterior cranial fossa. This is at the root of the nose between the orbits. Nasal encephalocele is classified into three subgroups according to the site of facial protrusion.

In the nasofrontal type, the defect is in the frontoethmoidal junction and the encephalocele projects directly forward between the frontal and nasal bones.

In the nasoethmoid type, the protrusion is lower and pursues a long, narrow course from the frontoethmoidal junction downwards emerging between the nasal bones and the cartilage.

In the nasoorbital type, the protrusion pursues a course from the frontoethmoidal junction down behind the nasal bones, and then laterally through a defect between the lacrimal bone and the frontal process of the maxilla, presenting between the nose and lower eyelids in the nasolabial fold.



(FIGURE - 14) CORRECTION OF FRONTONASAL ENCEPHALOCELE

(A & B) Pre-operative appearance of large frontonasal encephalocele, (C & D) Postoperative appearance after two operations using the method described in the text.

The treatment aims at resection of the encephalocele, improving the appearance, and preventing infection from occurring. The herniated cerebral tissue is generally fibrotic and can be excised without severely affecting the function.

The approach is through a coronal flap. The operation should be done intracranially. Extensive subperiosteal exposure is performed to identify the exit defects of the encephalocele. A bifrontal craniotomy is done; the frontal lobes are retracted to display the roof of the orbits and the neck of the encephalocele is exposed extradurally. The dural sac is opened, the herniation is inspected, and the fibrotic tissue is excised. Dural repair is then accomplished, usually with the help of fascia (temporal). Orbital osteotomies are designed to decrease the orbit size and are supplemented with placing a bone graft in the floor, medial and lateral wall and roof of the orbit.

After this, the external dissection of the soft tissue mass is done, carefully separating it from the skin. Special precaution should be taken to avoid injury to the lacrimal drainage apparatus (Fig 14).

COMPLICATIONS

The complications of craniofacial surgery in a busy centre approach that of many routine surgical operations. Nevertheless, we must explain to the patient and relatives that serious complications like death, blindness, infection, loss of bone graft, etc., may occur. In our series of over 1400 patients, the death rate is less than 0.2%. Blindness has never occurred and serious infection rate is about 0.4%. There are some subtle complications which are rather frequent. These are postoperative ptosis; weakness of the extraocular muscle; downward drift of the lateral canthi; recurrence of hypotelorism, especially in children; and relapse of maxillary deformity after advancement. Infection is the most feared complication apart from death and blindness. The infection may lead to death or meningitis with its sequelae. The reason for the high rate of infection in the past was because of a connection between the nasopharyngeal and extradural/intradural space. In adult patients with frontal advancement, there is creation of an extradural dead space. This is very susceptible

to infection. If there is a connection between the nasopharynx and cranium, it can be effectively shut off by use of a frontogaleal musculofascial flap. If there is a dead space, it should be filled with a free tissue transfer, either an omentum or muscle flap.

Suggested Reading

- 1 David DJ and Simpson DA. Craniodystosis. In JC Mustarde and IT Jackson (Eds), Plastic Surgery in Infancy and Childhood. Edinburgh: Churchill Livingstone 1988; 188-207.
- 2 Fukuta K and Jackson I T. Three dimensional imaging in craniofacial surgery: a review of the role of mirror image productions. Eur J Plast Surg 1990; 13: 209.
- 3 Jackson I T. Management of acute craniofacial injuries. In: Ernesto P Caronni (Ed), Craniofacial Surgery. Boston/Toronto: Little Brown and Company 1985; 441-448.
- 4 Jackson I T. The wide world of craniofacial surgery. J Oral Maxillofac Surg 1983; 41:103-110.
- 5 Jackson I T. Classification and treatment of orbitozygomatic and orbitoethmoid fractures: the place of bone grafting and plate fixation. Clin Plast Surg 1989; 16:77-91.
- 6 Jackson IT, Tanner NSB, Hide TAH. Frontonasal encephalocele - "long nose hypertelorism". Ann Plast Surg 1983; 11:490-500.
- 7 Jackson I T, Marsh WR, Bite U and Hide TAH. Craniofacial osteotomies to facilitate skull base tumour resection. Br J Plast Surg 1986; 39:153-160.
- 8 Ferguson DJM, Barker J and Jackson IT. Anaesthesia for craniofacial osteotomies. Ann Plast Surg 1983; 10:333-338.
- 9 Jackson I T, Adham M N and Marsh W R. Use of galeal frontalis Myofacial flap in craniofacial surgery. Plast Reconstr Surg 1986;77:905.
- 10 Jackson I T, Munro I R, Sayler K E and Whitaker L A (Eds). Atlas of craniomaxillofacial surgery. St Louis: Mosby Year Book 1982.
- 11 Sekhar L N and Janecka I P (Eds). Surgery of Cranial Base Tumours. New York : Raven Press, 1993.

Authors

Dr. Ian T. Jackson MD, DSc, (Hon), FRCS, FACS, FRACS, Institute for Craniofacial and Reconstructive Surgery Southfield, Michigan, USA

Dr. Ramesh Kumar Sharma, MS, MCh, Dept. of Plastic and Reconstructive Surgery, Chandigarh, India

Requests for reprints to Dr. Ian T. Jackson MD, DSc, (Hon), FRCS, FACS, FRACS, Institute for Craniofacial and Reconstructive Surgery, 16001 West Nine Mile Road, 3rd Floor Fisher Center Southfield, Michigan 48075 USA