



Utilizing a Guiding Catheter to Improve Endovascular Therapy Outcomes for Acute Vertebrobasilar Artery Occlusion in Patients with Tortuous Vessels

Takahiro Himeno¹ Tatsuya Ohtonari² Akio Tanaka³ Tomoyuki Inoue¹ Ryuusuke Koori⁴
Kouta Sato¹ Takeshi Miyazaki⁴ Shinzo Ota⁴

¹Department of Neurology, Brain Attack Center Ota Memorial Hospital, Fukuyama, Hiroshima, Japan

²Department of Spinal Surgery, Brain Attack Center Ota Memorial Hospital, Fukuyama, Hiroshima, Japan

³Department of Radiology, Brain Attack Center Ota Memorial Hospital, Fukuyama, Hiroshima, Japan

⁴Department of Neurosurgery, Brain Attack Center Ota Memorial Hospital, Fukuyama, Hiroshima, Japan

Address for correspondence Takahiro Himeno, MD, Department of Neurology, Brain Attack Center Ota Memorial Hospital, 3-6-28 Okinogami, Fukuyama, Hiroshima, 720-0825 Japan (e-mail: himenotakahiro@oita-u.ac.jp).

Asian J Neurosurg 2024;19:145–152.

Abstract

Objective Stable and swift placement of a guiding catheter in endovascular therapies for acute vertebrobasilar artery occlusion is often difficult because of the tortuous bends of the vertebral or subclavian artery especially in older people. The use of a delivery assist guiding catheter (DAGC) shortens the time with stable support to deliver a therapeutic treatment catheter to the target lesions. Herein, we reported the clinical and radiographic outcomes in endovascular therapies utilizing the DAGC for acute vertebrobasilar artery occlusions in actual clinical settings.

Materials and Methods Between January 2018 and December 2021, 33 consecutive patients (males, 20[60.6%]; median age, 78 years) using a DAGC for acute vertebrobasilar artery occlusion were analyzed retrospectively. Reperfusion was graded using postinterventional angiograms based on the “thrombolysis in cerebral infarction” (TICI) classification. Furthermore, the time from puncture to recanalization and the rate of effective recanalization achievement were investigated.

Results Effective recanalization with TICI 2b or 3 was achieved in 28 (84.8%) patients, and the median time from puncture to recanalization was only 44 minutes, despite the high rate of older patients in our cohort. In contrast, asymptomatic intracranial hemorrhage as a complication was observed in only 3 (9.1%) patients.

Conclusion The DAGC contributes to the shortening of recanalization time and improves the outcomes of endovascular therapies for acute vertebrobasilar artery occlusion.

Keywords

- ▶ acute vertebrobasilar artery occlusion
- ▶ endovascular therapy
- ▶ delivery assist guiding catheter
- ▶ tortuous vessels
- ▶ aspiration catheter

article published online
May 27, 2024

DOI <https://doi.org/10.1055/s-0043-1776048>.
ISSN 2248-9614.

© 2024. Asian Congress of Neurological Surgeons. All rights reserved.

This is an open access article published by Thieme under the terms of the Creative Commons Attribution-NonDerivative-NonCommercial-License, permitting copying and reproduction so long as the original work is given appropriate credit. Contents may not be used for commercial purposes, or adapted, remixed, transformed or built upon. (<https://creativecommons.org/licenses/by-nc-nd/4.0/>)

Thieme Medical and Scientific Publishers Pvt. Ltd., A-12, 2nd Floor, Sector 2, Noida-201301 UP, India

Introduction

While endovascular therapy for acute ischemic stroke due to large vessel occlusion in the anterior circulation is well-established as an effective alternative to intravenous tissue plasminogen activator administration,¹⁻⁴ the results of endovascular therapy for acute vertebrobasilar artery occlusion are not yet conclusive.⁵⁻⁸ A reason for the unstable results of endovascular therapy for acute vertebrobasilar artery occlusion is the uncertainty associated with placing the guiding catheter. Owing to the tortuous vertebral and subclavian arteries, the placement of the guiding catheter is often time-consuming and rarely impossible for the tortuous vessels, especially in older people. The system often slips down during treatment when the guiding catheter is unstable under such a condition.

A delivery assist guiding catheter (DAGC) (SEL-E guiding catheter; Medikit, Tokyo, Japan) has a strong supportive force to guide a treatment device stably and shortens the time of approach to the lesions for the conditions described above.⁹ In this study, we aimed to determine whether using a DAGC in endovascular therapy for acute vertebrobasilar artery occlusion could improve the outcomes of such therapies in a high-volume stroke center.

Materials and Methods

Patients

We retrospectively searched our endovascular therapy database to identify the clinical and radiographic outcomes of all patients with acute vertebrobasilar occlusion who underwent endovascular therapy with DAGC between January 2018 and December 2021. The inclusion criterion of this study was as follows: basilar artery or intracranial vertebral artery (V4 segment) occlusion resulting in no flow to the basilar artery. In total, 380 patients underwent endovascular therapy for acute ischemic stroke during this period (► Fig. 1). Patients with anterior circulation occlusion ($n = 329$) were excluded from the analysis. Of patients with posterior circulation stroke ($n = 51$), those with recurrences ($n = 3$) and posterior cerebral artery occlusion ($n = 8$) were excluded. Furthermore, seven patients with acute vertebrobasilar occlusion were also excluded because of the easiness of approach for the straight vessels with a normal guiding catheter. This decision was made by interventional operators who had more than 5 years of experience in cerebrovascular interventional therapy and had completed more than 100 thrombectomy procedures. We excluded cases of retreatment because it was usually much

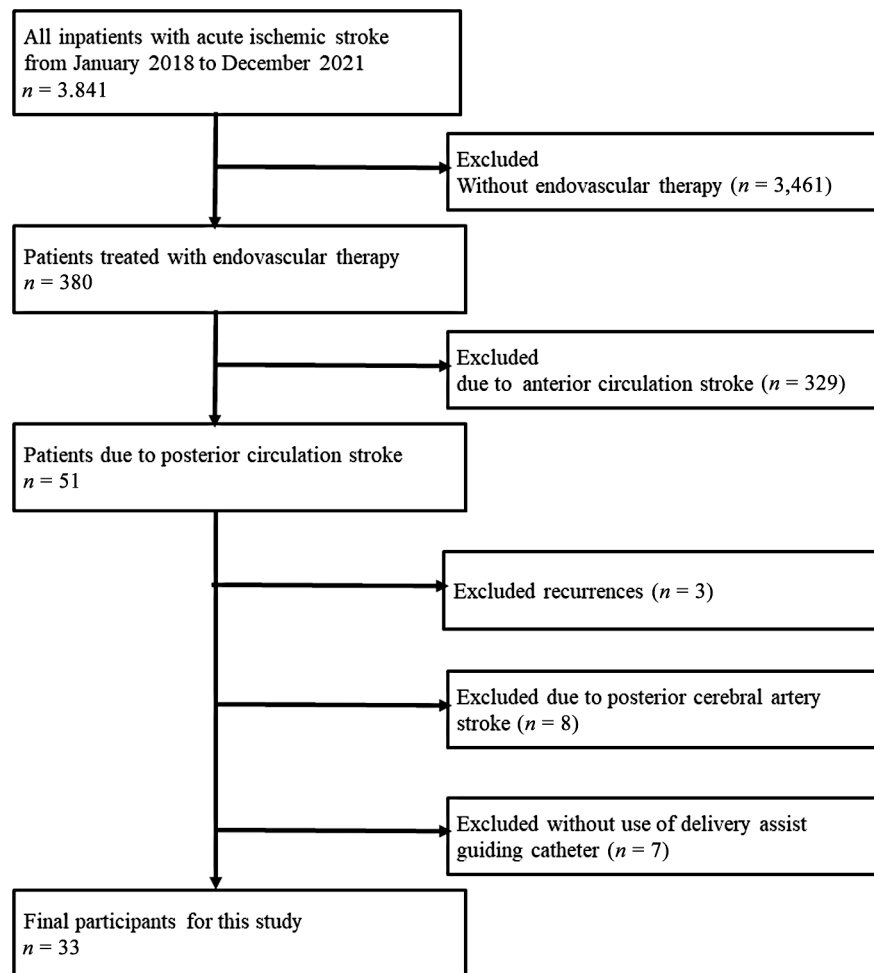


Fig. 1 Study profile.

easier to perform procedure. All other types of infarcts, including dissection and paradoxical embolism, were included. Ultimately, 33 patients were eligible for our study. We investigated the following data: age, sex, cerebrovascular risk factor (prior stroke, hypertension, diabetes mellitus, dyslipidemia, atrial fibrillation, and smoking), time of symptom onset, National Institutes of Health Stroke Scale score, posterior circulation Acute Stroke Prognosis Early CT score on admission, pre-stroke modified Rankin Scale (mRS) score, stroke subtype, and intravenous alteplase administration. Furthermore, as specialized assessment factors in endovascular treatment, we investigated the following data: femoral artery puncture time (start of treatment), utilized devices, "thrombolysis in cerebral infarction" (TICI) classification based on postinterventional angiograms, duration from puncture to recanalization, and technical complications. Postinterventional clinical functional neurological outcomes were evaluated using the mRS score at 90 days.

Device and Intervention Technique

The DAGC (8 Fr; JB2 shape; stiff type; outer diameter, 2.7 mm [8.0 Fr]; inner diameter, 2.24 mm [0.088 inch]; inner layer, polypropylene; outer layer, nylon; stainless steel braiding; platinum marker; full length, 83 cm; and effective length, 75 cm) was used in all patients. The DAGC was introduced to the distal side of the target vessel under the guidance of a 0.035-inch wire and a 4- to 6-Fr regular catheter. Thereafter, the 0.035-inch wire and 4- to 6-Fr regular catheter were removed, and the DAGC was pulled back to the appropriate proximal portion (►Fig. 2A). It usually takes only a few minutes with simple techniques described above. In cases of acute vertebrobasilar artery occlusion, the DAGC was placed at the brachiocephalic or left subclavian artery origin; subsequently, an aspiration catheter, such as Catalyst 6 (Stryker, Kalamazoo, Michigan, United States), was guided to the lesion using a microcatheter and a microguidewire (►Fig. 2B).

After placing the DAGC, an aspiration catheter was introduced into the vertebral artery using a microcatheter and microguidewire. However, a 0.035-inch guidewire was sometimes used to guide the aspiration catheter to the vertebral artery when the microcatheter and microguidewire were insufficient for support. Once the aspiration catheter reached the lesion, thrombectomy was performed using a direct aspiration first-pass technique (ADAPT).¹⁰⁻¹² When the thrombus was not removed using ADAPT, thrombectomy was performed in combination with a stent retriever (Solombra technique).^{13,14} When the aspiration catheter could not reach the lesion, it was treated with a stent retriever after the approach with a microcatheter and a microguidewire through the aspiration catheter. If an atherothrombotic occlusion during treatment was confirmed or a severe stenosis after recanalization was detected, percutaneous transluminal angioplasty (PTA) was performed or urokinase was further administered.

Results

Patients' Characteristics

►Table 1 presents the characteristics of all 33 patients. Of these patients, 20 (60.6%) were male, and the median age was 78 years. Atherothrombotic cerebral infarction, cardiogenic embolism, and other causes such as vertebral artery dissection, paradoxical embolism, and other embolic sources were observed in 13 (39.4%), 12 (36.4%), and 8 (24.2%) patients, respectively.

Endovascular Therapy

►Table 2 shows the outcomes of the 33 DAGC procedures. Intravenous alteplase was used in 5 (15.2%) patients. The duration of the intervention (median time from puncture to final recanalization) was 44 minutes. Effective recanalization with TICI 2b or 3 was observed in 28 (84.8%) patients. None of the patients had unreachable target lesions. Thirteen (39.4%)

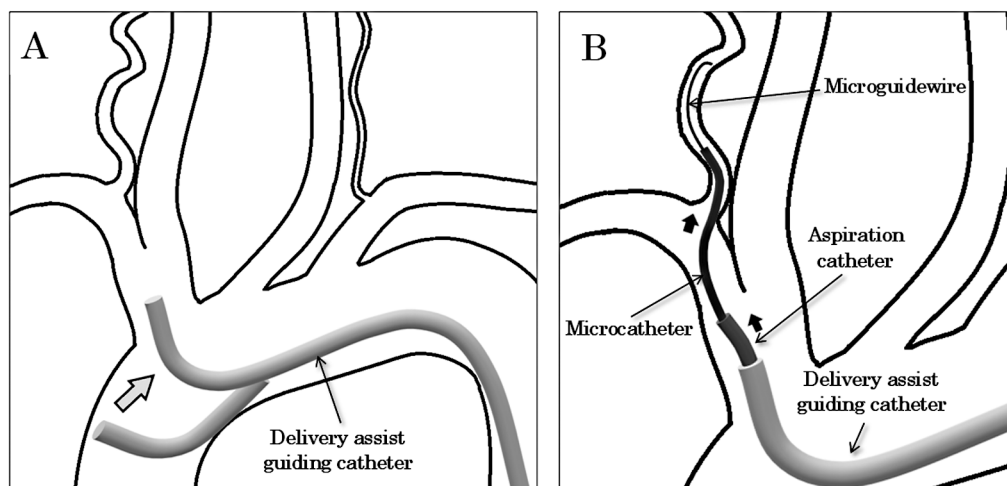


Fig. 2 (A) The delivery assist guiding catheter (DAGC) tip is introduced at the distal side of the target vessel, and the DAGC tip is pulled back to the appropriate proximal portion. (B) Through the DAGC as a stable guiding catheter, an aspiration catheter is inserted into the target vessel with a microcatheter and a microguidewire.

Table 1 Patients' characteristics

Variables	ATBI	CE	Others	Total
Cases	13 (39.4%)	12 (36.4%)	8 (24.2%)	33
Age—year	80 (73–88)	83 (75–86)	66 (56–76)	78 (73–86)
Male sex	8 (61.5%)	7 (58.3%)	5 (62.5%)	20 (60.6%)
Medical history				
Stroke	1 (7.7%)	4 (33.3%)	2 (25%)	7 (21.2%)
Hypertension	12 (92.3%)	11 (91.7%)	6 (75%)	29 (87.9%)
Diabetes mellitus	5 (38.5%)	5 (41.7%)	1 (12.5%)	11 (33%)
Dyslipidemia	10 (76.9%)	5 (41.7%)	3 (37.5%)	18 (54.5%)
Atrial fibrillation	4 (30.8%)	9 (75.0%)	0 (0%)	15 (45.5%)
Smoking	3 (23.1%)	3 (25.0%)	2 (25.0%)	8 (24.2%)
Pre mRS ≤ 3	13 (100%)	10 (83.3%)	8 (100%)	31 (93.9%)
pc-ASPECTS score	5 (4–6)	7 (7–8)	6 (2–7)	7 (4–7)
Initial NIHSS score	14 (11–30)	34 (24–37)	35 (20–37)	29 (13–35)

Abbreviations: ATBI, atherothrombotic infarction; CE, cardioembolism; IQR, interquartile range; mRS, modified Rankin Scale; NIHSS, National Institutes of Health Stroke Scale; pc-ASPECTS, Posterior Circulation Alberta Stroke Program Early Computed Tomography score. Data are *n* (%) or median (IQR). Others = dissection, paradoxical embolism, other embolic source.

Table 2 Endovascular therapy

Cases	33
Intravenous alteplase use	5 (15.2)
Time intervals—min	
From onset to door (<i>n</i> = 30)	223 (101–452)
From onset to puncture (<i>n</i> = 30)	285 (170–514)
From door to puncture (<i>n</i> = 30)	65 (61–79)
From puncture to recanalization (<i>n</i> = 37)	44 (20–68)
mTICI ≥ 2b	28 (84.8%)
Devices	
Aspiration only	13 (39.4%)
Combination (Stent retriever + aspiration)	12 (36.4%)
Aspiration + others (UK/PTA)	6 (18.2%)
Others (UK alone/PTA alone)	2 (6.1%)
Intracranial hemorrhage	
Symptomatic	0 (0.0%)
Asymptomatic	3 (9.1%)

Abbreviations: IQR, interquartile range; mTICI, modified thrombolysis in cerebral infarction scale; PTA, percutaneous transluminal angioplasty; UK, urokinase. Data are *n* (%) or median (IQR). Combination = Stent retriever + aspiration.

patients were treated with aspiration alone, 12 (36.4%) were treated with combination therapy, and 6 (15%) required urokinase or PTA after aspiration. Urokinase or PTA alone without aspiration was performed in two (6.1%) patients. Asymptomatic intracranial hemorrhage was observed in three (9.1%) patients. A favorable outcome (mRS score ≤ 3)

at 90 days was achieved in 13 (41.9%) patients (► **Table 3**). The mortality (mRS score 6) rate at 90 days was 25.8%.

Comparisons of Outcomes with and without DAGC

► **Table 4** shows all seven patient's characteristics and endovascular therapy without the usage of DAGC for the normal straight vessels. The median age of the patients (73 years) was younger than that of patients with the usage of DAGC (78 years). Atherothrombotic cerebral infarction, cardiogenic embolism, and other causes, such as vertebral artery dissection, paradoxical embolism, and other embolic sources, were observed in three (42.9%), three (42.9%), and one (14.3%) patients, respectively. Effective recanalization with TICI 2b or 3 was observed in seven (100%) patients. The median time from puncture to recanalization in the patients without DAGC was 54 minutes. Despite the simplicity of the procedure, this time was longer than that in patients with the usage of DAGC (44 min).

Representative Cases

To support the comprehension of the procedures utilizing DAGC, we show the basilar artery occlusion case (► **Fig. 3**) and V4 segment occlusion case resulting in no flow to the basilar artery (► **Fig. 4**).

Discussion

Outcomes

Our study of endovascular therapies for acute vertebrobasilar artery occlusion using a DAGC demonstrated a high effective recanalization rate and a significant reduction in the time from puncture to recanalization. The time from puncture to recanalization was shorter in patients with the usage of DAGC than in those who did not need a DAGC device, even

Table 3 Clinical outcome and comparison with other studies

Study	Present study	Basics ¹	BEST ²	ATTENTION ³	BAOCHE ⁴
Cases	33	154	66	226	110
Age—year	78 (73–86)	67 ± 13	62 (50–74)	66 ± 11	64 ± 10
Male sex	20 (60.6%)	100 (64.9%)	48 (72.7%)	149 (66%)	80 (73%)
Initial NIHSS score	29 (13–35)	21	32 (18–38)	24 (15–35)	20 (15–29)
Prestroke mRS ≤ 3	31 (93.9%)	154 (100%)	66 (100%)	226 (100%)	110 (100%)
Intravenous thrombolysis	5 (15.2%)	121 (79%)	18 (27%)	69 (31%)	15 (14%)
Time from puncture to recanalization—min	44 (20–68)	None	None	72 (48–108)	85 (59–129)
TICI ≥ 2b	28 (84.8%)	63 (71.5%) (n = 88)	45 (71.4%) (n = 63)	208 (93%)	89 (88%)
Intracranial hemorrhage					
Symptomatic	0 (0.0%)	7 (4.5%)	5 (7.5%)	12 (5%)	6 (6%)
Asymptomatic	3 (9.1%)			31 (14%)	8 (8%)
mRS ≤ 3 at 90 days	13/31 (41.9%) (pre-mRS ≤ 3)	68 (44.2%)	28 (42.4%)	104 (46%)	51 (46%)
Mortality at 90 days	8/31 (25.8%) (pre-mRS ≤ 3)	59 (38.3%)	22 (33.3%)	83 (37%)	34 (31%)

Abbreviations: IQR, interquartile range; mRS, modified Rankin Scale; NIHSS, National Institutes of Health Stroke Scale; SD, standard deviation; TICI, thrombolysis in cerebral infarction scale. Data are n (%), median (IQR), mean ± SD.

Table 4 Patients' characteristics and endovascular therapy without DAGC

Cases	7
Age—year	73 (59–81)
Male sex	7 (100%)
Medical history	
Stroke	2 (28.6%)
Hypertension	7 (100%)
Diabetes mellitus	3 (42.9%)
Dyslipidemia	6 (85.7%)
Atrial fibrillation	3 (42.9%)
Smoking	2 (28.6%)
pc-ASPECTS score	5 (5–7)
Initial NIHSS score	20 (13–32)
Subtype of stroke	
Large-artery atherosclerosis	3 (42.9%)
Cardioembolism	3 (42.9%)
Others	1 (14.3%)
Prestroke mRS ≤ 3	7 (100%)
Intravenous alteplase use	2 (28.6%)
Time intervals—min	
From onset to door (n = 5)	75 (52–163)
From onset to puncture (n = 5)	164 (153–243)
From door to puncture (n = 5)	95 (64–114)
From puncture to recanalization	54 (36–75)
mTICI ≥ 2b	7 (100%)
Devices	
Stent retriever only	1 (14.3%)
Aspiration only	4 (57.1%)
Aspiration + other (PTA)	1 (14.3%)
Other (UK + PTA)	1 (14.3%)
Intracranial hemorrhage	
Symptomatic	0 (0)
Asymptomatic	0 (0)

Abbreviations: ATBI, atherothrombotic infarction; CE, cardioembolism; DAGC, delivery assist guiding catheter; IQR, interquartile range; mRS, modified Rankin Scale; mTICI, modified thrombolysis in cerebral infarction scale; NIHSS, National Institutes of Health Stroke Scale; pc-ASPECTS, Posterior Circulation Alberta Stroke Program Early Computed Tomography score; PTA, percutaneous transluminal angioplasty; UK, urokinase. Data are n (%) or median (IQR). Combination = stent retriever + aspiration.

though patients without the usage of DAGC were younger and had straight vessels. DAGC may be convenient regardless of the type of vessels because DAGC is easily placed in a short time, and had a strong supportive force to guide a treatment device stably and quickly.

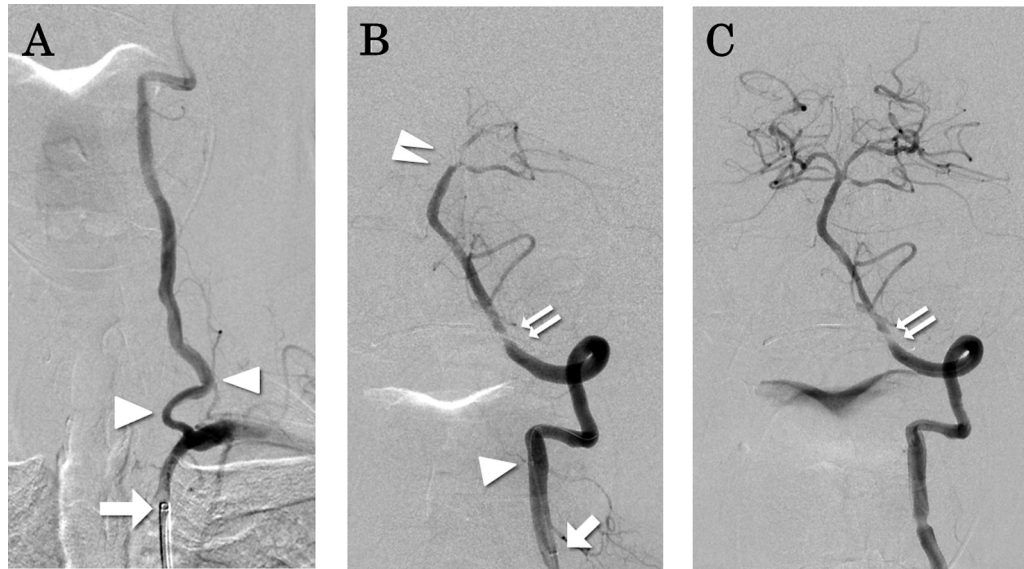


Fig. 3 A 74-year-old man presented with sudden loss of consciousness and quadriplegia. Diffusion-weighted imaging reveals high-intensity areas in the bilateral cerebellar hemispheres. Basilar artery occlusion is confirmed on magnetic resonance angiography. A delivery assist guiding catheter (DAGC) is placed at the origin of the left subclavian artery. (A) Frontal angiographic view of the left subclavian artery shows tortuous left vertebral artery (VA) (white arrow: tip of the support guiding catheter, white arrow head: tortuous site of the left VA). Penumbra 5MAX ACE (Penumbra, Alameda, California, United States) is induced through the DAGC using Marksman (Medtronic, Dublin, Ireland), and Transend EX (Stryker, Kalamazoo, Michigan, United States). (B) The left VA angiogram shows distal basilar artery occlusion (white arrow: tip of the aspiration catheter, white arrow head: tip of the microcatheter, double white arrow head: occlusion site, double arrow: imaging defect due to dentures). The Penumbra 5MAX ACE is induced to the distal part of the basilar artery, and the thrombus is removed using a direct aspiration first-pass technique. (C) The left VA angiogram shows the achievement of thrombolysis in cerebral infarction 2b of the basilar artery (double arrow: imaging defect due to dentures). The time from puncture to recanalization is 16 minutes.

Comparisons of Outcomes between this Study and Previous Studies

The median age of the patients in this study (78 years) was older than those of four previous major studies (Basics, mean 67 years, BEST, median 62 years, ATTENTION, mean 66 years, BAOCHE, mean 64 years) (►Table 3). Nevertheless, the effective recanalization rate in the current study (84.8%) was higher than that in Basics⁵ (71.5%) or BEST⁶ (71.4%) and slightly inferior to in ATTENTION⁷ (93%) or BAOCHE⁸ (88%). The median time from puncture to recanalization in this study was 44 minutes. The time from puncture to recanalization was significantly shorter than that in ATTENTION (74 min) or BAOCHE (85 min). Regarding functional neurological outcomes, an mRS score less than or equal to 3 was obtained in 13 (41.9%) patients in our study, which was equivalent to the four previous major studies (Basics, 44.2%; BEST, 42.4%; ATTENTION, 46%; BAOCHE, 46%) (►Table 3). The mortality (mRS score 6) at 90 days tended to be lower in this study than in the four previous major studies (25.8 vs. 38.3% [Basics], 33.3% [BEST], 37% [ATTENTION], 31% [BAOCHE]) despite the higher median age in our cohort (►Table 3).

Why Is the DAGC Necessary?

The DAGC is especially effective in patients with severely tortuous vessels where access is difficult using a conventional guiding catheter. Access to the lesion has been achieved at a high rate using recently progressing aspiration catheters through the DAGC. With the conventional method, we need to induce an 8 Fr guiding catheter into the vertebral artery to facilitate treatment with an aspiration catheter. However,

when using a DAGC, we place the tip of the DAGC at the origin of the subclavian artery or brachiocephalic artery and introduce only an aspiration catheter into the vertebral artery, to reduce the likelihood of vasospasm and vascular dissection. Since a DAGC has a shorter full length of 83 cm, it allows us to access distal target lesions with an aspiration catheter. There were no instances of insufficient effective length.

In endovascular therapy for the anterior circulatory system, direct puncture of the common carotid artery is an option for cases in which the placement of the guiding catheter is difficult. In contrast, the DAGC is convenient for the posterior circulatory system because a direct puncture is almost impossible.

The Neuro EBU (Medtronic, Dublin, Ireland) can be used in a similar manner. However, based on our limited experience, positioning a DAGC is comparatively easier and faster than using the Neuro EBU. This is because the shape of the DAGC resembles the JB2, which matches the shape of the aortic arch. While we tried out the DAGC with steeper tip angles, it was evident that the current tip angle was easier to place and provided stronger support. The Neuro EBU might offer superior support if a patient has an extremely larger gap between the brachiocephalic artery bifurcation and the top of the aortic arch.

Technical Details for Actual Procedures

Several important technical aspects for actual use should be described. Aspiration catheters are usually introduced into the vertebral artery using a microcatheter and a microguidewire after DAGC placement. However, we sometimes had to use a 0.035-inch guidewire to guide the aspiration catheter to the vertebral artery in cases where the angle from the subclavian

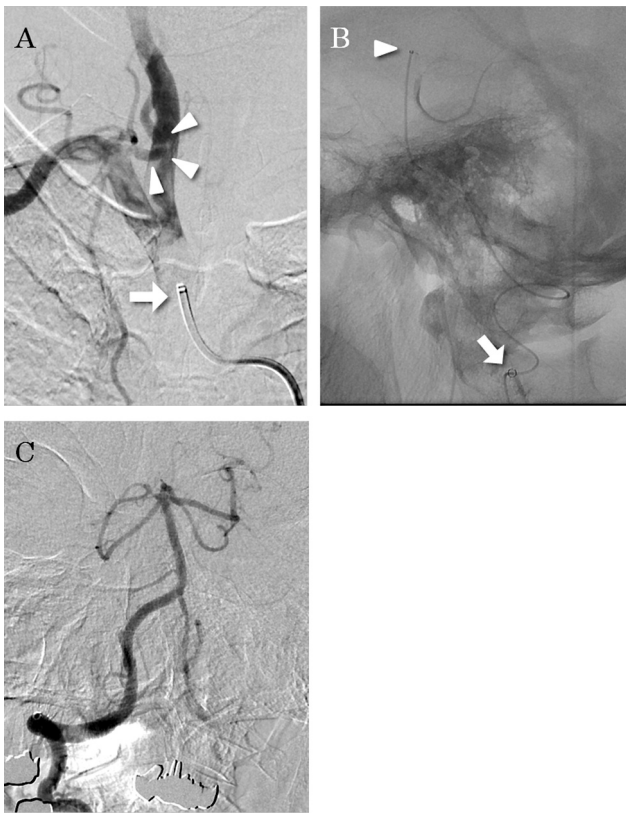


Fig. 4 A 74-year-old woman developed sudden loss of consciousness and quadriplegia. Diffusion-weighted imaging reveals high-intensity areas in the pons, midbrain, and right cerebellar hemisphere. Magnetic resonance angiography reveals hypoplasia of the left vertebral artery (VA). The right VA is occluded intracranially, and the basilar artery is poorly visualized. The right posterior cerebral artery is fed from the posterior communicating artery. A delivery assist guiding catheter is placed at the origin of the brachiocephalic artery. (A) Frontal angiographic view of the brachiocephalic artery shows tortuous right VA (white arrow: tip of the delivery assist guiding catheter, white arrow heads: tortuous site of right VA). Since the Penumbra SMAX ACE cannot be guided intracranially, the velocity microcatheter (Penumbra, Alameda, California, United States) is guided distal to the thrombus. (B) Lateral view shows the situation of injection via a microcatheter, white arrow shows an aspiration catheter at the extracranial region, and white arrowhead shows a tip of the microcatheter at the basilar top. A Solitaire 4 × 20 (Medtronic, Dublin, Ireland) is deployed, and the thrombus is retrieved in the Penumbra SMAX ACE (Solumbra technique). (C) The right VA angiogram shows the achievement of thrombolysis in cerebral infarction 3 recanalization of the basilar artery. The time from puncture to recanalization is 64 minutes.

artery to the vertebral artery was steep and the microcatheter and microguidewire were insufficient for support.

When the aspiration catheter did not reach intracranially, a microcatheter with a long effective length, such as Velocity (Penumbra, Alameda, California, United States), Phenom 21 (Medtronic, Dublin, Ireland), or Trevo track 21 (Stryker, Kalamazoo, Michigan, United States), was useful. Once the approach to the lesion was achieved with a microcatheter, thrombectomy was performed using a stent retriever. However, in the posterior circulatory system, the treatment results were better with aspiration catheters than with a stent retriever.^{15,16}

PTA is sometimes required when stenosis is detected during the procedure. In such cases, inserting a PTA balloon catheter through the aspiration catheter is also possible. When a PTA balloon catheter is required, a longer effective-length catheter, such as the Unryuu (Kaneka, Tokyo, Japan) PTA balloon catheter, is suitable.

Limitations

Although the data were obtained from a prospectively maintained database, the retrospective nature of the study is a limitation. Moreover, this was a single-center study with an inadequate sample size. This was a pilot study to improve the outcomes of endovascular therapy for acute vertebrobasilar artery occlusion in patients with tortuous vessels. In future, prospective randomized studies with larger sample size are necessary.

Conclusion

Despite the high rate of older patients in our cohort, the DAGC appears to contribute to the shortening of recanalization time and equivalent outcomes of endovascular therapies for acute vertebrobasilar artery occlusion.

Authors' Contributions

T.H. was involved in conceptualization, methodology, investigation. T.O. helped in writing the original draft. A. T. did formal analysis. T.I., R.K., and K.S. helped in investigation. S.O. supervised the study.

Ethical Approval

This study was approved by the institutional ethics committee (IEC) (No.253).

Conflict of Interest

None declared.

References

- Berkhemer OA, Fransen PS, Beumer D, et al; MR CLEAN Investigators. A randomized trial of intraarterial treatment for acute ischemic stroke. *N Engl J Med* 2015;372(01):11–20
- Saver JL, Goyal M, Bonafe A, et al; SWIFT PRIME Investigators. Stent-retriever thrombectomy after intravenous t-PA vs. t-PA alone in stroke. *N Engl J Med* 2015;372(24):2285–2295
- Jovin TG, Chamorro A, Cobo E, et al; REVASCAT Trial Investigators. Thrombectomy within 8 hours after symptom onset in ischemic stroke. *N Engl J Med* 2015;372(24):2296–2306
- Goyal M, Demchuk AM, Menon BK, et al; ESCAPE Trial Investigators. Randomized assessment of rapid endovascular treatment of ischemic stroke. *N Engl J Med* 2015;372(11):1019–1030
- Langezaal LCM, van der Hoeven EJ, Mont'Alverne FJA, et al; BASICS Study Group. Endovascular therapy for stroke due to basilar-artery occlusion. *N Engl J Med* 2021;384(20):1910–1920
- Liu X, Dai Q, Ye R, et al; BEST Trial Investigators. Endovascular treatment versus standard medical treatment for vertebrobasilar artery occlusion (BEST): an open-label, randomised controlled trial. *Lancet Neurol* 2020;19(02):115–122
- Tao C, Nogueira RG, Zhu Y, et al; ATTENTION Investigators. Trial of endovascular treatment of acute basilar-artery occlusion. *N Engl J Med* 2022;387(15):1361–1372

- 8 Jovin TG, Li C, Wu L, et al; BAOCHE Investigators. Trial of thrombectomy 6 to 24 hours after stroke due to basilar-artery occlusion. *N Engl J Med* 2022;387(15):1373–1384
- 9 Himeno T, Ota S, Ohtonari T, et al. Efficacy of the insertion-support guiding catheter in approaching intracranial or craniocervical lesions in patients with the difficulty of extracranial trans-arterial access. *J Neuroendovasc Ther* 2020;14(01):36–42
- 10 Turk AS, Frei D, Fiorella D, et al. ADAPT FAST study: a direct aspiration first pass technique for acute stroke thrombectomy. *J Neurointerv Surg* 2014;6(04):260–264
- 11 Kang D-H, Hwang Y-H, Kim Y-S, Park J, Kwon O, Jung C. Direct thrombus retrieval using the reperfusion catheter of the penumbra system: forced-suction thrombectomy in acute ischemic stroke. *AJNR Am J Neuroradiol* 2011;32(02):283–287
- 12 Turk AS, Spiotta A, Frei D, et al. Initial clinical experience with the ADAPT technique: a direct aspiration first pass technique for stroke thrombectomy. *J Neurointerv Surg* 2014;6(03):231–237
- 13 Deshaies EM. Tri-axial system using the Solitaire-FR and Penumbra Aspiration Microcatheter for acute mechanical thrombectomy. *J Clin Neurosci* 2013;20(09):1303–1305
- 14 Humphries W, Hoit D, Doss VT, et al. Distal aspiration with retrievable stent assisted thrombectomy for the treatment of acute ischemic stroke. *J Neurointerv Surg* 2015;7(02):90–94
- 15 Alawieh A, Vargas J, Turner RD, et al. Equivalent favorable outcomes possible after thrombectomy for posterior circulation large vessel occlusion compared with the anterior circulation: the MUSC experience. *J Neurointerv Surg* 2018;10(08):735–740
- 16 Gerber JC, Daubner D, Kaiser D, et al. Efficacy and safety of direct aspiration first pass technique versus stent-retriever thrombectomy in acute basilar artery occlusion—a retrospective single center experience. *Neuroradiology* 2017;59(03):297–304