

ORBITAL VARIX AND ITS SURGICAL CORRECTION - A CASE REPORT

Dr. P.K. Sharma, M.S., M.Ch.

Dr. B. Shukla, M.S., Ph. D.

Dr. B.M. Tripathi, M.D.

Dr. R. Malik, M.D.

(Presented at XXV National Conference APSICON-90,at Pune)

KEY WORDS

Orbit, varicose veins, ligation.

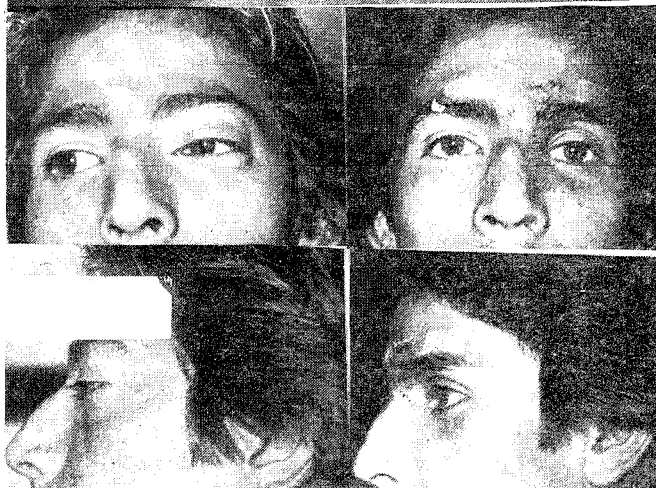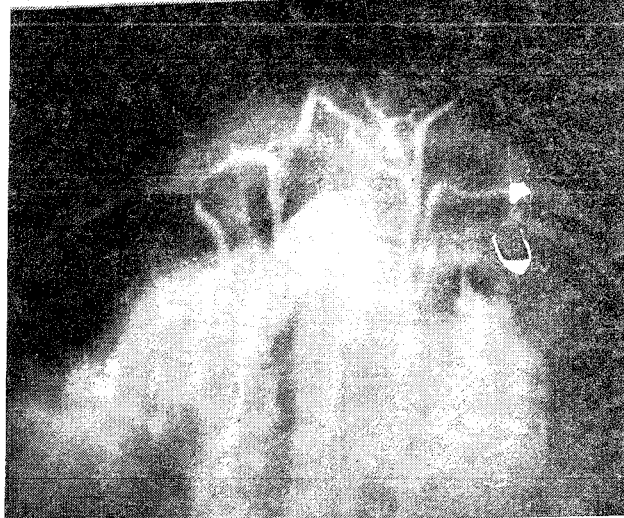
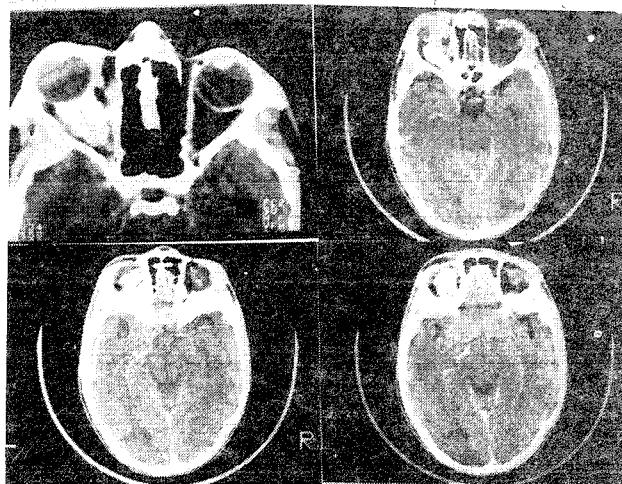ABSTRACT :

A Young patient presented with left unilateral proptosis and Orbital venography was suggestive of orbital vari on left side. An easy and effective operative procedure was planned. The superficial veins around orbit were ligated. Result was acceptable and without complications. This proved an effective and simple approach as against trans-cranial or orbital approach for surgical removal of vari.

INTRODUCTION

A unilateral proptosis during the course of the day if vary in size, it invites considerable anxiety. Such condition is rare. Enophthalmus due to pressure atrophy, blindness due to optic atrophy are, important sequele of this condition. Non-surgical methods have been suggested. Such as, Retrobulbar

injections of sclerosing agents. Surgical correction is usually difficult. Method of ligation of veins for varices is one which is used in the present case.



Photographs showing :

- (i) A bulge left eye.
- (ii) Post - Op.
- (iii) C.T. scan showing ovoid mass postero lateral to globe.
- (iv) Orbital venogram.

CASE REPORT :

An eighteen years old student presented with complaint of bulging of left eye on straining or on lying prone. Dull headache was usually associated. On examination there was fullness of left eye with dilated veins at medial superior quadrant of left eye. The fullness increased on straining. Vision in both eyes was normal and fundus normal. Plain skiagram of left eye was inconclusive. Muscle biopsy of Left orbicularis oculi showed loss of striations and increased intermyceller adipose tissue, suggestive of ocular myopathy. C.T. scan of left orbit showed an intensively enhancing intracoanal mass in posterolateral quadrant of the globe. On asking patient to strain, the size of the lesion increased with outward bulge of the eye-ball.

Ligation of supraorbital vein by supraorbital incision and ligation of anterior facial vein at medial canthus was done. Postoperative period was uneventful. Healing took place without any complications.

DISCUSSION ::

Orbital Varix presents as a aesthetic, emotional and psychological problem. The signs and symptoms are alarming. Only the lucky ones see such a rare case in their life-time. The anomalies are variable in size and extent. Some anomalies confine to the orbit and others extend intracranially through enlarged sphenoidal fissure or bony orbital defect. Optic atrophy in larger lesions is another problem, faced by patient. Duke Elder quotes 15% incidence of blindness in such conditions.

Retrobulbar injections are dangerous if intracranial extension is present. The alternative is surgical removal of varices, which is never easy. It

is extremely difficult to excise extensive vascular anomaly without damaging function of the globe. As reported in some cases lateral orbital decompression helps.

CONCLUSION :

Technique of ligation of supra-orbital and anterior facial veins, is used in the present case. This approach is superficial one for a deeply placed lesion and avoids trauma to optic nerve. No orbital exploration or intracranial approach is required. The present technique is simple, less time consuming, with minimal of scarring and complications. Therefore this technique is a useful one.

AUTHOR NAMES AND ADDRESS

Dr. P.K. Sharma , Reader,

Dr. B. Shukla M.S. P.H.D., Director, Eye Institute.

Dr. B. M. Tripathy, M. D. Reader.

Dr. R. Mallick, M. D., Lecturer.

E-26, 45 Bungalows, Bhopal-462003 (M.P.)

REFERENCES :

1. Campos. Arch. Ophtal. 1947; 7 : 390
2. Duke Elder, S : Text-book of Ophthalmology. Medical Publisher & Bookseller : London. 1952; 5 : 5397.
3. Germain and Weill. : Ann. Oculist. 1928 ; 165 : 542.
4. Lowenstein. Klin. Mol. Augenheilk. 1911 ; 49 : 183.
5. Rumjanzewa, Z. Augenheilk. 1930 ; 71 : 247.
6. Walsh, W.B. AND Dandy, W.E. : **Pathogenesis of intermittent Exphthalmos**. Trans. Amer. J. Ophthalm. 1944 ; 42 : 334.