

# THE DISTALLY BASED ISLAND POSTERIOR-INTEROSSEOUS FLAP - AN EXPERIENCE

---

**Dr. A.K. Singh M.Ch.**  
**Dr. A. Sharan M.Ch.**

## KEY WORDS

Hand function, supple skin cover,  
Elbow function restorations.

## ABSTRACT

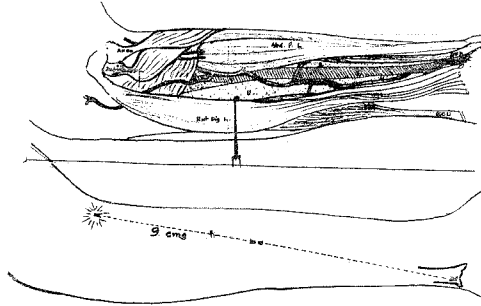
Soft tissue reconstructions of the hand is an exciting challenge for reconstructive surgeon. The choice is between using a distant flap, mono or biaxial with or without delays, a free flap with microvascular anastomosis or an Island flap.

The advent of local flaps radial and other forearm flaps has solved problem admirably (Song et al, 1982; Biemer and Stock, 1983; Soutar and Tanner, 1984; Foucher et al, 1984). However it does involve sacrifice of a major artery to the hand.

## ANATOMY

The forearm skin is supplied by perforating subcutaneous and musculocutaneous arteries which originate from the radial, ulnar, anterior and

posterior interosseous artery (Lamberty and Cormark 1982).



#### Sketch showing

- (i) Marking of posterior interosseous artery between lateral epicondyle and ulnar head.
- (ii) course of (posterior interosseous) artery in forearm.

Posterior interosseous flap is a fasciocutaneous flap based on the posterior interosseous artery which lies in the fascial septum between extensor carpi ulnaris and extensor digiti minimi. Multiple branches come out and spread on the deep fascia to form fascial arcade as well as further branches pass through the deep fascia to supply the underlying deep extensor muscle. In the lower two third direct septo - periosteal branches to the ulna are present (Costa Comba et al, 1991). Source of blood supply to the segment of the ulna is mainly musculo periosteal in its proxima two third and fascio-periosteal in the distal third. Posterior interosseous nerve lies in close approximation after emergence from supinator. Then it runs with the posterior interosseous artery on abductor pollicis longus. Gradually the nerve goes deeper and vessel becomes superficial in the septum.

Posterior interosseous artery has good anastomosis with anterior interosseous arteries at wrist, underneath the extensor tendons. Island flap on posterior interosseous territory can be raised either proximally based or distally based. Proximally based flap is useful for coverage around the elbow. Distally based flap will easily reach the dorsum of the hand to the level of the metacarpophalangeal joints and the first web space of the thumb. This flap survives on a retrograde arterial flow from the dorsal carpal arch via the anastomosis between the posterior interosseous and the anterior interosseous arteries.

Based on these anatomical findings eight clinical cases are described, using this island flap pedicled distally.

#### OPERATIVE TECHNIQUE

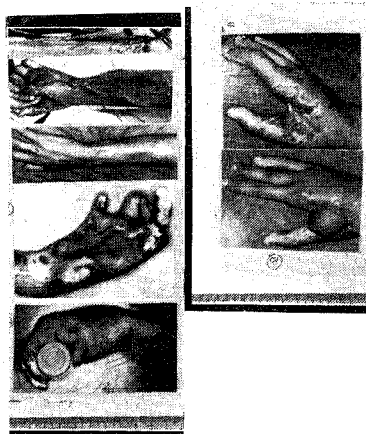
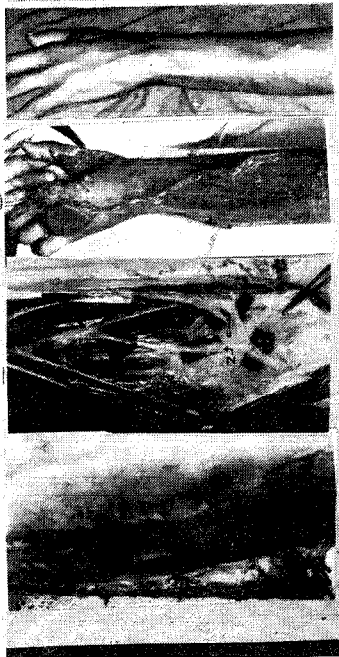Keeping the forearm in full pronation, posterior interosseous artery is marked between the lateral epicondyle and the ulnar head. A point 9 Cm. (range 8-9 cm) distal to the lateral epicondyle marks the center of the distally based flap to be raised (Costa and Soutar, 1988).

The flap is outlined and distal incision extended to the level of deep fascia. The septum between extensor carpi ulnaris and extensor digiti minimi is identified and preserved. Dissection proceeds from distal to proximal upto the distal border of the supinator. This fasciocutaneous flap is raised with septum containing posterior interosseous artery. It is then raised distally upto the wrist. Posterior interosseous artery supplies almost the entire dorsal forearm skin extending from subcutaneous ulnar border around the radial dorsum of forearm and

from 4 cm below the interepicondylar line to the wrist.

in size was taken to cover the wound. Post operative period was uneventful.

**CLINICAL CASE REPORTS**



Photographs showing :

- (i) Staining of post. skin with methylene blue.
- (ii) Relationship of P.I.A. with posterior interosseous nerve.
- (iii) P.I.A. Flap raised.
- (iv) Post burn defect.
- (v) Thumb reconstruction with P.I.A. (distally based).
- (vi) Defect - first web space.
- (viii) With distally based P.I.A. flap. (after 3 weeks.)

**CASE-1**

A 45 yr. old male presented with raw area of dorsum of hand with exposed second metacarpal. Distally based posterior interosseous flap - 6 x 4 cm

**CASE-2**

A 40 year old male sustained roadside accident. The injury comprised of first web space, skin avulsion and fracture of first metacarpal bone. Internal fixation and coverage of web space with 7 x 4 cm posterior interosseous flap was done. Healing was uneventful.

**CASE-3**

A 34 year old female had full thickness thermal burn of dorsum of hand involving first web space, debridement of all dead tissue was carried out to encourage granulations. First web space and dorsum of hand was covered with 7 x 4 cm size posterior interosseous flap. Post operatively there were no complications.

**CASE-IV**

A case 23 year old male sustained thermal burn with loss of thumb at metacarpophalangeal joint level. Flap 6 x 6 cm taking 3 cm cutaneous border of ulna bone was raised. Whole of the composite, osseofacio cutaneous flap was used to increase the length of thumb. K-wire fixation of bone was carried out postoperatively there was gain in length of thumb and grip.

**CASE-V**

A 32 year old female with exposed metacarpophalangeal joint of middle finger was covered by 5 x 4 cm size flap. Postoperative healing was satisfactory.

TABLE 1

Case	Age	Sex	Diagnosis	Etiology	Flap	Size	Donar	-	Area	Complication
1.	45	M	Exposed 2nd Metacaspal with extensor tendon	Crush Injury	Island Skin	6x4	Skin	-	Graft	Nil
2.	40	M	Contracture I web space	Post Traumatic	Island Skin	7x4	Skin	-	Graft	Nil
3.	34	F	Raw area dorsum of hand with I-web space	Post Burn skin	Island	7x4	Skin	-	Graft	Nil
4.	23	M	Loss of thumbs at MP joint Bone	Post Burn Skin +	Island	6x6	Skin	-	Graft	Nil
5.	32	F	Exposed MP joint of middle finger	Post traumatic	Island skin	5x4	Primary	-	closure	Nil
6.		M	Exposed extensor tendon	Crush injury	Island Skin	5x4	Primary	-	closure	marginal necrosis
7.	34	M	Contracture Ist web space	Post Burn	Island skin	8x5	Skin	-	Graft	Nil
8.	39	F	Contracture & Ist web space	Post Burn	Island skin	7x5	skin	-	Graft	Nil

#### CASE-VI

A 27 yr. old male had thrasher injury with loss of skin on dorsum of hand. That was covered with 5 x 4 cm size flap. Post-operative distal marginal necrosis was noted. But wound healed well.

#### CASE-VII

A 39 yr. old male had post thermal burn adduction contracture first web space. Contracture was released and covered by 8 x 5 cm size flap.

#### CASE-VIII

A 34 yr. old female had first-web space adduction contracture which was released and

covered by 7 x 5 cm size flap. Post operative healing was uneventful.

#### DISCUSSION

Distally based island fasciocutaneous flaps in forearm have made management of soft tissue defects of the hand simpler, since they offer one stag procedure, and early physiotherapy and mobilisation is achieved. Radial artery and ulnar artery flaps are a major arterial supply to the hand. Both these flaps cause don area morbidity. Sometimes a tendon exposed during dissection shows delayed healing.

The posterior interosseous vessels offer a valuable blood supply to the skin of the posterior aspect of the forearm. Sacrifice of a minor artery of

the hand achieves comparable results and there is minimal donor defect. This flap can be raised even when radial or ulnar artery or palmar arches are damaged.

In compound posterior interosseous flap the bone is harvested from a region of the ulna which is broad and triangular and the shape allows harvest of an appreciable bone segment while leaving a substantial remnant. Thus fracture of ulna is unlikely. In radial forearm flap. Bone is taken from a region which is tubular and immobilization becomes necessary for some period of time to avoid fracture.

Main concern with this composite Island flap is the length of time required & dissection needs to be carried out in an elegant and delicate manner to achieve success.

#### CONCLUSION

Posterior interosseous vessels provide a good and valuable vascular supply to the posterior aspect of the forearm, which allows elevation of long flap with a wide arc of rotation and a vascularized bone segment also can be harvested.

#### REFERENCES

1. Biemer, E. and Stock, W. (1983). **Total thumb reconstruction : a one stage reconstruction using an osteocutaneous forearm flap.** British Journal of Plastic Surgery, 36, 52.
2. Costa, H., and Soutar, D.S. (1988). **The distally based island flap.** British Journal of Plastic Surgery, 41, 221.
3. Foucher, G., Van Genechten, F., Merle, N. and Michon, J. (1984). **A compound radial artery forearm flap in hand surgery : an original modification of the Chinese forearm flap.** British Journal of Plastic Surgery, 37, 139.
4. Song, R., Gao, Y., Song, Y. and Yu, Y. (1982). **The forearm flap.** Plastic and Reconstructive Surgery, 70, 343.

5. Soutar, D.S. and Tanner, N.S.B. (1984). **The radial forearm flap in the management of soft tissue injuries of the hand.** British Journal of Plastic Surgery, 37, 18.

#### AUTHOR NAMES AND ADDRESS

Dr. Arun K. Singh, Assistant Professor

Dr. Anupam Sharan, Senior Resident

Department of Plastic Surgery, K.G. Medical College,  
LUCKNOW-226 003.