

Dumb - Bell Shape Penis

Dr. U.H. Vyas, M.S.
Dr. Jayesh Brambhatt, M.S.
Dr. Santosh C. Raibagkar, M.S., M.Ch.

KEY WORDS

Religious ritual
Urethral Fistula.

ABSTRACT

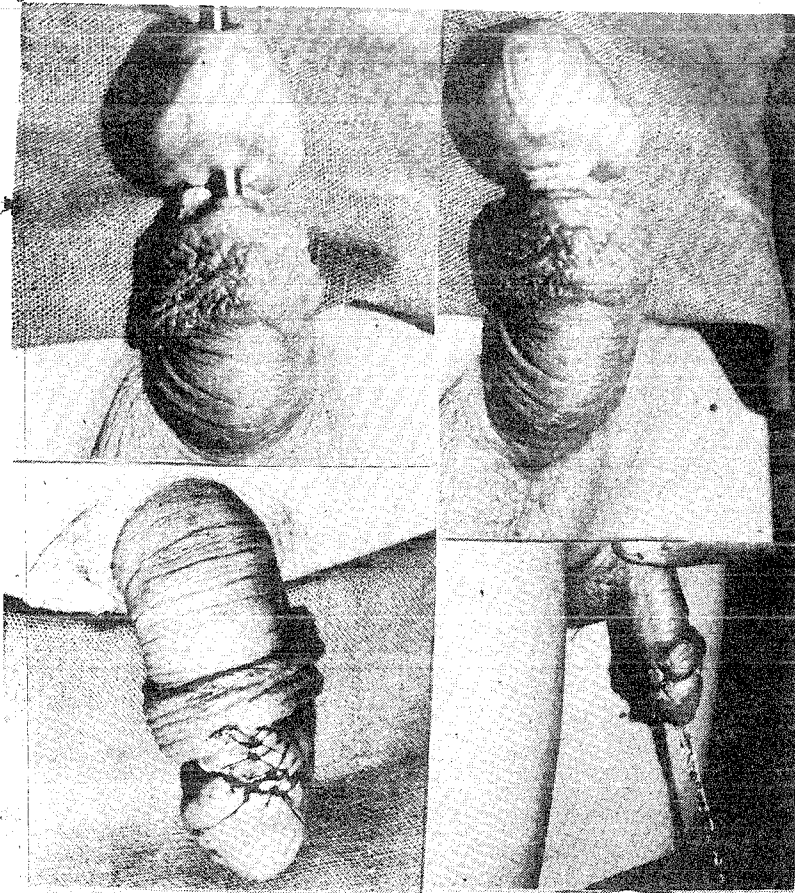
An unusual complication following religious circumcision resulting in urethral fistula is reported.

Jews, Muslims and many African tribes perform circumcision on all their offsprings as a religious ritual in infancy or childhood. This ritual of circumcision is usually performed by religious heads. After circumcision the dressing is applied which is kept in position by tying a cotton thread or a horse hair around it.

A boy aged 6 years presented with the complaints of passing urine through two streams. It was revealed by his parents that he had undergone religious circumcision in early childhood and at that time horse hair was used to hold the dressing.

Clinical examination showed a severe stricture at the sub-glandular level and an urethral fistula at the same site. (Photograph shows dorsal and ventral aspect of dumb bell penis.)

Reconstruction was planned in two stages. In the first stage of reconstruction the objective was to increase vascularity of the glans and intervening tissue. A single 'Z' plasty was performed on dorsal aspects of penis after de-epithelizing the dorsal half of intervening tissue.



Figures :

1. Passage of Dilator Through Normal Urethra and Fistula.
2. Ventral Aspect of Penis.
3. Post Op. with Stitches (Z Plasty.)
4. Normal Single Stream.

Photograph shows post operative view before removal of stitches.

The second stage consisted of refreshing of proximal and distal urethral stumps and end to end anastomosis of both the stumps to establish urethral continuity. A large rectangular skin flap from the ventral aspect was advanced over the anastomosed urethra.

After completion of both stages of reconstruction the boy has near normal appearance of penis and can pass urine from external urinary meatus from the tip of glans.

Photograph shows the result after 3 months with normal stream of urine.

CONCLUSION

Success could be achieved in this case by first improving blood supply to glans by dorsal Zplasty and subsequently after an interval by doing fistula repair and end to end glans to shaft anastomosis.

REFERENCES

1. Claman, J. & Copenhagen H., Circumcision for the newborn. Br. J. Surg. 53 : 427 : 1966.
2. Kaplan G.W. Complications of Circumcision Urol. Clin. North America. 10 (B): 543 :1983.
3. Kelasis King L.R. & Belman AM (ads) Clinical Paediatric Urology 1976.
4. Neonatal Circumcision & Penile Problems, Paediatrics. 1988 Apr. 81 (4) 537 - 41.
5. Patel, H. : Problem of Routine Circumcision Can. Med. Ass. 95 : 576 : 1966.
6. Redman J.F. Urology. 1988, Aug 32 (22) 130 - 2
Rare Penile Anomalies presenting with complications of Circumcision.
7. Wallerstein, E. Circumcision : The American Medical Enigma Rol. Clin. North America. 12 (1) : 123 : 1985.

Author's Name And Address

Dr. U.H. Vyas, Prof & Head
Dr. Jayesh Brambhatt,
Dr. Santosh C. Raibagkar,
Asstt. Hon. Prof. of Plastic Surg.

Plastic Surgery Department,
Smt. S.C. L. General Hospital,
Ahmedabad 380 018.