

# New Technique In Umbilical Reconstruction

---

Dr. A.K. Singh, M.S., M.Ch.  
Dr. P. Mishra, M.S.

## KEY WORDS

Aesthetics.

## ABSTRACT

This paper describes new and easy technique for umbilical reconstruction. Three patients are operated by this technique with good results.

## INTRODUCTION

In most of the cases every effort is made to save umbilicus. However, at times it is not possible to do so. In many procedures such as repair of Umbilical hernia, incisional hernia, umbilicus is sacrificed. Navel is one of the aesthetic landmark and it has its own importance. In females who wear types of clothing where navel is visible, it is of paramount importance. A child operated for umbilicus hernia where umbilicus is sacrificed causes him embarrassment.

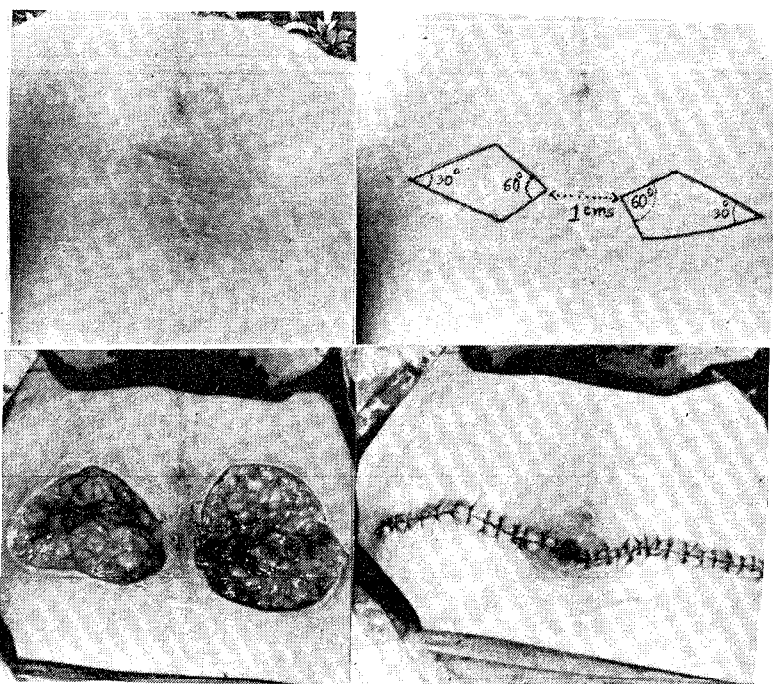
Therefore, umbilical reconstruction is being given due importance. To this date none of the techniques currently in use for its reconstruction have proved satisfactory, in achieving near normal appearance. This is so because of problems encountered which are listed below.

1. Selection of correct site.
2. Laxity of anterior abdominal wall.
3. Existing scars at the site of reconstruction.
4. Failure to achieve adequate depth of the redesigned umbilicus.
5. Aesthetically acceptable appearance of the newly formed umbilicus.

This technique described below gives better results.

#### TECHNIQUE

Proper site of umbilicus is marked in sitting posture slightly above the mid point between xiphoid process and pubic symphysis. A quadrilateral segment of skin is excised along with subcutaneous tissue on each side of proposed navel as shown in the photograph.



#### Figures :

1. Scarred Umbilical Area
2. Markings on Either Side of Proposed Navel.
3. Defect Created by Quadrilateral Segment Excision of Skin and Subcutaneous Tissue.
4. Inverted Dog ear at Medial Angle.

Medial angles are separated from each other by about 1 cm. distance and are of  $60^\circ$ . Defect is then sutured with 4/0 Nylon from lateral to medial end, as a result of which inverted dog ear is created at the medial angles and none at its lateral edges. In

children, skin is usually tight and approximation is often difficult.

#### OBSERVATION

Three patients were operated by this technique. All three patients had different factors responsible for losing their navel.

#### DISCUSSION

This technique has following advantages.

1. Easy to reconstruct.
2. Umbilicus with almost normal shape, size and depth is reconstructed.
3. This technique results in linear scar in the abdomen which remains hidden in abdominal folds.
4. Also improve abdominal contour.

#### REFERENCES

1. Blodgett, J.B. (1941) : Transumbilical repair of congenital umbilical hernia. *Surgery, Gynecology and Obstetrics*, 72; 632.
2. Borges, Albert F (1975) : Reconstruction of the umbilicus. *British Journal of Plastic Surgery*.
3. Ethicon Inc : "Manual of operative procedures and surgical knots" 12th edition. New Jersey : Ethicon Inc.
4. Farris, J.M. (1964) : Umbilical hernia, In "Hernia" edited by L.M. Nyhus, H.N. Harkins, Philadelphia, J.B. Lippincott.

#### Author's Name And Address

Dr. A.K. Singh, M.S. M.Ch. Lecturer,  
Dr. P. Mishra, M.S., Senior Resident.

Department of Plastic surgery, King George's  
Medical College, Lucknow.