




Contralateral Endoscopic Approach for a Rare Case of Neuroglial Cyst

Deepak Kumar Singh¹ Kshitij Sinha¹ Rakesh Kumar Singh¹ Vipin Kumar Chand¹ Neha Singh²
Arun Kumar Singh¹ Krishan Kumar¹

¹Department of Neurosurgery, Dr Ram Manohar Lohia Institute of Medical Sciences, Lucknow, Uttar Pradesh, India

²Department of Radiology, Dr Ram Manohar Lohia Institute of Medical Sciences, Lucknow, Uttar Pradesh, India

Address for correspondence Dr. Kshitij Sinha, MCh, Department of Neurosurgery, Dr Ram Manohar Lohia Institute of Medical Sciences, Lucknow, Uttar Pradesh, India (e-mail: kshitij.sinha0023@gmail.com).

Indian J Neurosurg

Abstract

Neuroglial cysts are very rare benign lesions of the brain, accounting for up to 1% of all intracranial cysts. Various intracranial locations such as parenchyma, ventricles, subarachnoid spaces, and rarely the spinal cord have been reported. The clinical features vary according to the site of the cyst ranging from being asymptomatic to having headache, seizures, and hemiparesis. It is most commonly seen in infants and children but can be seen in adults too. This rare case is of a middle-aged woman presenting with complaints of headache and left-sided hemiparesis. We report a rare case of a right-sided neuroglial cyst for which a contralateral endoscopic approach was taken for the surgery. Endoscopic cyst fenestration is an ideal modality to treat neuroglial cyst. The contralateral endoscopic approach to treat neuroglial cyst is a better option with the advantage of minimal invasiveness along with better visualization of ventricles and easy maneuverability of the endoscope within the ventricles and surrounding anatomy.

Keywords

- ▶ neuroglial cyst
- ▶ neuroepithelial cysts
- ▶ gliopendymal cysts
- ▶ contralateral approach
- ▶ endoscopic
- ▶ navigation guided

Key Message

Endoscopic cyst fenestration is an ideal modality to treat neuroglial cysts. The contralateral endoscopic approach to treat a neuroglial cyst is a better option with the advantage of minimal invasiveness along with better visualization of the ventricles and easy maneuverability of the endoscope within the ventricles and surrounding anatomy.

Introduction

Neuroglial cysts are very rare benign lesions of the brain accounting for up to 1% of all intracranial cysts.¹ Although there are various theories regarding the origin of these cysts, most neuroglial cysts arise from the ectopic ependymal cells. They have ectodermal origin consisting of capsule lined by

ependymal epithelium, connective tissue, and glial layer.^{2–4} Various intracranial locations such as parenchyma, ventricles, subarachnoid spaces, and rarely the spinal cord have been reported. The clinical features vary according to the site of the cyst ranging from being asymptomatic to headache, seizures, and hemiparesis. It is most commonly seen in infants and children, but can be seen in adults also. This case is of a middle-aged woman presenting with complaints of headache and left-sided hemiparesis.

Case Report

A 55-year-old right-handed woman came to our outpatient department (OPD) with complaints of mild headache and gradually increasing left-sided hemiparesis for the last 1 year along with difficulty in walking. On examination, the power

DOI <https://doi.org/10.1055/s-0043-1775747>.
ISSN 2277-954X.

© 2023. The Author(s).

This is an open access article published by Thieme under the terms of the Creative Commons Attribution License, permitting unrestricted use, distribution, and reproduction so long as the original work is properly cited. (<https://creativecommons.org/licenses/by/4.0/>)

Thieme Medical and Scientific Publishers Pvt. Ltd., A-12, 2nd Floor, Sector 2, Noida-201301 UP, India

of the left upper limb was 2/5 and that of the left lower limb was 2/5. Noncontrast computed tomography (NCCT) of the head (►Fig. 1A & B) of the patient was done, which showed a right-sided parieto-occipital cyst with a midline shift. The patient underwent magnetic resonance imaging (MRI) of the brain (►Fig. 1C & D), which revealed a cyst in the right parieto-occipital region having a cerebrospinal fluid (CSF) intensity consistent with a neuroglial cyst along with a midline shift of approximately 8 mm to the left.

Procedure

Neuronavigation (StealthStation S7; ►Fig. 2) was used in this case to confirm the entry point along with the trajectory. The patient underwent endoscopic fenestration of the neuroglial cyst to the right lateral ventricle via the contralateral (left) approach. The endoscope was inserted in the left ventricle whereby septostomy (►Fig. 3A) was performed. The endoscope was further advanced to the right ventricle and identification of the cyst was done. Wide fenestration of the cyst wall was made (►Fig. 3B). A contrast (Omnipaque 300) was put in to confirm the fenestration, which was confirmed intraoperatively by fluoroscopy and later on by post-op NCCT the head (►Fig. 4A).

Postoperatively, the patient tolerated the surgery well with improvement in headache and subtle improvement in the

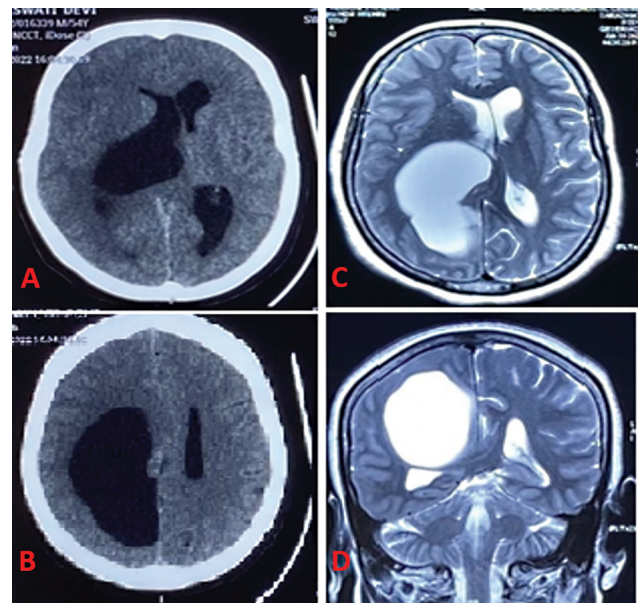


Fig. 1 (A,B) Noncontrast computed tomography (NCCT) of the head showing right parieto-occipital neuroglial cyst with a midline shift toward the left. Effacement of the sulci with dilated left ventricle is also evident. (C,D) Axial T2 magnetic resonance imaging (MRI) and coronal T2 MRI having the same intensity as cerebrospinal fluid (CSF) with effacement of the sulci.

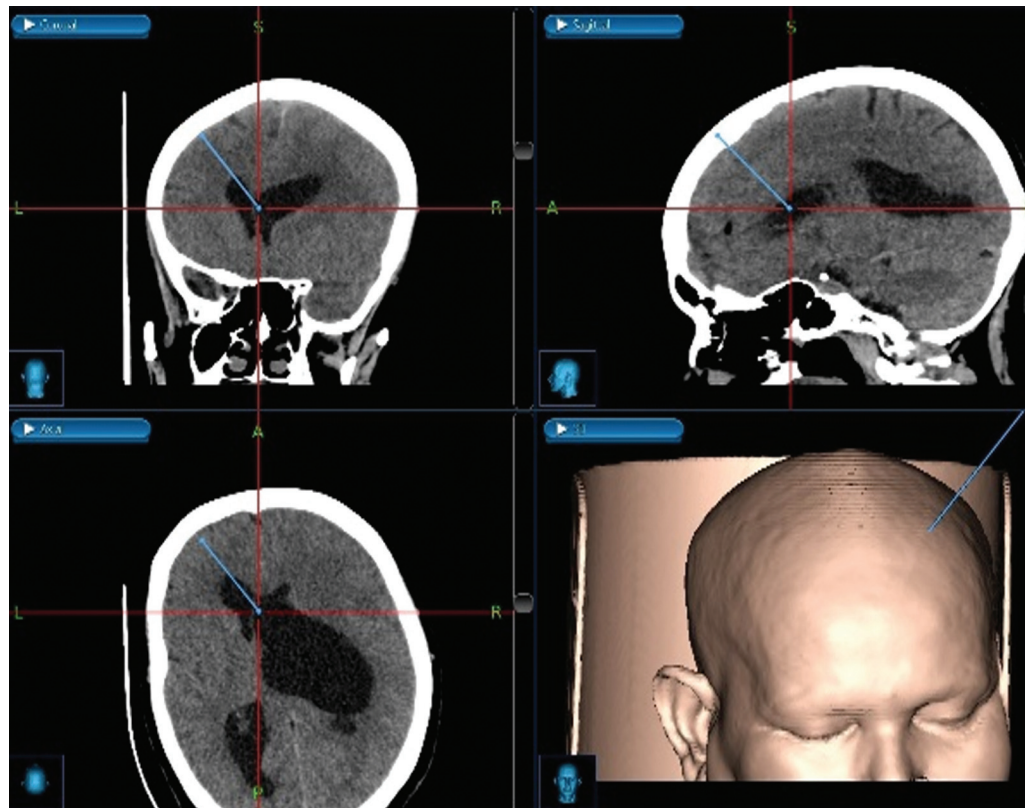


Fig. 2 Neuronavigation (StealthStation S7) confirms the best trajectory in this case. The contralateral approach seems to be a better option to reach the cyst. The compressive effect from the cyst can be seen, which leads to crowding of the anatomy and narrowing of the ipsilateral ventricle. Also, this trajectory ensures that proper fenestration of the cyst can be achieved easily.

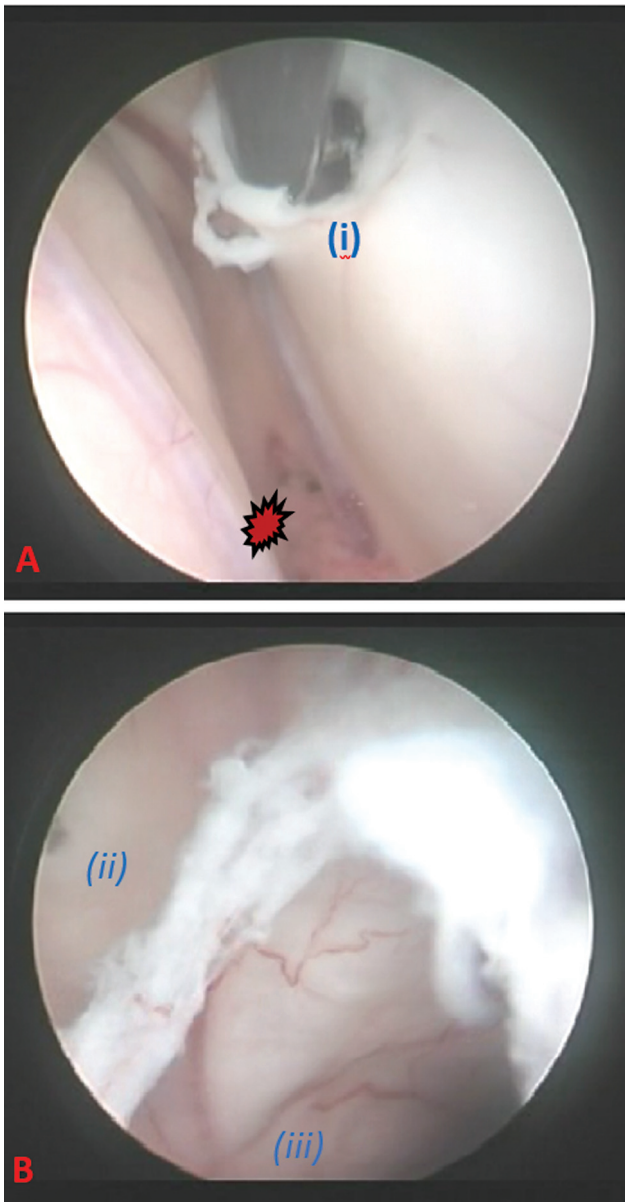


Fig. 3 (A) Ease of maneuverability of an endoscope (Aesculap) inside the left ventricle. By septostomy, the right ventricle was entered and identification of the cyst wall was done. denotes choroid plexus. (B) (i) Septostomy site. (ii) Ventricle cavity. (iii) Neuroglial cyst cavity after fenestration. With wide cyst fenestration done, the ventricle as well as the cyst can be seen.

power of the left upper limb in the immediate post-op period. On the follow-up after 1 month, the patient had regained full power of her left upper and lower limbs and was able to walk independently. Follow-up head NCCT showed disappearance of the neuroglial cyst with no midline shift (→ **Fig. 4B**).

Discussion

Neuroglial cysts, also known as neuroepithelial cysts or gliependymal cysts, have been very rarely reported in adults. The most commonly accepted hypothesis is that they originate early in embryogenesis and therefore most of the reported cases are in fetuses and infants.

With the completion of neurulation at the end of week 4 of embryogenesis, its entire wall is made up of neuroepithelial cells that form the pseudostratified epithelium or neuroepithelium. The cells give rise to neuroblasts and glioblasts, which form neurons and glial cells, respectively. Gradually in the following weeks, both these cells migrate from the deep zone to the intermediate and outer zones near the surface of the brain cortex. The cavity of the neural tube enlarges to form the ventricular system, which is lined by ependymal cells and in some part by well-vascularized pia, forming the tela choroidea. Tela is invaginated by blood cells, which form a choroid plexus.

Several theories have been developed, of which Friede and Yasargil's⁵ hypothesis regarding the displacement of the tela toward the brain parenchyma or the subarachnoid space is widely accepted. This theory also explains the different intracranial locations and cyst histological types.

The term (NEUROGLIAL CYST) was given by Friede and Yasargil in 1977^{6,7} and constitutes the rarest (<1%) form of cystic lesion of the brain with an intracerebral or extracerebral origin. Very rarely it may be located in the spinal cord or anywhere along the neuraxis, but does not communicate directly with the ventricles although it has the propensity for it.⁵ The most common site is periventricle of the frontal lobe.

The symptoms can manifest according to the location of the cysts.^{8,9} Supratentorial cysts may manifest as headache, seizures, motor deficits, and cognition defects. In children, developmental defects such as corpus callosal anomaly can be present,¹⁰ while infratentorial cysts can present as dizziness, diplopia, and hemifacial spasm.

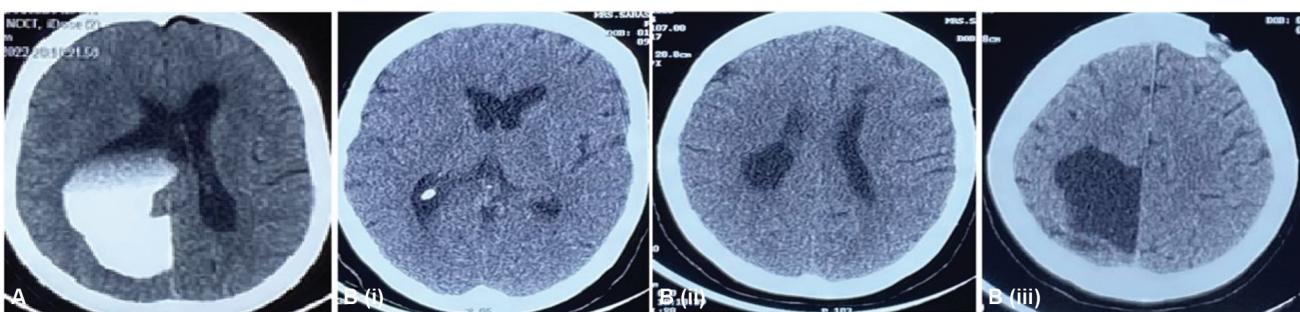


Fig. 4 (A) The contrast (Omnipaque 300) given inside the neuroglial cyst to confirm patency of the stoma can be seen in the immediate post-op noncontrast computed tomography (NCCT) of the head.¹¹ (B) NCCT of the head at 6 weeks shows disappearance of neuroglial cyst with no midline shift. The sulci are visible with no effacement.

Table 1 Previous reported cases of neuroglial cyst

Study	Age	Location	Number	Clinical feature	Intervention
Wu ¹²	Congenital	Cerebral convexity	Single	Routine USG	Shunt
Hassan ¹²	Congenital	Midline	Single	Hydrocephalus	Pregnancy termination
Pelkey ¹²	Congenital	–	Single	Routine USG	Nil
Tange et al ⁹	Neonate	Interhemispheric	Single	Corpus callosum agenesis	Partial excision with a cystoperitoneal shunt
Pawar ¹²	14 y	Temporal horn of the lateral ventricle	Single	Headache, seizures, and proptosis	Excision
Obaldo ¹²	Congenital	Middle cranial fossa	Single	Proptosis	Excision with cystoperitoneal shunt
Muhler ¹²	Congenital	Occipital cyst	Single	Ventriculomegaly	Pregnancy termination
Zheng ¹³	3 mo	Temporal periventricle	Single	Hydrocephalus	Endoscopic fenestration
Cho ¹³	4 mo	Midline anterior	Single	Hydrocephalus	Partial resection
Mustapha et al ¹⁴	10 y	Occipital cyst	Multiloculated	Headache and seizures	Endoscopic fenestration
Desita et al ¹⁵	29 y	Parietal cyst	Single	Left-sided paresis and slurring of speech	Craniotomy with excision

MRI is the preferred diagnostic modality for detecting these cysts. T1 images are hypointense, while the T2 images are hyperintense without any contrast uptake. The cyst in CT is similar to CSF with smooth rounded border and is normally unilocular.

Many different treatment modalities have been suggested although a unanimous agreement on the procedure of choice is still lacking due to the rarity of these cases. Previously reported cases with their treatment have been shown in ► **Table 1**.

For asymptomatic patients, regular follow-up is done. In symptomatic patients, various surgical management such as cystoperitoneal shunts, cystoventricular bypass, craniotomy with excision of the cyst wall with or without fenestration, or a combination of various procedures can be done.

Open craniotomy is itself an invasive and long procedure that increases morbidity along with a prolonged hospital stay. The disadvantage of having a shunt is placement of the external hardware with risk of malfunction later on. In this patient, we have done endoscopic fenestration of the cyst wall into the ventricles from the contralateral side. An advantage of this procedure is minimal invasiveness with low morbidity. The patient can also return home with a short hospital stay.

The large size of the cyst has a compressive effect that makes it difficult to identify the anatomy of the ventricle if the endoscope is used ipsilaterally. Upon entering the ventricle, the visibility is further hampered by high proteinaceous material of the cyst. The problem can be overcome by introducing the endoscope via the contralateral side, which gives a better working space in the narrow corridor of the ventricle. This helps in identification of the anatomical landmarks along with better visualization within the ventricles as well. The endoscope can also cross the midline easily without damage to the surrounding structures.

The contralateral approach has the additional advantage of achieving a better working trajectory of the endoscope in

this case. Thus, improved maneuverability of the endoscope within the narrow space of the ventricles helps identify the anatomy and make interventions with ease. Wide cyst fenestration with communication through the thinnest part of the lateral ventricle is done, thereby achieving desired results with restoration of the CSF channels. This approach provides a better trajectory and working angle and thus prevents trauma within the ventricle and neurovascular structures, thus reducing procedure-related morbidities.

The final patency of the stoma thus created was confirmed by giving dye and doing an intraoperative ventriculography.¹¹

Conclusion

Endoscopic cyst fenestration is an ideal modality to treat neuroglial cysts. The contralateral endoscopic approach to treat neuroglial cysts is a better option with the advantage of minimal invasiveness along with better visualization of the ventricles and easy maneuverability of the endoscope within the ventricles and the surrounding anatomy.

Patient's Consent

A full and detailed consent from the patient/guardian has been obtained. The patient's identity has been adequately anonymized. If anything related to the patient's identity is shown, adequate consent has been taken from the patient/relative/guardian. The journal will not be responsible for any medicolegal issues arising out of issues related to the patient's identity or any other issues arising from the article.

Note

The authors hereby certify that the work shown here is genuine, original, and not submitted anywhere, either in part or in full. All the necessary permissions from the

patient, hospital, and institution were obtained for submitting this article.

Conflict of Interest

None declared.

References

- 1 Osborn AG, Preece MT. Intracranial cysts: radiologic-pathologic correlation and imaging approach. *Radiology* 2006;239(03):650–664
- 2 Harada A, Takeuchi S, Inenaga C, et al. Hemifacial spasm associated with an ependymal cyst in the cerebellopontine angle. Case report. *J Neurosurg* 2002;97(02):482–485
- 3 Park CH, Hyun SJ, Kim KJ, Kim HJ. Spinal intramedullary ependymal cysts: a case report and review of the literature. *J Korean Neurosurg Soc* 2012;52(01):67–70
- 4 Rai HH, Khan MF, Enam SA, Hashmi I. Co-existing spinal intradural ependymal cyst and sacral Tarlov cyst in adult-onset tethered cord syndrome with syringomyelia: case report and literature review. *Surg Neurol Int* 2016;7(Suppl 25):S708–S710
- 5 Friede RL, Yasargil MG. Supratentorial intracerebral epithelial (ependymal) cysts: review, case reports, and fine structure. *J Neurol Neurosurg Psychiatry* 1977;40(02):127–137
- 6 Osborn AG, Salzman KL, Jhaveri MD, Barkovich AJ. *Diagnostic Imaging: Brain*. 3rd ed. Philadelphia, PA: Elsevier; 2020
- 7 Frazier J, Garonzik I, Tihan T, Olivi A. Recurrent gliopendymal cyst of the posterior fossa: an unusual entity containing mixed glial elements. Case report. *J Neurooncol* 2004;68(01):13–17
- 8 Barth PG, Uylings HB, Stam FC. Interhemispherical neuroepithelial (glio-ependymal) cysts, associated with agenesis of the corpus callosum and neocortical maldevelopment. A case study. *Childs Brain* 1984;11(05):312–319
- 9 Tange Y, Aoki A, Mori K, Nijima S, Maeda M. Interhemispheric gliopendymal cyst associated with agenesis of the corpus callosum: case report. *Neurol Med Chir (Tokyo)* 2000;40(10):536–542
- 10 Monaco P, Filippi S, Tognetti F, Calbucci F. Gliopendymal cyst of the cerebellopontine angle. *J Neurol Neurosurg Psychiatry* 1995;58(01):109–110
- 11 Husain M, Singh DK, Rastogi M, Ojha BK, Chandra A, Gupta RK. Intraoperative ventriculo-stomographic evaluation of endoscopic cerebrospinal fluid diversion and flow restoration procedures. *Br J Neurosurg* 2010;24(06):672–678
- 12 Umredkar A, Mohindra S, Gupta R, Bal AK. Contrasting behavior of glio-ependymal cysts: a report of two cases and literature review. *Neurol India* 2010;58(04):659–661
- 13 Robles LA, Paez JM, Ayala D, Boleaga-Duran B. Intracranial gliopendymal (neuroglial) cysts: a systematic review. *Acta Neurochir (Wien)* 2018;160(07):1439–1449
- 14 Mustapha O, Allali N, Latifa C, El Haddad S. Epilepsy as a presentation of a neuroglial cyst associated with dysgenesis of corpus callosum in a child. *Case Rep Radiol* 2021;2021:6675071
- 15 Desita F, Ferriastuti W, Fauziah D. Unusual presentation of a neuroepithelial cyst: a case report. *Radiol Case Rep* 2022;17(11):4384–4387