



Rod Migration into the Posterior Cranial Fossa after C1–C2–C3–C4 Screw Fixation: Case Report and Review of the Literature

Igor Vadimovich Basankin¹ Vladimir Alekseevich Porkhanov¹ Abram Akopovich Giulzatyan¹
 Pavel Borisovich Nesterenko¹ Eduard Romanovich Khurshudyan¹ Marina Igorevna Tomina¹
 Ivan Evgenievich Gritsaev¹ Karapet Karapetovich Takhmazyan¹ Sergey Borisovich Malakhov¹

¹Research Institute Krasnodar Regional Hospital 1 after Prof. S.V. Ochapovsky Spinal Surgery Department N°3, Krasnodar, Russia

Indian J Neurosurg 2024;13:73–75.

Address for correspondence Giulzatyan Abram Akopovich, MD, PhD, Research Institute Krasnodar Regional Hospital 1 after Prof. S.V. Ochapovsky Spinal Surgery Department N°3, Russia, 350086, Krasnodar, 1 May street, Krasnodar, Russia (e-mail: abramgulz@gmail.com).

Abstract

Keywords

- ▶ cervical spine
- ▶ complication
- ▶ neurosurgery
- ▶ rod migration
- ▶ screw fixation

Screw loosening, avulsion, fracture, and rod migration are mechanical complications associated with dorsal fixation of the cervical spine. These usually occur in the late postoperative period and range from 2 to 5%. In this article, we describe a rare case of rod migration into the posterior cranial fossa 4 years after C1–C2–C3–C4 screw fixation in a patient with traumatic fracture of the C2 and C3 vertebrae.

Introduction

Axial and subaxial cervical spine posterior screw fixation is performed in various pathologies, such as traumatic injuries; degenerative, infectious, and oncological diseases; congenital and acquired deformities; rheumatoid arthritis; and ankylosing spondylitis.^{1–5} Over the past decade, with the introduction of navigation systems, the efficiency and safety of posterior fixation has increased; however, there are still different complications that can adversely affect the outcome of surgical treatment.⁶

In this article, we describe a rare case of rod migration through the occipital bone into the posterior cranial fossa after C1–C2–C3–C4 screw fixation in a patient with traumatic injury of C2 and C3.

Case Report

A 25-year-old patient got a severe concomitant injury in 2018 because of a traffic accident involving fractures of C2

(type C by AO Spine) and C3 (type A4 by AO Spine). His neurological status at presentation was American Spinal Injury Association (ASIA) Impairment Scale grade A and Glasgow Coma Scale (GCS) score of 13. Associated injuries were traumatic brain injury (subarachnoid hemorrhage), left third to ninth rib fractures and hemothorax, spleen rupture, stable pelvic, and distal ulna fracture (Injury Severity Score [ISS] = 48 points).

After emergency surgical care, on the 10th day, the patient underwent a C1–C4 posterior fixation with an eight-screw system.

The postoperative period was uneventful. The patient was discharged on the eighth day without neurological deficit. The patient was recommended to wear hard cervical collar for 3 months.

Four years after the operation, the patient admitted to the clinic with severe pain in the cervical spine and occipital region, visual impairment, and nausea.

Objectively palpation of the cervical spine is painful. The muscle strength in the upper and lower limbs was grade 5.

article published online
October 31, 2023

DOI <https://doi.org/10.1055/s-0043-1775735>.
ISSN 2277-954X.

© 2023. The Author(s).

This is an open access article published by Thieme under the terms of the Creative Commons Attribution License, permitting unrestricted use, distribution, and reproduction so long as the original work is properly cited. (<https://creativecommons.org/licenses/by/4.0/>)
Thieme Medical and Scientific Publishers Pvt. Ltd., A-12, 2nd Floor, Sector 2, Noida-201301 UP, India

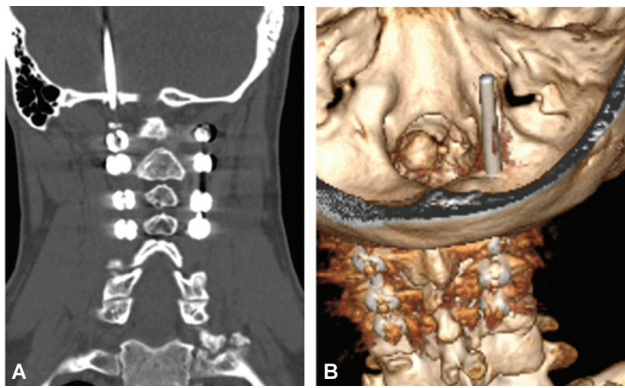


Fig. 1 (A,B) Perforation of the squamous part of the occipital bone and rod migration. Unlocking of the right C1 screw fixation node.

Staggering gate, dynamic coordination tests with a slight intention.

According to computed tomography (CT) of the brain and cervical spine, there was complete unlocking of the nut in the right screw in C1 and complete cranial rod migration into the posterior cranial fossa with perforation of the occipital bone (→Fig. 1).

Considering the identified changes on CT, we performed an urgent operation for removal of the spine fixation hardware and the rod from the posterior cranial fossa. The duration of the operation was 40 minutes. Blood loss was up to 50 mL.

The patient was discharged in a satisfactory condition on day 5 after the surgery. There was a regression of nausea and pain. At follow-up after 3 months, there was no complaint from the patient and he was being treated by an ophthalmologist.

Discussion

Biomechanical complications include screw loosening, avulsion, fracture, and rod migration.⁷ Mechanical complications usually diagnosed in the late postoperative period and range from 2 to 5%.⁸

According to the literature, rod migration into the posterior cranial fossa is a rare complication that requires urgent surgical surgery. We were able to find six studies on this issue in the PubMed and Medline databases.⁹

Of all the cases described, one patient died, one remained disabled, and the remaining four cases, like the one presented here, survived without any serious incidents. In three cases, the rod migrated through the foramen magnum, and in three other cases the migration was through the squamous part of the occipital bone. The age of the patients ranged from 13 to 70 years (average: 41.5 years). Migration occurred 18 months to 15 years after the primary operation. Laminectomy did not affect the development of complications.

In our observation, migration of the rod into the posterior cranial fossa was diagnosed 4 years after the primary surgery. In our opinion, the reason for the rod migration may be the anatomical and functional features of the cervical

spine, as well as the biomechanical aspects of the spine functioning under rigid fixation.

In case of only posterior screw fixation, the facet joints are blocked and their mobility is limited. On the other side, disk mobility is preserved, which leads to a chronic increased load on the elements of the rigid fixation system and increases the risk of developing mechanical complications, especially in the long-term period. One of these scenarios is possible: a fracture of the rod/screw, rod migration, or screw loosening. In the case of spontaneous unlocking of one of the fixation nodes, it may create a movable damping system and gradual weakening of the remaining blocking nodes. In this situation, the rod acquires the ability to move longitudinally in the heads of screws toward the unlocked point due to multidirectional movements in the cervical spine. Polyaxial screws contribute to this. Considering the presence of cervical lordosis and the mobility of the screw heads, the rod begins to migrate according to the principle of a “piston mechanism.” The rod moves usually in the cranial direction.

Cranial movement of the rod brings the proximal end of the rod closer to the skull. The point of entry of the migrating rod into the cranial cavity depends, in our opinion, on the location of the screw heads. In the case of a medial and deep location of the screw heads, the most likely entry site is the foramen magnum, while with a more lateral and superficial location of the screw heads, a defect is formed in the skull and the rod penetrates through it.

Conclusion

The literature shows that in a few cases this is a life-threatening complication. However, it is most often a controlled complication and the treatment outcome is favorable. Removal of a migrated rod is a technically simple procedure.

Conflict of Interest

None declared.

References

- Gubin AV, Burtsev AV. Posterior screw fixation of the craniofacial junction. *Hirurgiâ Pozvonočnika* 2014;(02):42–48
- Aleynik AY, Mlyavykh SG, Bokov AE. Transpedicular screw fixation of cervical spine: literature review and clinical data. *Hirurgiâ Pozvonočnika* 2017;14(03):47–53
- Magomedov SS, Dokish MYu, Tatarintsev AP. Transpedicular free-hand fixation in the subaxial cervical spine. *Hirurgiâ Pozvonočnika* 2018;15(03):13–22
- Basankin IV, Giulzatyan AA, Nesterenko PB, Bagaudinov AB, Tayurski DA, Mukhanov ML Experience of using transpedicular osteosynthesis in traumatic spondylolisthesis of the axis. *Sovrem Tekhnologii Med* 2021;13(05):47–53
- Norkin IA, Chekhonatsky AA, Ninel VG, Ostrovsky VV. Treatment of cervical spine fracture in a patient with Bekhterev's disease. *Hirurgiâ Pozvonočnika* 2007;(02):23–25
- Badiee RK, Mayer R, Pennicooke B, Chou D, Mummaneni PV, Tan LA. Complications following posterior cervical decompression and fusion: a review of incidence, risk factors, and prevention strategies. *J Spine Surg* 2020;6(01):323–333

- 7 Kiran B, Sharma A, Prashant G, Parekh A. A case report of rod migration into cerebellum through foramen magnum after lateral mass fixation of cervical spine. *Acta Neurochir (Wien)* 2016;158(04):741–744
- 8 Deen HG, Nottmeier EW, Reimer R. Early complications of posterior rod-screw fixation of the cervical and upper thoracic spine. *Neurosurgery* 2006;59(05):1062–1067, discussion 1067–1068
- 9 Ezzat AA, Salah AM. Rod migration through foramen magnum into posterior fossa after cervical spine lateral mass fixation: a case report and literature review. *Surg Neurol Int* 2022;13:514