

## OPEN RHINOPLASTY AND USE OF MODELLING WAX SPLINT ON INDIAN PATIENTS

Mita Prasanna

Department of Plastic Surgery, Kasturba Medical College, Manipal.

**SUMMARY :** *Learning and teaching of rhinoplasty by the 'open' method is becoming popular because of better exposure of the nasal skeleton than with the closed (endonasal) technique.*

*25 patients of rhinoplasty or septorhinoplasty done by this approach in the Plastic Surgery Department of Kasturba Medical College, Manipal have been retrospectively analysed to find out its advantages and disadvantages, particularly in Indian patients. Primary or secondary open rhinoplasties were done for augmentation, reduction, correction of deviation or gross deformities and tip-plasty. Splints applied for all these cases post-operatively were made of dental modelling wax.*

*The open approach can be recommended on Indian patients also, for all rhinoplasties demanding excellent exposure, and the resulting scar is insignificant. The main advantage is precision in restructuring and the disadvantage is prolonged tip-oedema. Splint made of modelling wax is useful because it is cheap, light in weight and easy to mould.*

### INTRODUCTION

Open rhinoplasty has gained considerable acceptance over more than 10 years because it affords good access and exposure for extensive and precise surgical manipulation of the nasal skeletal structure. Columellar incision has become the incision of choice even in black patients<sup>1</sup>. A retrospective study was aimed at identifying the pros and cons of (a) open rhinoplasty technique and (b) moulding wax (dental) splint used in the post operative period.

### MATERIALS AND METHOD

A retrospective study of 25 consecutive patients of rhinoplasty (excluding cleft lip-noses) done by the same surgeon (the author) at Kasturba Medical College, Manipal was done. The patients were grouped as per indication, for (a) augmentation, (b) reduction (c) correction of deviation (d) correction of gross deformities and (e) tip-plasty. All the patients were admitted a day prior to surgery and put on antihistamine and prophylactic antibiotic after sending a nasal swab for culture and sensitivity. Detailed documentation of nasal deformities and plan for their correction was done. Close-up photographs of face were taken in four standard views.

### OPERATIVE TECHNIQUE

For personal convenience, all rhinoplasties were done under general anaesthesia and by external

approach (i.e. open method). Septoplasty by the standard technique was done for respiratory obstruction and/or cosmetic reasons. Septoplasty through Killian's incision was completed before making an open-rhinoplasty incision, using an inverted "V" incision at the narrowest part of columella, extended laterally as marginal incisions.

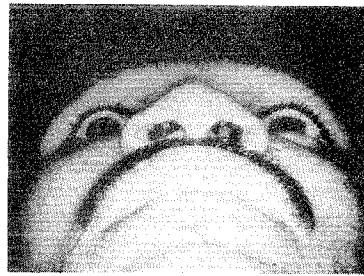
"Augmentation" was achieved either by "oversized" bone graft (Fig 1) or by "smaller sized" silastic implant (Fig 2) placed on the bare nasal bone, in a pocket just adequate to lodge it. Bone graft was harvested from iliac crest in all except one case, who had ulnar bone graft. Silastic implants were either pre-fabricated or cut out of a silastic block. Skin-grafting for mucosal contracture was necessary in one case (Fig 2). The "Tip plasty" were done by excision of fibrofatty tissue from tip of nose, re-adjustment of mobilised caudal septum, medial and lateral crurae, and scoring of cartilages at various sites. (Fig 3). Stabilisation of the reconstructed tip was done by vicryl sutures, placed as figure of eight through the septum and medial crurae. Wound closure was done, by suturing the septal and external rhinoplasty incisions with 4-O vicryl and 5-O prolene respectively in all cases.

### DRESSING

For support of septum and hemostasis, packing of whole length of both nasal cavities was done using glove fingers filled with liquid paraffin-ribbon-



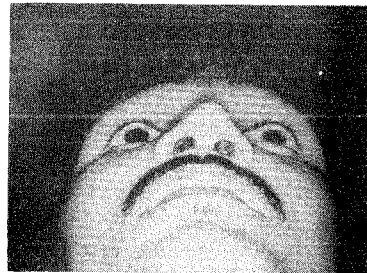Pre-operative



Pre-operative

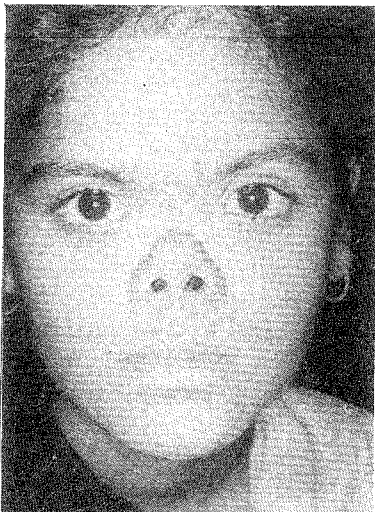

Post-operative

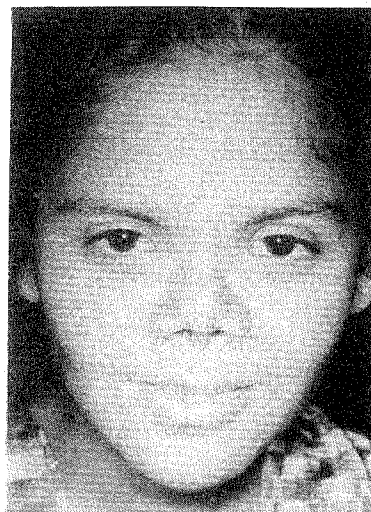


Post-operative

(Fig - 1) Augmentation Rhinoplasty using bone graft

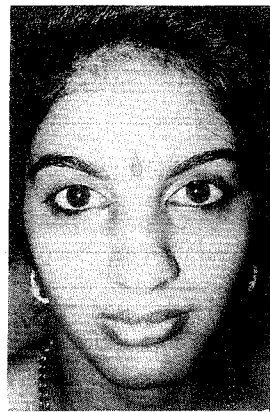

Pre-operative

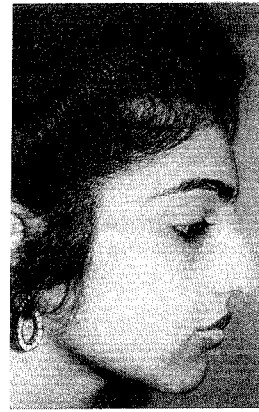

Post-operative

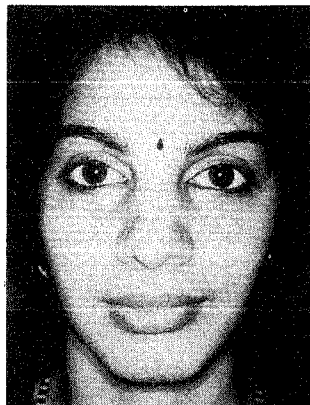(Fig - 2) Augmentation Rhinoplasty using silastic implant



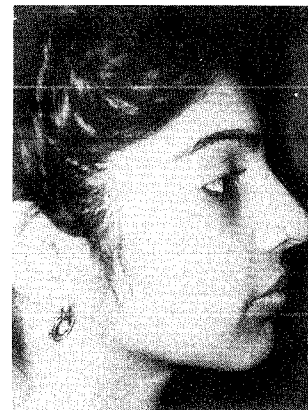Pre-operative



Pre-operative



Post-operative



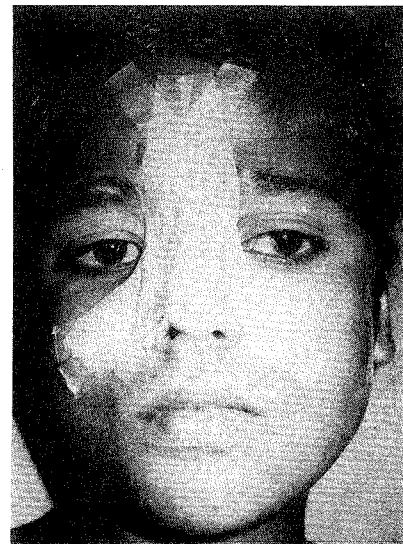
Post-operative

(Fig - 3) Tip-plasty for a drooping tip

gauze. Micropore tapes carefully put over a layer of gauze helped to maintain the new shape of nose.

### SPLINTING

"Splinting" of all noses was done by modelling (dental) wax (manufactured by the Hindustan Dental Procedures, Hyderabad, India). This material is available as 2mm thick pink sheets of 9 x 17 cms size. Single (or double) sheet was (1) cut in the shape of nose splint (like plaster splint for fracture nasal bones) with an extension on the forehead (2) dipped for half a minute in warm water to make it mouldable (3) quickly wiped of the water (4) placed directly over the micropore tape and (5) moulded to sit snugly over the packed nose. When allowed to dry up well, it stiffens in its moulded shape. Tincture Benzoin is then applied over the surface of this splint and the skin around the nose, to make it sticky. Splint is then taped in position with micropore tapes or narrow strips cut out of elastoplast (Fig 4).



(Fig - 4) Nose-splint made of modelling wax.

## POST-OPERATIVE CARE

Patients were put on antihistamine tablets, antibiotic and appropriate analgesia. The pack was removed on 4th post-operative day. In cases of deviated nose, repacking was done for another 48 hours. Retaping and splinting with dental wax was done on 4th, 7th and 10th post-operative days, shaping the nose more effectively as oedema regressed. Patients were photographed and discharged with the dental wax splint on 10th post-operative day, with advice to remove the splint after five more days. Follow up was done every two months for at least one year.

## RESULTS

All the patients attended plastic surgery out-patient department for "cosmetic" improvement of their noses. Age of the 25 patients studied, ranged from 14 to 42 years (mean 23 years). There were 12 female and 13 male patients. 22 patients were for "primary" rhinoplasty and three for "secondary" rhinoplasty with history of previous surgery done elsewhere. The etiological factors responsible for the shape of the nose at the time of the presentation are shown in Table 1. The type of rhinoplasty done is shown in Table 2. "Septoplasty" was done in 9 (36%) patients either for respiratory obstruction and/or for cosmetic reason. Eight patients had bone-grafts and seven had silastic implants for augmentation.

TABLE 1 - Causes of Nose-deformity

Etiological factors	Number of patients
Trauma	4
Previous Surgery	3
Childhood infection	1
Congenital	17
TOTAL	25

TABLE 2 - Purpose of Rhinoplasty

Type of Rhinoplasty	No. of patients	Sex	
		M	F
Augmentation	11	5	6
Reduction	3	1	2
Deviation-correction	6	5	1
Deformity-correction	3	1	2
Tip plasty	2	1	1
TOTAL	25	13	12

No necrosis or dehiscence at flap-tip of open rhinoplasty incision was seen. None of the patients had any major complication during 10 days of hospital stay. However, one patient who stopped wearing the splint after discharge had side-ward

displacement of silastic implant on 14th post-operative day which was removed immediately under local anaesthesia and redone six months later with a perfect result. There was no evidence of allergic skin reaction or any other problem related to the dental wax splint.

The results, both objective and subjective were very satisfactory with an inconspicuous scar. However 4 cases of congenital flat noses with bone-graft-augmentation showed about 30 to 60% absorption of bone-graft in two years' follow-up.

## DISCUSSION

Open rhinoplasty has been found to be a safe and reliable technique which produces predictable results<sup>2</sup>. The good result in all the 25 patients in our study is attributed mainly to a good exposure and visualisation of the pathology achieved by open-rhinoplasty method. Good surgical approach is the first and the most important step of every surgery and it is more so for a cavernous and complex structure like the nose<sup>3</sup>. The exposure of surgical anatomy of the nose is much better with external than with endonasal (closed) rhinoplasty.<sup>4</sup>

The various indications described for external rhinoplasty are severely twisted nose, secondary rhinoplasty, augmentation rhinoplasty, congenital deformities of the nose, closure of septal perforation and teaching and learning of rhinoplasty<sup>5</sup>. However, this technique should be avoided when tip-grafts are likely to be under tension or if the deformity is too minor<sup>6</sup>.

We recommend the use of the open method for both primary and secondary rhinoplasties if the skin over caudal nose is normal. The reasons to recommend this technique based on our experience are (1) it is easy to learn (2) cartilagenous nose can be sculptured under direct vision (3) nasal bones can be reached easily for management of hump (4) it results in symmetrical oedema and fibrosis and (5) septoplasty by any incision can be combined.

Septoplasty is the cornerstone of rhinoplasty. When indicated, we did septoplasty by Killian's incision<sup>7</sup> before proceeding with open rhinoplasty. In two of our patients of tip-plasty, correction of caudal septal deviation could be comfortably done through open rhinoplasty incision alone. External approach is best suited for septo-rhinoplasty even in children.<sup>8,9</sup>

Besides septoplasty, some other common procedures done on the nose earlier were mere augmentation or reduction procedures. Emphasis is now placed on repositioning and restructuring the nasal anatomy to create as natural and

functional a nose as possible<sup>2</sup>. Shaping of the nose by repositioning structures like septum, medial and lateral crurae could be easily done under direct vision exactly as per the pre-operative planning. Thus the main advantage of open approach is that it facilitates precision tailoring and great variety of tip-refinements to give consistently excellent results<sup>10</sup>. It is therefore recommended for all cases demanding excellent exposure.

The disadvantages of this technique appreciated in this study were (1) persistence of oedema approximately for 6 months. (2) need for meticulous dissection to avoid inadvertent cut to medial crurae and flap-tip necrosis and (3) risk of columellar scar.

The external approach is much criticised for the risk of columellar skin flap necrosis and visible scar formation<sup>4</sup>, which could well be prevented by proper dissection and meticulous closure. Keeping the scar in view the columellar incisions have varied from transverse, the gull wing, the "V" shaped and the step ladder incisions. Ofodile and Bokhari<sup>1</sup> had suggested placing the columellar incision at the "columella labial groove" in black patients but "mid-columellar" incision in our patients did not result in any conspicuous scar.

Relative post-operative prolongation of nasal tip swelling with open approach, as compared with closed technique is a well identified problem<sup>10</sup>. Often this makes the nasal tip appear wider after healing than intra-operatively. Splint for the nasal tip<sup>11</sup> helps to maintain the favourable intraoperative result even after healing.

All our patients had nasal tip oedema which appreciably but slowly regressed with time. Regression was helped by application of external splint. In view of the changing shape of the nose with decreasing oedema and need for prolonged usage we recommend the use of a cheap, light weight and remouldable splint in all patients of open rhinoplasty continuously for the first 2 weeks and later during night for another one or two weeks.

We found a splint made of modelling wax (commonly used by dentists) easy to cut with ordinary scissors and mould after dipping in warm water for a few seconds. Having used it for a minimum of 50 times on patients of rhinoplasty, we found this material to have many advantages. It is easily available, light in weight, easy to mould with accuracy to shape, cheap, non-allergic to skin, remouldable for repeated use and is useful for supporting ala nasi in hollow tube form.

## References

1. **Ofodile F, Bokhari FJ.** Columella incision in open rhinoplasty in Blacks. *Plast Reconstr Surg* 1992; 89:991-2
2. **Zijlker TD, Adamson PA.** Open structure rhinoplasty. *Clin Otolaryngol* 1993; 18:125-34.
3. **Senechal G, Bennouna K.** Critical study of surgical approaches in esthetic rhinoplasty. *Rev Laryngol-Otolrhinol-Board* 1991; 112(5):453-7.
4. **Vuyk HD, Olde Katter P.** Open rhinoplasty experience in 200 patients. *Rhinology* 1993; 31:175-82.
5. **Teichgraber JF, Riley WB, Russo RC.** External rhinoplasties: indications for the use. *Br J Plast Surg* 1992; 45:47-54.
6. **Ronald P. Gruber.** Open rhinoplasty. *Clinics in plastic surgery* 1988; 15:95-114.
7. **Randolph C Robinson.** Functional Septo-rhinoplasty: Atlas of oral and maxillofacial surgery 1995; 3:27-38.
8. **Crysdale Ws, Walter PJ.** External rhinoplasty in children: Patient selection and surgical technique. *J Otolaryngol* 1994; 23:28-31.
9. **Triglia JM, Cannoni M, Pech A.** Septo-rhinoplasty in children: benefits of the external approach. *J Otolaryngol* 1990; 274-8.
10. **Perlman PW, Nathan MJ.** Cosmetic rhinoplasty using the external approach. *Ear-Nose-Throat J* 1991; 70:425-30.
11. **Pedro Vega - Villasante, Covarrubias H.** A new splint for the nasal tip. *Plast Reconstr Surg* 1995; 96:189-93.

## Author

**Dr. Mita Prasanna, MS, M Ch.,**

Formerly Head of Department of Plastic Surgery, Kasturba Medical College, Manipal

Request for reprints to Dr. Mita Prasanna, M.S. M.Ch., P.Box 90, Mina Al Fahal, Postal code 116, Muscat, Sultanate of Oman.