

3 Female Cases Of Subsymphyseal Epispadias And Their Correction

Dr. Vinay Tomar, M.Ch.
Dr. Rajeev Mathur, M.Ch.
Dr. T.C. Sadasukhi, M.Ch.
Dr. S.C. Mathur, M.Ch.

KEY WORDS

Incontinence, Correction.

ABSTRACT

Successful correction of incontinence by Leadbetter's modification of young dees technique in 3 cases of subsymphyseal female episadias is reported. Simplicity and efficacy of this technique has prompted the team to undertake this procedure in all the cases.

Female epispadias is a very uncommon entity. The complete form (subsymphyseal) of female epispadias presents with characteristic external genitalia deformity such as Bifid clitoris, and widely separated labia. The widely separated pubic bones confirmed by a skiagram is an important clue to establish episadias urethra as a cause of incontinence.

A number of procedures e.g. bladder neck reconstruction, transvaginal placation of bladder neck, vesicourethral suspension, have been proposed for correction of incontinence in female epispadias.

Jeff has refined the bladder neck reconstruc-

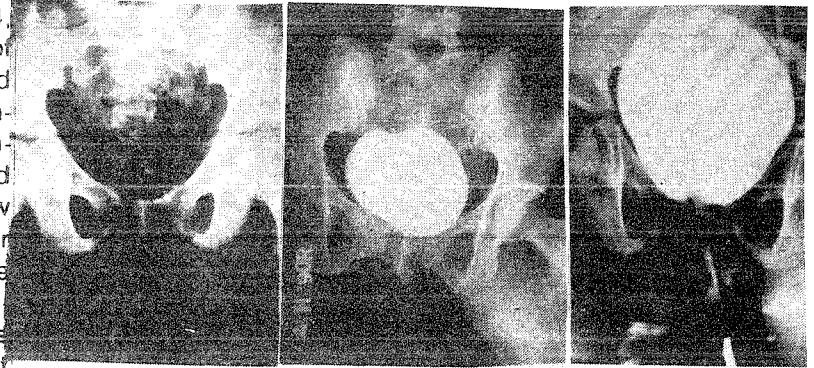
tion by including intraoperative urethral pressure profilometry and bladder neck suspension in manner of marshall, marchetti and krantz. Transvaginal placation of bladder neck and vesicourethral suspension alone also been reported with successful results by many authors.

Bladder neck reconstruction was first performed by Young in 1922 who converted funnel shaped posterior urethra into a tapered structure. In 1942, Dees modified and standardized the Young's procedure by arbitrarily defining the level for internal vesical sphincter at a point halfway between the verumontanum and intra arterial ridge. In 1964, Leadbetter further modified and advised creation of a long posterior urethral tube (3.5-5.0 cm) and thought that urethral length was responsible for continence, an idea advanced by Lapidus. He reimplanted ureters beyond trigone, narrowed and tailored the entire bladder base to form a long new urethra. He did not excise the lateral triangular wedges of bladder wall which actually decreases the bladder capacity and affects the results. Cine cystourethrography done postoperatively in all his operated cases in follow up revealed that sphincteric action at new bladder neck formed by muscles of triagone were responsible for continence than urethral length as suggested previously.

Leadbetter's modification of young Dees bladder neck reconstruction is most promising operation for urinary incontinence and feasible in either sex. In 1985, he reported a long term follow up with excellent result in 67 % and partial success in 9 % patients undergone bladder neck reconstruction for

variety of lesions. We performed Leadbetter's procedure in our 3 cases with excellent results. The complications likely to occur in this procedure are urethral obstruction or persistence of reflex, bladder neck obstruction, vesical diverticulum and wound infection. All of our cases achieved continence in immediate postoperative period without complications. IVP and voiding cystourethograms in follow up revealed well preserved renal functions and no reflux.

Photograph.



Figures :

1. Skiagram Kub - Wide Separatiion of Pubic Symphysis.
2. Post-Operative Urethrogram-Normal Urethra.
3. Pre. Op. Cystogram- Bilateral V-U. Reflux with Good Capacity of Bladder.

TABLE :

Case No.	Age (Yrs)	X-ray KUB separation of pubic bone	IVP	MCU	Procedure performed	Voiding interval during immediatepost-op. period	Complli cations.
1.	10	10 MM	Normal	Adequate capacity with bilateral V-U Reflux	Lead better's modification of young dees.	2-3 hours.	None.
2.	4	12 mm	Normal	Adequate capacity with bilateral V- U Reflux.	Lead better's modification of young dees.	1-1 1/2 hours	Secondary hemorrhage.
3.	28	9mm	Normal	Good Capa- city no V-U Reflux.	Lead better's modification of young dees but no uretero- neocystostomy.	3 hours	None.

The success in our cases is attributed to following:

- 1) Application of Leadbetter's technique in toto.
- 2) Patient's age 3 and above as recommended by Stephen.

Proximal reimplantation of ureters as advised by Leadbetter was carried out in 3rd case as there was absence of V-U reflux and proved successful.

REFERENCES :

1. **Young, H.H.** : An operation for the cure of incontinence associated with episadias. *J. Urol.* 1922, 7: 1-32.
2. **Dees, J.E.** : Epispadias with incontinence in male. *Surg.* 1942, 12 : 621-629.
3. **Leadbetter, G.R. Jr.** : Surgical correction of total urinary incontinence. *J. Urol.* 1964, 91 : 261-266.
4. **Wendl, R.M. & King, L.R.** : The treatment of total urinary incontinence. *J. Pediatr. Surg.* 1970, 5 : 543.
5. **Stanley, K.E. Jr., Symonds, R.E. & Green, L.F.** : Partial epispadias in a girl. *J. Urol.* 1963, 89 : 439-441.
6. **Lopez, Engel King, R. & Allain, T.P.** : Female epispadias treatment of incontinence by Marshall-Marchetti technique. *J. Urol.* 1960, 84 : 555-558.
7. **Freedam, H.K.** : Scholesinger, H.L. & Randall, G.E. : Two cases of subsymphyseal epispadias in female patient with surgical correction. *J. Urol.* 1967, 97 : 490-91.
8. **Dees, J.E.** : Congenital epispadias associated with incontinence. *J. Urol.* 1942, 62 : 513-522.
9. **Edward, C. Muceke & Victor F. Marshall** : Subsymphyseal epispadias in female patient. *J. Urol.* 1968, 99 : 622-628.
10. **Stephena, Kramer & Panayotis, P. Kelalis** : Assessment of urinary incontinence in epispadias : Review of 94 patients. *J. Urol.* 1982, 128 : 290-293.
11. **Lapides, J.** : Structure and function of internal vesical sphincter. *J. Urol.* 1958, 80 : 341 - 353.
12. **Lapides, J., Ajemian, E.P., Steward, B.W., Breakey, B.A. & Lichtwardt, J.R.** : Further observation on the kinetics of Urethrovesical sphincter. *J. Urol.* 1960, 84 : 86-94.
13. **Lead better, G.W. Jr. & Fraky, E.E.** : Surgical correction for total urinary incontinence 5 years after. *J. Urol.* 1967, 97 : 869-873.
14. **Jeffs, R.D.** : Exstrophy. In compbell's Urology, 4th Ed., Edited by J.H. Harrison, R.F. Gittes, A.D. Perlmutter, T.A. Stamey & P.C. Walsh, Philadelphia. W.B. Saunders Co. Vol. 2., Chapter 49, 1979, 49 : 1672-1696.
15. **Leadbetter, G.W. Jr.** : Surgical reconstruction for complete urinary incontinence. A 10-22 years follow up. *J. Urol.* 1985, 133 : 205.

AUTHOR'S NAME AND ADDRESS :

1. Dr. Vinay Tomar, M.Ch. (G.U. Surg.) Assistant Professor.
2. Dr. Rajeev Mathur, M.Ch. (G.U. Surg.) Assistant Professor.
3. Dr. T.C. Sadasukhi, M.Ch. (G.U. Surg.), Associate Professor.
4. Dr. S.C. Mathur, M.Ch. (G.U. Surg.), Professor & Head.

S.M.S. Medical College, Jaipur.