

Inferiorly Based Fasciocutaneous Flaps In Leg - Our Experience.

**Dr. Subrat Kumar Jena, M.S. (Orth),
M.Ch. (Plast.), FICS**

Dr. Falguni Ray, M.S., M.Ch. (Plastic)

**Dr. (Mrs.) Bijaylakhmi Nayak,
M.S., M.S. (Plastic)**

Dr. Binay Kumar Das, M.S., M.S. (Plastic)

KEY WORDS

Flaps, Venous Drainage, Perforators.

SUMMARY

Inferiorly based fasciocutaneous flaps have emerged as an ideal material for the defects in lower leg and foot. We have used this flap in eleven patients since 1986 through 1989. The flaps have proved to be reliable over difficult areas of ankle and foot, either multistaged distant flaps or free flaps are the other alternative. Here inferiorly based fasciocutaneous flaps offer a much simpler and safer answer.

INTRODUCTION

In spite of the bright prospects for free flaps in the management of defects in lower leg and foot, these have not gained universal popularity. Running on the same track, fasciocutaneous flaps have achieved greater appeal within a short history of less than a decade. Since the description of Ponten in 1981 the fasciocutaneous flaps have made tremendous strides in both clinical and experimental studies. The potentials of the flaps is evident by the demonstration of satisfactory perfusion pressures in the perforators situated as low as 4 cms. from the medial malleolus (Amarante et al, 1986). Septal perforating vessels have been demonstrated from peroneal artery. (Donski and Fogdestan in 1983) and from posterior tibial artery. This information has helped workers in designing large inferiorly based fasciocutaneous flaps from all around the leg, except the bony antero-medial aspect. Flaps have survived great lengths, reaching difficult areas in

lower leg, ankle, dorsum as well as plantar aspect of foot.

We have used 11 inferiorly based fasciocutaneous flaps and have achieved very satisfactory results. They are highly versatile and do not require sophisticated equipment or special training.

MATERIAL AND METHOD

We had 11 cases of lower leg and foot defects resulting from various causes like, road traffic accidents (3 cases), burns (2 cases), non-healing ulcers with fungal infection (2 cases), skin malignancy (2 cases) and post-operative scarring with contractures (2 cases). Age of the patients ranged from 8 to 52 years.

Pre-operative planning included localisation of the fasciocutaneous perforators on the skin surface by a Doppler probe. We have used a standard pocket Doppler of Indian make for this purpose. The pedicle was designed so as to include atleast two large perforators. The length of the flap has been widely variable (Table). The longest flap measured 24 cms. in a young boy extending from the supra-malleolar area to just below the popliteal crease. The anterior tibial flap, which is also included in this series (Type 'C' fasciocutaneous flap of Cormack and Lamberty, 1984) had a dissected vascular pedicle of 23 cms. in one and 19 cms in another patient.

FLAP ELEVATION :

The procedure used is described separately for anterior tibial flap and other fasciocutaneous flaps of leg. For both the procedures a bloodless field is essential. The flap is accurately traced and the sites of perforators marked with skin pencil before the tourniquet is inflated, (Figure 1 a,b,c).

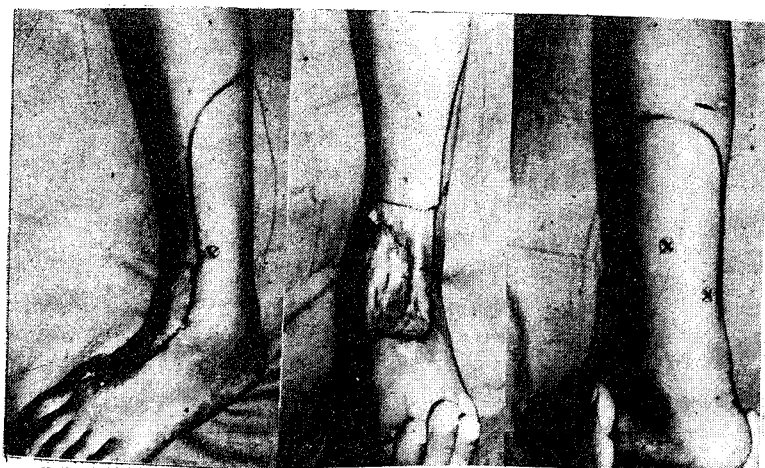

Fig. -1 :

- Inferiorly Based Fasciocutaneous Flap**
 a) X Shows Sites of Perforators
 b) Defect
 c) Marking for the Same

For raising the anterior tibial flap, the artery is first exposed in the cleft between the Tibialis anterior and the toe extensors at a level roughly around the pivot point. The skin of the leg is then incised along the course of the anterior tibial artery upto the lower border of the flap. While dissecting the vascular bundle care is taken not to skeletonise the vessels and to keep as much soft tissue around the pedicle as possible. We did not feel the necessity of dissecting a silver of Tibialis anterior (as advised by Wee, 1986) along the whole length of the pedicle. However, a thin width of Tibialis anterior muscle and extensor, digitorum longus muscle on either side of the vessels lying just underneath the skin paddle are Carefully retracted, against inadvertant damage to the septal vessels passing through the thin and flimsy septum. The vascular bundle proximal to the flap is clamped and the tourniquet released. Haemostasis is achieved by electro-coagulation.

Pulsation returns in the anterior tibial artery within a short while with engorgement of the venae committantes while the clamp is still in position. The vascular bundle is then ligated on either side of the clamp and then the clamp is removed dividing the bundle between the ligatures. While transferring the skin paddle down, the pedicle is placed in a comfortable situation avoiding sharp bony prominences. The skin bridge between the pivot point and the defect is opened up to allow the pedicle to be laid down in this predetermined position. The donor defect is skin-grafted and the skin incisions closed (Figure -2, a,b). The limb is then immobilised in a Plaster of Paris posterior slab.

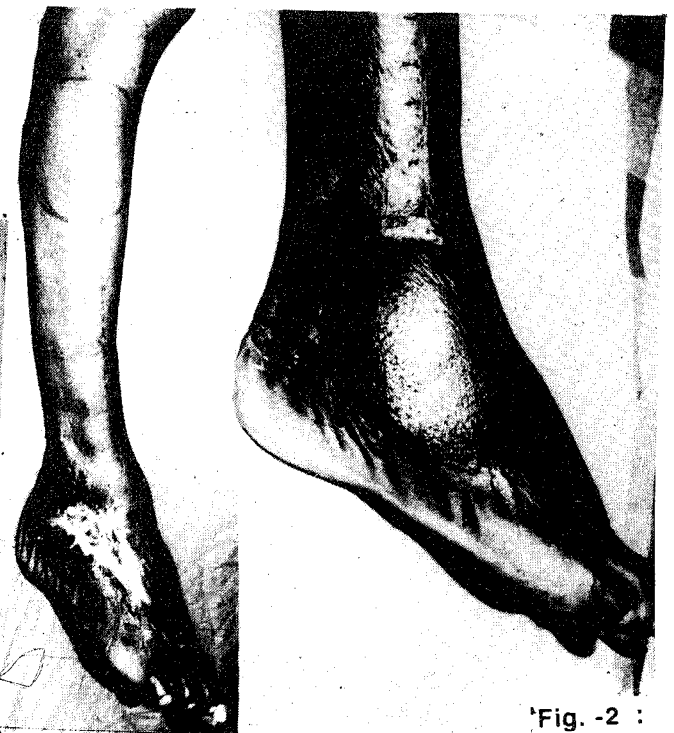

Fig. -2 :

- Anterior Tibial Fasciocutaneous Flap**
 a) The Defects. Markings for Anterior Tibial Artery and the Paddle Planned.
 b) Final Results,

For the fasciocutaneous flaps in other locations elevation is simple sub-fascial dissection starting from the proximal edge of the flap. The width of the pedicle is decided by the minimum distance between the host perforators. No attempt is made to settle the 'Dog ears' by dissecting the flap further down beyond the site of these perforators. As evident from the results these 'Dog-ears' never pose any serious concern either to the patient or to surgeon.

RESULTS :

There was one instance of flap failure (Table). The failure was most probably due to a tight loop of bandage. Marginal superficial necrosis of skin occurred over distal one cm in a child aged 10 yrs. The healing was uneventful in the rest of our patients (Figure 3 a,b,c and Figure 4 a,b). We give Lomodox in Dextrose intravenously at the rate of 3 units per day for 2 to 3 days post-operatively in most of the cases.

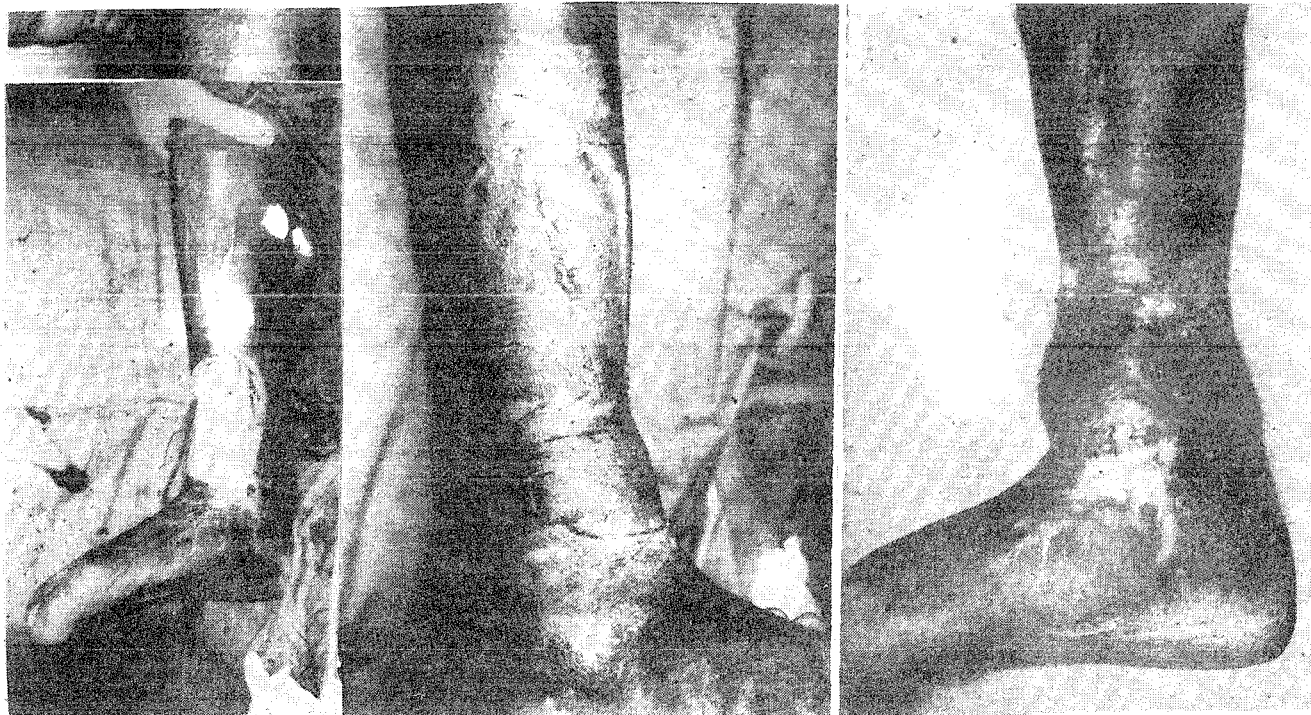


Fig. -3 :

Fasciocutaneous Flap
 a) Defect
 b) Flap After in set
 c) Final Result

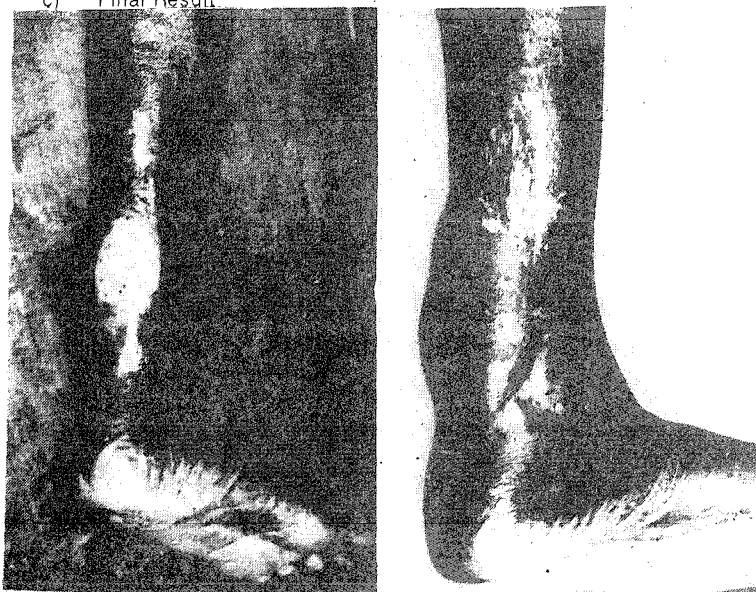


Fig. - 4 :

Peroneal Fasciocutaneous Flap
 a) Flap After Transfer.
 b) Defect

Inferiorly based fasciocutaneous flaps
TABLE - I
 (Summary of observations)

Type of flap	No. of cases	Age of Pt. years	Dimensions Cms.	Complications
Ant Tibial Art flap, Island	2	52	11 x 8	Nil
		48	10 x 9	Nil
Lateral leg	3	10	15 x 6	Sup necrosis
		50	15 x 8	Nil
		45	13x 8	Nil
Medical leg	2	30	17 x 7	Nil
		8	12 x 7	Nil
Posterior leg	4	35	23 x 7	Necrosed
		18	26 x 7	Nil
		40	18 x 6	Nil
		37	17 x 8	Nil

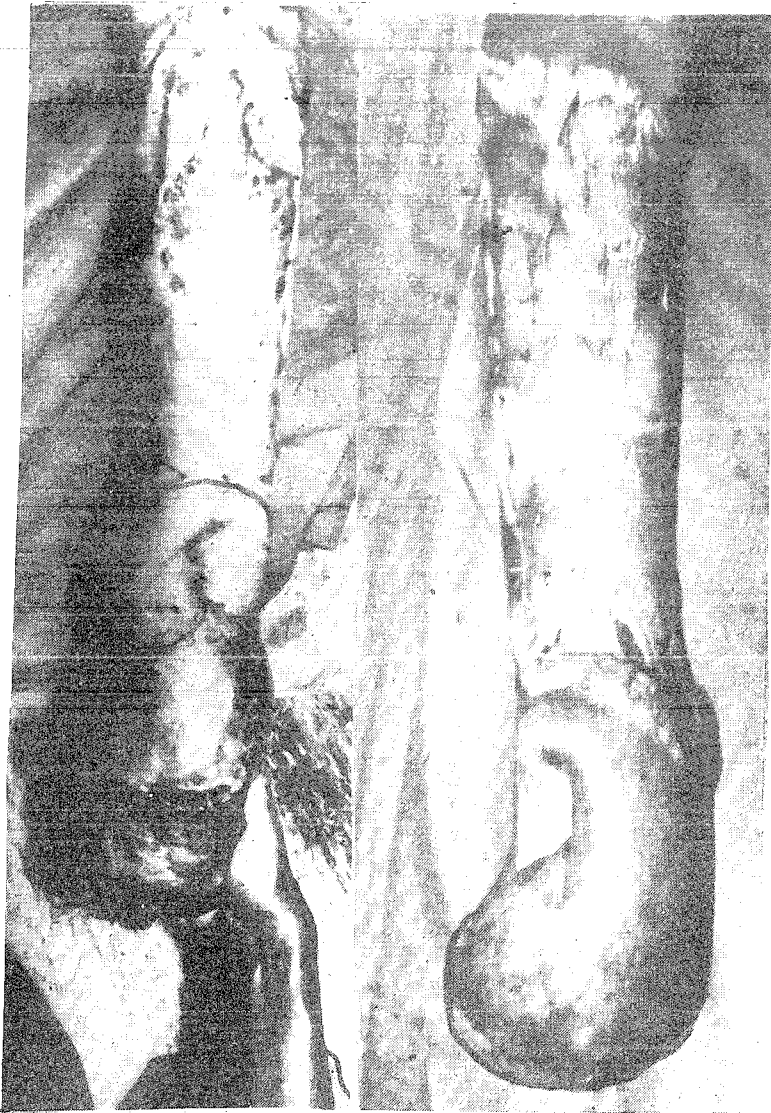


Fig. - 5 :

Inferiorly Based Fasciocutaneous Flap
(a,b) - Flap After Transfer to Defects.

DISCUSSION :

Use of distally based fasciocutaneous flaps, both island and peninsular, is not new. In 1983 Donski and Fogdestam described a distally based fasciocutaneous flap from the sural region. This flap was based on the perforating branches of the peroneal artery which were located precisely at the posterior border of the lateral compartment of the lower third of leg. Amarante et al (1986) described perforators from the posterior tibial artery as low as 4 and 6.5 cm from the medial malleolus. Similarly, distally pedicled peroneal artery has been used to carry an island of skin to reconstruct a heel defect. (Yoshimura et al., 1984). Landra (1984) has pedicled the posterior tibial artery distally, bringing the soleus

muscle to cover defects in the lower leg. Wee in 1986 used distally based anterior tibial artery flap in lower leg and foot.

The arterial supply to the inferiorly based flaps is attributable to two facts: (a) retrograde flow through the anastomosis between the major vessels (axial vessels of the limb) and (b) disposition of dominant perforators in the retrograde manner (Taylor et al., 1990). Since the perforators are connected by a net work of arteries and corresponding veins, it seems evident that two adjacent prominent perforators isolated clinically with precision can represent the axis of a viable flap of various dimensions. Use of Doppler probe is valuable in the process. By correlating the dye injection and Doppler study Taylor et al. (1990) have also shown that a loud perforator indicated a vessel size of 0.5 mm or larger.

The venous drainage of the flaps has also been explained by two propositions; (a) avalvular channels called the 'oscillating veins' connecting the venous perforators accompanying the perforating arteries and (b) incompetence of the valves because of denervation or distention of the veins.

The fasciocutaneous flaps based on large axial vessels, e.g., the anterior tibial artery, have an added advantage of providing extensively long pedicles for transfer of these flaps, the principle blood supply to the skin remaining the same.

CONCLUSION :

It is significant that in the recent years a large number of flaps based distally in the limbs are appearing in literature. It has emerged from labourious and extensive cadaveric dissections as well as Doppler studies that they are quite sound and reliable. The use of Doppler probe in planning these flaps can hardly be over emphasized. It is relatively inexpensive, simple and a quick method of defining the dimensions of the vessels, perforating or axial, without any false positives. This, however, does not mean that a sound knowledge of anatomy can be dispensed with. To achieve success in these flaps and in order to design newer flaps that seem to challenge the conventional guidelines, the only clue is to dive deep and know more and more about the blood supply of SKIN.

REFERENCES :

1. **Amarante, J., Costa, H., Reis, J. and Soares, R.** : A new distally based fasciocutaneous flap of the leg. *British Journal of Plastic Surgery*. 1986; 39: 338-340.
2. **Barclay, T.L., Cardoso, E., Sharpe, D.T. and Croket, D.J.** : Repair of lower leg injuries with fasciocutaneous flaps. *British Journal of Plastic Surgery*. 1982; 35: 127.
3. **Cormack, G.C. and Lamberty, B.G.H.** : A classification of fasciocutaneous flaps according to their pattern of vascularisation. *British Journal of Plastic Surgery*. 1984; 37: 80.
4. **Donski, P.K. and Fogdestam, I.** : Distally based fasciocutaneous flap from the sural region. *Scandinavian Journal of Plastic and Reconstructive Surgery*; 1983; 17:191.
5. **Lin, S.D., Lai, C.S. and Chiu, C.C.** : Venous drainage of reverse forearm flap. *Plastic and Reconstructive Surgery* 1984; 74: 508.
6. **Ponten, B.**: The fasciocutaneous Flaps: its use in soft tissue defects of the lower leg. *British Journal of Plastic Surgery*, 1981; 34: 215.
7. **Trimmons, M.J.** : William Harvey revisited : Reverse flow through the valves of the fore arm veins. *Lancet*. 1984;2 : 394.
8. **Wee, J.T.K.** : Reconstruction of the lower leg and foot with the reverse pedicled anterior tibial flap : preliminary report of a new fasciocutaneous flap. *British Journal of Plastic Surgery*. 1986; 39:327.
9. **Yoshimura, M., Imura, S., Shimamura, K., Yamauchi, S. and Nomura, S.** : *Peroneal flap for the reconstruction in the extremity*. *Plastic and Reconstructive Surgery*. 1984; 74:402.

AUTHOR'S NAME AND ADDRESS :

1. Dr. Subrat Kumar Jena, M.S. (Orth), M.Ch. (Plast.), FICS, Lecturer
2. Dr. Falguni Ray, M.S., M.Ch. (Plastic), Assistant Professor
3. Dr. (Mrs.) Bijaylakhmi Nayak, M.S., M.S. (Plastic), Associate Prof.
4. Dr. Binay Kumar Das, M.S., M.S. (Plastic), Professor

Dept. of plastic Surgery,
S.C.B. Medical College,
Cuttack.