

A New Technique To Enhance Levator Power In Congenital Ptosis

Dr. Mrinmay Nandi, M.S., M.Ch.

The above work has been presented in Peet Prize Session (1992), BOMBAY.

KEY WORD

Reanimation, Tendon muscle graft.

ABSTRACT

Severe degree of congenital Ptosis, not correctable by resection of levator alone poses a formidable challenge. Results with classical technique of brow suspension with frontalis sling, leaves much to be desired. Improved version of this technique is tried on seven patients and appears to be superior.

INTRODUCTION

In congenital ptosis, atrophy of levator is observed. Histologically there is loss of crossed striation, random decrease of muscle fibre diameter, sarcolemel retraction, nuclear malalignment, fibrous and fatty displacement of striated fibres. Isaksson (1962) and Hornolass (1976) have shown that there is defect in the quality and quantity of the striated fibres of the levator muscles. Muscle contraction is inadequate and it cannot relax properly. Therefore, it neither can elevate nor shut the palpebral fissure adequately. The result is a Ptosis and a lid lag on looking downwards. Whenever it is possible, procedures like levator resection, split level eyelid resection, split level eyelid resection with levator hitch are the operations of choice. The movement of the eyelid is more physiological follow-

ing these operations. When the levator contracts, not only is the eyelid elevated and allows light to enter but it contracts from before backwards maintaining an even contact with the eye ball. There is symmetry of the eyelids in motion. Brow suspension with frontalis sling has the disadvantage of under-correction and over correction and is less physiological. The upper eyelid moves vertically upwards due to the pull of frontalis and the eyelid tends to move away from the eyeball. There is asymmetry of the two lids in motion in unilateral cases because two different muscles act on two different eyes and in two different direction.

This results often in lid lag, lagophthalmos and keratitis. Hence increasing the power of levator muscle in severe cases with poor levator action, should give superior results to that of frontalis sling method. With this in mind this study is undertaken.

MATERIAL AND METHODS

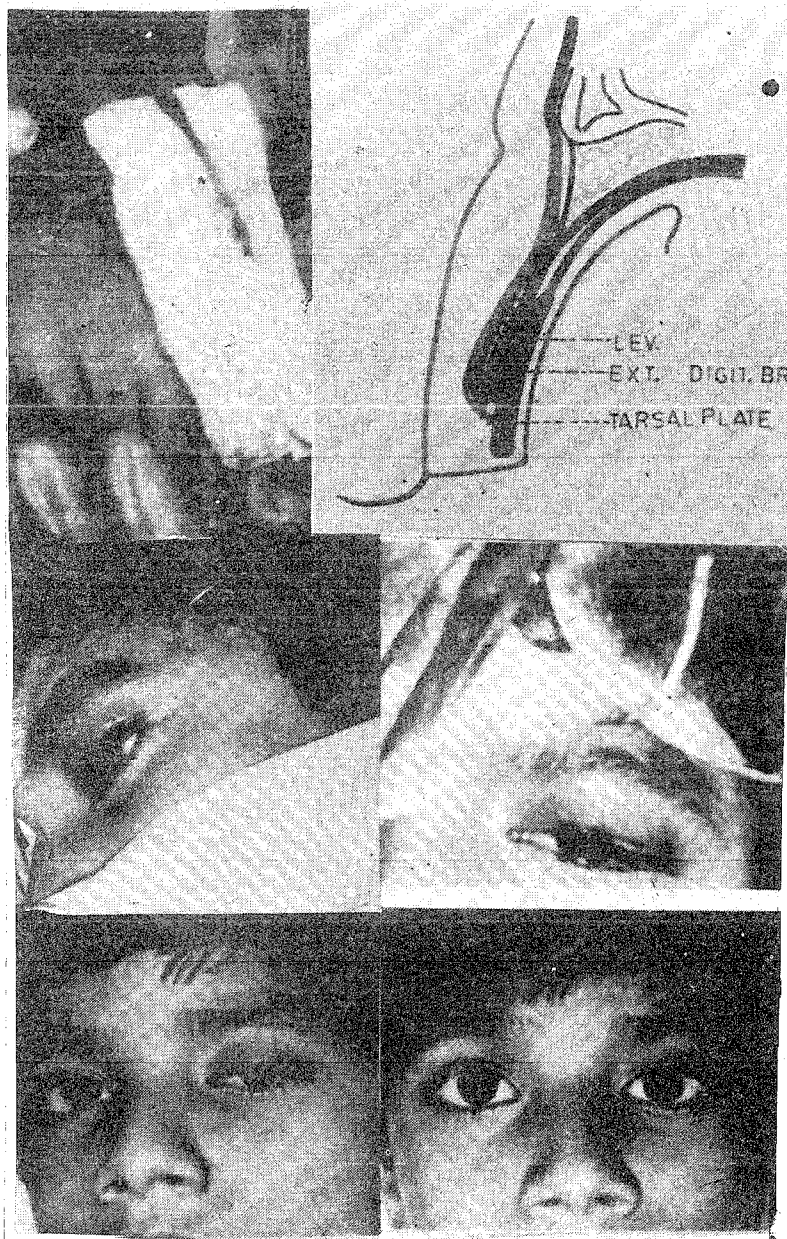
Seven patients were operated upon in the last three years by this method. Four of them were children below twelve while the rest were adults.

All of them had unilateral severe degree of ptosis with very poor levator function. Two of them were failed cases following levator resection. Brow suspension with frontalis sling was indicated in all according to present convention. E.M.G. was done in grown up patients.

OPERATION

The extensor digitorum bravis muscle was denervated after dissecting out the neurovascular pedicle near its base. After two weeks of this procedure one of the muscle belly along with its tendon was taken out. The muscle portion was gently spread out into a triangular shape conforming with levator muscle. It was then placed over the levator and through a tunnel the tendon was brought out in the forehead in the centre. The lower border of the muscle was then fixed to the tarsal plate and the muscle was fixed to levator all along its length and breadth. A loop was then made in the frontalis muscle and through it the tendon was brought out in the temporal region. Eyelid was then raised to the desired position by pulling the tendon and after final adjustment, tendon was fixed to the periosteum.

Photograph 1-6



Figures :

1. Showing Denervated Extensor Digitorum Bravis Muscle with Tendon.
2. Placement of Ext. Dig. Br. Over levator.
3. Tension Adjustment Before Fixing with periosteum.
4. Tendon in Forehead
5. Pre-Operative
6. After one year (Post-Operative)

RESULTS :

Improvement of the levator action was noticed in all the cases (table - 1) within a month when the oedema subsided, and this improvement went on for a period of one year.

E.M.G. studies which could be performed in the grown ups showed marked increase in the power of levator muscle, compared with the preoperative findings.

TABLE I

Sr. No.	Age	Date of Operation	Levator Function Pre Op.	Levator Function Sept' 92	Lid lag Post Operative	Lagophthalmos	Lid Bulk	EMG
1.	9 yrs	Jan. '90	2 mm	8 mm	Nil	Nil	Satisfactory	Not done
2.	10 Yrs.	April '90	3 mm	9 mm	Nil	Nil	"	Not done.
3.	18 Yrs.	Dec. '90	1 mm	7 mm	Mild	Nil	"	Marked
4.	15 Yrs.	Mar.'91	1mm	8 mm	Mild	Nil	"	Marked
5.	11 Yrs.	May '91	2 mm	6 mm	Nil	Nil	"	Not done.
6.	10 Yrs.	May '91	2mm	7 mm	Mild	Nil	"	Not done.
7.	21 Yrs.	June '91	Nil	6 mm	Mild	Nil	"	Marked

DISCUSSION

Idea behind this procedure is to let the muscle get animated and regain the tone. This reinforcement of levator muscle by additional denervated muscle mass is expected to elevate the lid further up.

CONCLUSION

Some amount of asymmetry does persist when the two eyes are compared. Procedure is expected to become popular in spite of this shortcoming, since it reinforces the natural levator function.

REFERENCES

1. Beard, C. 1981 Ptosis, 3rd edn. The C.V. Mosby co. St Louis 2.
2. Berke R.N., Wadsworth J.A.C. 1955 Histology of levator muscle in congenital and acquired ptosis. Archives of Ophthalmology 53:413.
3. Berke, R.N., 1959 Results of reaction of the levator muscle through skin incision in congenital ptosis. Archives of Ophthalmology 61:177.
4. Crawford, J.S. 1956 Repair of ptosis using frontalis muscle and falcis lata. Transactions of the American Academy Ophthalmology and Otolaryngology 60:672.
5. Hornblass A., Adachi M., Wohint, A., Smith, B. 1976 Clinical and ultrastructural correlation in congenial in congenial and acquired ptosis. Ophthalmic Surgery 7 : 69.
6. Isaksson, I. 1962 Studies on congenial genuine blepharoptosis. Acta Ophthalmologic 72, (Suppl).
7. Mustarde, J.C., 1975 Problems and possibilities in ptosis surgery. Plastic and Reconstructive Surgery, October, pp 381 - 388.
8. Mustarde, J.C., 1979. Split level lid resection. Plastic Surgery in infancy and childhood, 2nd Edn. pp 238 - 240.
9. Mustarde, J.C., 1980 The role of Muller's muscle in ptosis surgery In: Ely, J.F. (ed) Transaction of the Seventh International Congress of Plastic and Reconstructive Surgery. Sao Paulo. Sociedade Brasileira de Cirugia Plastica.
10. Sutula F C 1988 Histological changes in congenital and acquired ptosis. Eye. 2.2. 179-184.

AUTHOR'S NAME AND ADDRESS :

Dr. Mrinmay Nandi, M.S., M.Ch., Lecturer,

Department of Plastic Surgery, Calcutta Medical College, CALCUTTA.