

Caudal Duplication Of Hind Gut And Lower Genitourinary Tract In A Female Child.

**Dr. V.N.S. Yadava, M.S., M.S.,
(Plastic Surgery)**

**Dr. Jina, Raghendra Prasad, M.S.
(Gen. Surg.)**

**Dr. Kushwaha Komal Prasad, M.D.
(Paediatrics)**

KEY WORDS

Hind gut, Lower G.U. Tract, Duplication.

ABSTRACT

Two year old, with congenital anomaly of duplication of hind gut upto sigmoid flexor with one open end and other closed, as well as double bladder and double urethra opening below two clitoris and two vaginal vaults is presented.

INTRODUCTION

Such anomalies are quite rare. Revitch and Scott (1953) reviewed the literature and brought out such 20 cases, including his own cases, in which there was complete or partial duplication of the hind guts and that of lower genitourinary tract. Nesbit and Bromme (1933) were the first to report two separate urinary bladders in an intravenous polygraph. Out of 20 cases of Ravitch and Scott, 12 had duplication of the bladder, and six had duplication of the bladder as well as external genitalia. Marshall and Muecke (1968) reported 18 cases of such abnormality in which 9 had the duplication of lower gastrointestinal tract, in 6 it was right upto the ileocacal valve.

Approximately two hundred cases of urethral duplication are recorded in literature Hoekstra and Jones (1985).

The abnormalities of internal genitalia are well known in the form of septate uterus, cervix and upper vagina. However, duplication of external genitals is not so frequent.

CASE HISTORY

Parents noticed a gross abnormality at birth in perineal region. There were two separate openings, on the right and the left of midline in the perineal region, discharging urine from both sides and discharging faeces from the left side alone. Close examination revealed abnormally wide perineum. The 2 1/2 year old female child revealed the following, other abnormalities.

Right sided opening presented with one well developed clitoris, a urethral opening and below a vaginal vault.

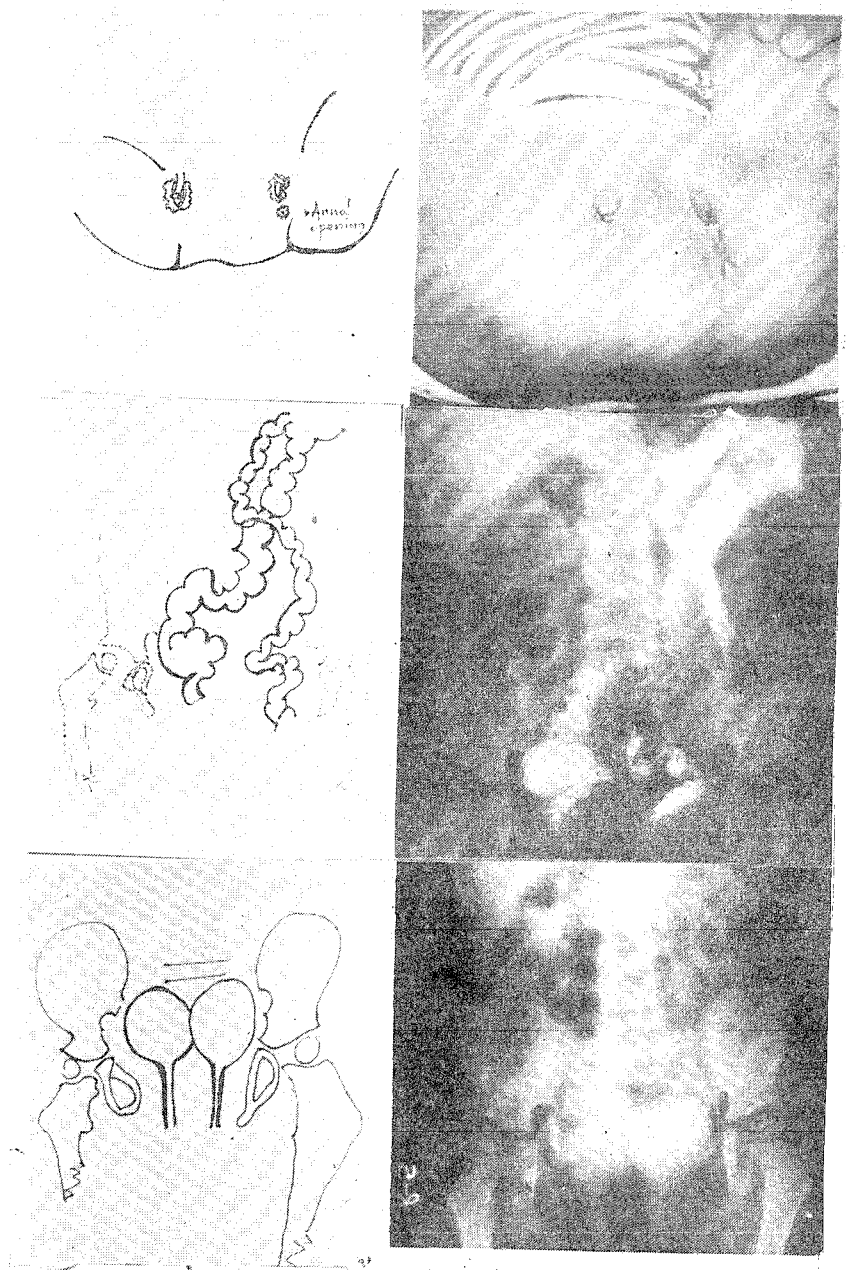
On the left side in addition to above there was an opening through which she was passing faeces normally.

INVESTIGATIONS

Barium enema revealed passage of barium upto sigmoid flexor and from there having entered the right duplicated hind gut reached the imperforate anus on the right side.

Intravenous pyelogram revealed two separate bladders and two separate urethral tracts. It also revealed widely separated pubic bones and non union of symphysis pubis.

Photographs (1-6)



Figures :

1. (a,b) - External Genitalia with Normal Left Anus and Imperforate Anus on Rt. and Perineal Fullness.
2. (a,b) - Passage of Barium Through Left Anus, Sigmoid NN Flexor and Duplicated Rt. Hind Gut.
3. (a,b) - Intravenous Pyelogram, Two Bladders and Draining Urethra on Each Side.

DISCUSSION :

Congenital caudal twinning of the hind gut and lower genitourinary complex are quite rare. Early reports of such anomaly were based on autopsy findings, indicating high mortality of such infants and children. 18 cases of Ravitch and Scott were reported, operated, and others had died in infancy mainly following intestinal obstruction, which is a major cause of fatality.

Segmental duplication of gut can be at any level from esophagus to anal canal. Large bowel duplication with separate lumen is however, rare. Existing reports of such cases are in the form of enterocystoma or enteric cyst, forming a blind loop and other one communicating with the opening. Excision or anastomosis to the healthy loop is the operative treatment normally practiced in such cases. Aitkan (1950) reported a new born infant who had complete duplication with separate lumen starting from terminal ileum, entire colon, rectum and anal canal along with exomphalos. LeouDiaz (1951) has reported existence of three parallel colons in one case. Burns, Cummins and Hyman (1947) reviewed the literature and classified the duplication of urinary bladder as two separate bladders or one separated by a frontal or sagittal septa, in two bladders or in an incomplete division, where septa are deficient.

Literature search revealed twelve cases of genital or genitovesical duplication with duplication of hind gut. 200 cases of urethral duplication in complete or abortive form associated with epispadias or hypospadias or without either are also reported. Abnormalities of the upper genitalia are common where there are bicornuate uterus or one separated by complete or incomplete sagittal septa. In one case alone there has been duplication of the lower vaginal outlet.

Twinning of the lower urogenital sinus is extremely rare. On the basis of Embryological studies two hypothesis explain such duplications.

- i) Ravitch and Scott (1953) suggests it is due to the twinning of the tail portion of the embryo.

- ii) Keibel 1896, Watson 1920 suggests it is due to a super numerary urorectal septa, sagittally oriented, responsible for dividing bladder and the hind gut.

REFERENCES :

1. Hoekstra, S and Jones, B. : Duplication of male urethra report of three cases. clinical radiology 1985, Vol. 36, 529-531.
2. Muecke, E.C., Duplication of Bladder, Campbells Urology, Patrick C. Walsh, Rubben E. Guttes, A.D. Perlmatter, Thomas. A. Stameg, 5th Edition 1986, published by W.B. Saunders Co. Philadelphia Vol. II, Page 1877 - 1878.
3. Nesbit, R.M. and Bromme, W., Double penis in Double Bladder with report of case. Amer. J. Roentgenol 1933, 30 : 497.
4. Ravitch M.M., and Scott W.W., Duplication of entire colon, Bladder and Urethra. Surgery 34 : 843 - 1953.

AUTHOR'S NAME AND ADDRESS :

1. Dr. Yadava. Vishwanath Sahai,
M.S. (Gen. Surg.) M.S. (Plastic Surg.)
2. Dr. Jina. Raghendra Prasad,
M.S. (Gen. Surg.)
Assoc. Professor, Deptt. of Surgery.
3. Dr. Kushwha. Komal Prasad,
M.D. (Paediatrics)
Asst. Professor, Deptt. of Paediatrics.

Department of Surgery, B.R. D.
Medical College,
Gorakhpur - 273 013 (U.P.) INDIA.