



# Utility of Clinical and Radiological Markers in Diagnosing Cerebral Tuberculoma and Neurocysticercosis

Chandrakanta Patra<sup>1</sup> Shabeer Ahmad Paul<sup>2</sup> Gouranga Prosad Mondal<sup>1</sup> Ramesh Bhattacharyya<sup>1</sup>  
Kartik Chandra Ghosh<sup>1</sup>

<sup>1</sup> Department of Neurology, Calcutta National Medical College & Hospital, Kolkata, West Bengal, India

<sup>2</sup> Department of Neurology, Govt Superspeciality Hospital Shireen Bagh, Srinagar, Jammu and Kashmir, India

**Address for correspondence** Shabeer Ahmad Paul, DM Neurology, Department of Neurosciences, Paras Hospital, Srinagar, Jammu and Kashmir, India (e-mail: paulshabir55@gmail.com).

Indian J Neurosurg

## Abstract

**Background** Ring-enhancing lesion is one of the most common radiological findings in a spectrum of diseases affecting the central nervous system (CNS) including infectious, inflammatory, demyelinating, and neoplastic pathologies.

**Objective** The aim of this study was to analyze the clinical and radiological parameters of pathologies presenting as ring-enhancing lesions in the brain, especially tuberculoma and neurocysticercosis.

**Materials and Methods** In this study, 58 patients with ring-enhancing lesions on brain magnetic resonance imaging (MRI) were recruited. Cases were studied for different clinical and radiological variables. Data were analyzed using SPSS 20 version.

**Results** Tuberculoma is the most common pathology accounting for ring-enhancing lesions in the brain, followed by neurocysticercosis. Seizures were present in the majority of cases, with focal onset seizures being more common than generalized seizures. Multiple ring-enhancing lesions were present in the majority of cases, with the cerebral cortex being the most frequently involved site. On T2 fluid-attenuated inversion recovery (FLAIR) sequence, 2/3rds of the neurocysticercosis cases showed full suppression, whereas only 1/10th of tuberculoma cases showed full suppression. On diffusion-weighted imaging (DWI), a minority of neurocysticercosis cases showed diffusion restriction, while more than one-fifth of tuberculoma cases showed diffusion restriction. MR spectroscopy (MRS) results showed that a normal lipid lactate peak was observed in the majority of neurocysticercosis cases, whereas more than half of tuberculoma cases had a high lipid lactate peak. The choline-to-creatine ratio (Chol/Cre ratio) was less than 1.2 in one-third of neurocysticercosis cases and between 1.2 and 2.0 in two-thirds of the cases. In contrast, more than half of tuberculoma cases showed a Chol/Cre ratio between 1.2 and 2.0.

**Conclusion** Tuberculoma and NCC are the two most common causes of ring-enhancing lesions in developing world. Radiological characteristics like FLAIR

## Keywords

- ▶ ring-enhancing lesions
- ▶ tuberculoma
- ▶ neurocysticercosis

DOI <https://doi.org/10.1055/s-0043-1774815>.  
ISSN 2277-954X.

© 2023. The Author(s).

This is an open access article published by Thieme under the terms of the Creative Commons Attribution License, permitting unrestricted use, distribution, and reproduction so long as the original work is properly cited. (<https://creativecommons.org/licenses/by/4.0/>)

Thieme Medical and Scientific Publishers Pvt. Ltd., A-12, 2nd Floor, Sector 2, Noida-201301 UP, India

suppression and diffusion restriction on MRI and Chol/Cre ratio and lipid peak on MRS can substantiate the clinical parameters in distinguishing the two pathologies to a good extent.

## Introduction

A wide spectrum of diseases affecting the brain present as ring-enhancing lesions (RELs) on imaging. These disorders include infectious, inflammatory, vascular, and neoplastic pathologies. Distinguishing non-neoplastic causes from neoplastic lesions is extremely important because a misdiagnosis can lead to unwarranted neurosurgery and exposure to toxic chemotherapy or potentially harmful brain irradiation.<sup>1</sup>

Establishing the etiological diagnosis is difficult in many circumstances. Diagnostic techniques, such as diffusion-weighted magnetic resonance imaging (MRI), perfusion-weighted MRI, magnetic resonance spectroscopy (MRS), single-photon emission tomography, and positron emission tomography may help in establishing the etiology, but brain biopsy is often warranted to establish the definitive diagnosis.

Similarly, on MRI these lesions appear as hypo-, iso-, or hyperintense on different sequences with ring enhancement seen on T1 MRI sequences with contrast. The lesions tend to be of variable size and are usually surrounded by certain amount of vasogenic edema. Typically, the RELs are located at the junction of the gray and white matter, but they can be

present in the subcortical area, deep in the brain parenchyma, or may even be superficial.<sup>2</sup>

The exact pathological nature of RELs is difficult to accomplish as biopsy of such lesions is performed in isolated cases only. Both the conditions can present as solitary lesion or multiple lesions.<sup>3</sup> On conventional MRI, most tuberculomas typically appear as solitary RELs on gadolinium-enhanced T1-weighted (T1W) images and infrequently as a conglomerated ring-enhancing mass.<sup>4</sup> Neurocysticercosis (NCC) has four different stages, the vesicular, colloidal vesicular, granular nodular, and nodular calcified, which are recognized on imaging. It is the colloidal vesicular and granular nodular stages that present as RELs with perilesional edema and it could be challenging to differentiate it from tuberculoma.<sup>5,6</sup>

As both lesions can be managed conservatively, it would be ideal if an etiological diagnosis be made without biopsy. The importance of differentiating these two etiologies cannot be overemphasized as solitary cysticercosis granuloma is a benign disorder that resolves spontaneously while tuberculoma requires prolonged therapy with potentially toxic drugs<sup>7</sup> (► **Table 1**).<sup>8-11</sup>

The aim of this study was to analyze the clinical and radiological parameters of different pathologies presenting

**Table 1** Research in the last one or two decades has focused on how to improve the diagnosis of tuberculomas and NCC by utilizing different MRI sequences

Study	Features	Conclusion
Pretell et al <sup>8</sup>	Studied 6 cases of NCC and 4 cases of tuberculoma for MRS findings. Chol/Cre ratio >1 was seen in all cases of tuberculoma and in none with NCC. High lipid peak was seen in tuberculomas	MRS can help avoid biopsy in granulomatous lesions of the brain
Sharma and Sharma <sup>9</sup>	Study involved 10 cases in children: 6 tuberculoma and 4 NCC. Cystic lesions on MRI with dot sign in 2 cases, and amino acid peaks on MRS were characteristic of NCC. Conglomerate lesions on MRI and lipid peak on MRS were seen in tuberculomas	Utilized clinical and radiological parameters for differentiating tuberculomas and NCC
Hanumaiah et al <sup>10</sup>	Studied radiological characteristics of 4 stages of NCC (vesicular, colloidal vesicular, granular nodular, and nodular calcific) and different stages of tuberculoma	Highlighted the radiological differentiating features of tuberculomas and NCC Used MTR as an additional radiological marker as tuberculoma lesions were bright and conspicuous on MTR in contrast to NCC
Maheshwarappa et al <sup>11</sup>	Studied the role of DWI and MRS in differentiating tuberculomas from NCC	85% of tuberculoma lesions showed diffusion restriction in contrast to none in NCC and 40% of tuberculoma lesions showed elevated lipid peak in contrast to none in NCC

Abbreviations: Chol/Cre ratio, choline-to-creatine ratio; DWI, diffusion-weighted imaging; MRI, magnetic resonance imaging; MRS, magnetic resonance spectroscopy; MTR, magnetization transfer ratio; NCC, neurocysticercosis.

as RELs and identify the possible markers that are helpful in arriving at the etiological diagnosis in two most common pathologies: NCC and tuberculomas.

## Materials and Methods

This study was performed in the inpatient Department of Neurology at Calcutta National Medical College & Hospital (CNMCH), Kolkata. Fifty-eight patients who presented with RELs on MRI were included in this study. SPSS 20 software was used as the statistical tool. Descriptive statistics, analysis of variance (ANOVA), and Pearson's chi-squared analysis were the statistical methods employed to analyze the data. NCC was diagnosed as per the revised diagnostic criteria for NCC. Epidemiological, clinical, laboratory, and radiological parameters were used to diagnose tuberculomas.

## Results

The age spectrum of the cases ranged from 12 to 72 years with a median age of 32.2 years (standard deviation [SD] = 16.373). In all, 51.7% (30) of the patients were aged between 25 and 50 years, 32.8% (19) were younger than 25 years, and only 15.5% were older than 50 years.

In our study, 56.9% (33) of the patients were females and 43.1% (25) were males. Symptom duration ranged from a minimum of less than 1 month to 12 months, with a mean of 3.1 months with a SD of 2.654.

Thirty-four of 58 cases were diagnosed as tuberculomas (58.6%), 12 (20.8%) as NCC, 7 (11.9%) as neoplastic (metastasis and astrocytoma), 2 (3.4%) as brain abscess, 2 (3.4%) as demyelinating lesions (acute disseminated encephalomyelitis (ADEM) and tumefactive multiple sclerosis), and 1 (1.7%) as toxoplasma (►Fig. 1).

Among patients who presented with seizure, 55.81% (24/43) had focal to bilateral tonic-clonic seizures, 23.25% (10/43) had focal onset seizures, and 20.93% (9/43) had generalized onset tonic-clonic seizures.

In the tuberculoma subgroup, 52.16% (12/23) had focal to bilateral tonic-clonic seizures, 26.08% (6/23) had focal onset seizure, and 21.73% (5/23) had generalized onset tonic-clonic seizures. In NCC subgroup, 45.45% (5/11) had focal

to bilateral tonic-clonic seizures, 36.36% (4/11) had focal onset seizures and 18.18% (2/11) had generalized onset tonic-clonic seizures (►Fig. 2).

The spectrum of nonseizure manifestations included headache, vomiting, fever, altered sensorium, visual disturbance, motor deficit, and cranial nerve abnormalities in our study group.

Headache was present in 91.37% (53/58), vomiting in 51.72% (30/58), fever in 36.2% (21/58), motor deficit in 34.48% (20/58), visual disturbance in 29.31% (17/58), cranial nerve deficit in 24.13% (14/58), and altered sensorium in 22.41% (13/58) of cases. ►Fig. 3 shows the frequency of nonseizure manifestations in different pathologies.

In the tuberculoma subgroup, 94.11% (32/34) patients had headache, 52.94% (18/34) each had fever and vomiting, 44.11% (15/34) had motor deficit, 32.35% (11/34) had visual disturbance 29.41% (10/34) had cranial nerve abnormalities, and 23.52% (8/34) had altered sensorium as the nonseizure manifestations.

In the NCC subgroup, headache was present in 75% (9/12) of cases, vomiting in 16.66% (2/12) cases, and visual disturbance and motor deficit in 8.3% (1/12) cases each.

Hemiparesis, monoparesis, paraparesis, and ataxia were the common motor deficits encountered in 34.5% (20/58) of the study group. Hemiparesis was present in 15.5% (9/58) cases, monoparesis and ataxia in 6.9% (4/58) each, and paraparesis in 5.2% (3/58) of cases. Those with no motor deficit comprised 65.5% (38/58) of the patients.

In total, 24.13% (14/58) of study participants had cranial nerve abnormality in the form of involvement of the oculomotor nerve and abducens nerve. Bilateral abducens paresis was present in 10.3% (6/58) of patients, followed by unilateral abducens nerve involvement in 8.6% (5/58) and unilateral oculomotor nerve paresis in 5.2% (3/58) of cases.

Abnormal fundus examination was associated with 36.20% (21/58) of studied participants. Choroid tubercles, optic neuritis, and papilledema were the common abnormalities encountered in direct ophthalmoscopy.

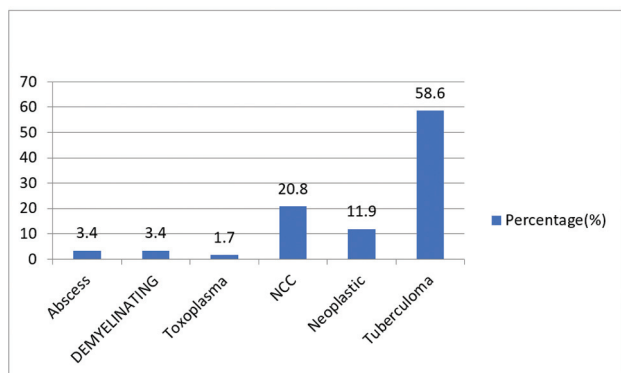
Papilledema was present in 15.5% (9/58) of patients, choroid tubercles in 13.8% (8/58), optic neuritis in 3.4% (2/58), and choroid tubercles with papilledema in 3.4% (2/58) of the studied subjects.

In the tuberculoma subgroup, 26.47% (9/34) of patients had chest X-ray abnormalities. Five of 34 (14.7%) patients had concurrent military tuberculosis, 5.88% (2/34) had upper zone opacity, and mediastinal widening with or without upper zone opacity was seen in 2.94% (1/34) of patients.

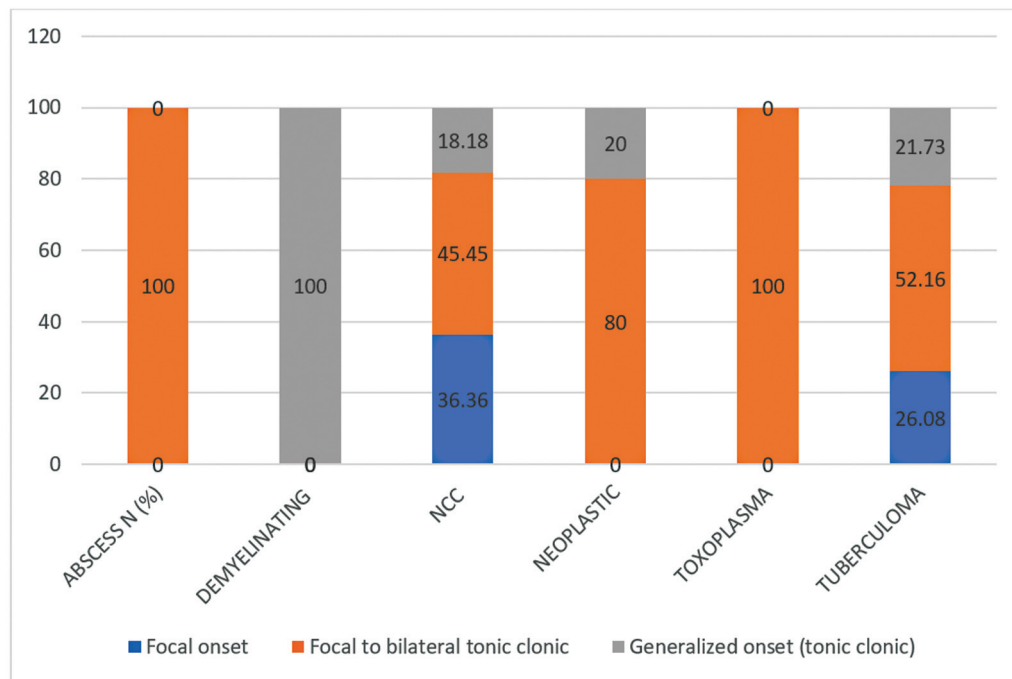
Lesion burden with a ring enhancement pattern in T1W MRI with gadolinium contrast was observed among studied participants. Patients with multiple RELs comprised 55.17% (32/58) of the patients, 27.58% (16/58) had single lesions, 13.78% (8/58) had conglomerated lesions, and 3.44% (2/58) had an incomplete ring enhancement pattern (►Fig. 4).

The pattern of ring enhancement of lesions in different pathologies is depicted in ►Fig. 5.

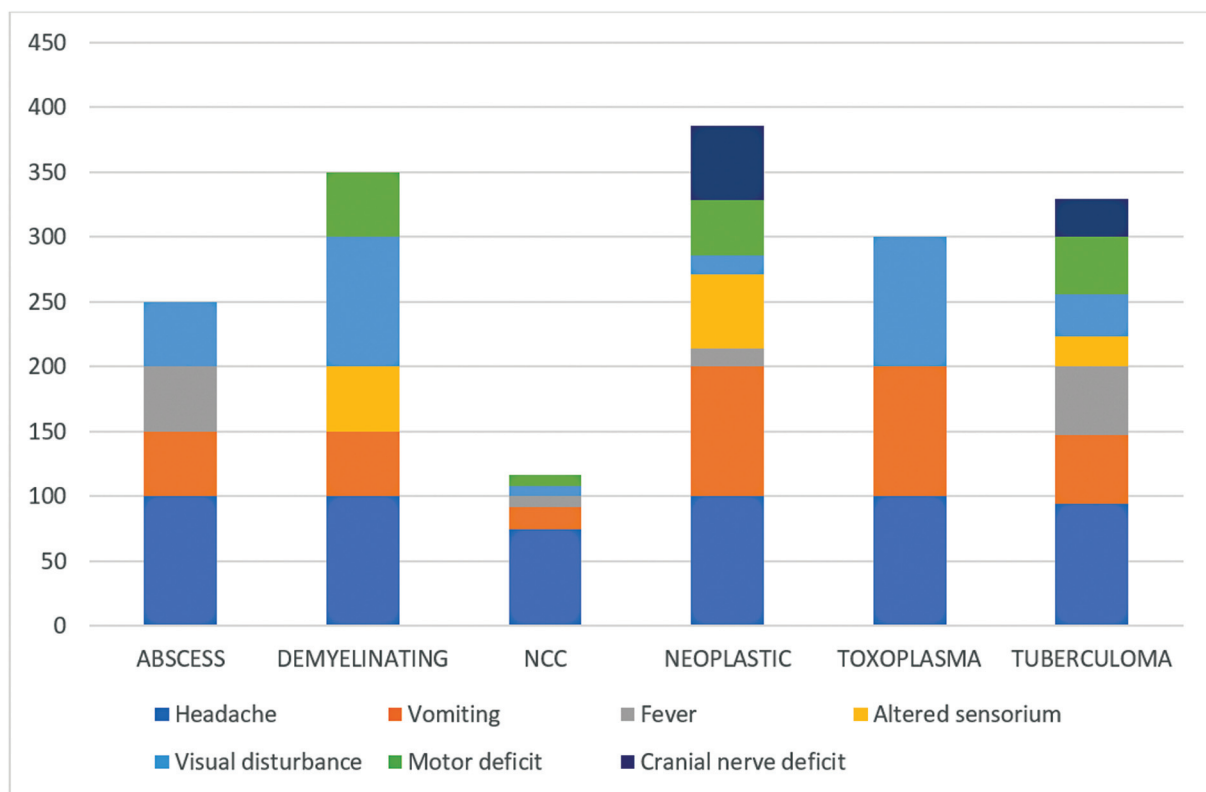
In the tuberculoma subgroup, 85.29% (29/34) patients had multiple RELs with 23.52% (8/34) showing conglomeration and 14.7% (5/34) single RELs. In the NCC subgroup, 58.33%



**Fig. 1** Frequency of different etiologies in our studied participants. NCC, neurocysticercosis.



**Fig. 2** Proportion of seizure types in different etiological categories. NCC, neurocysticercosis.

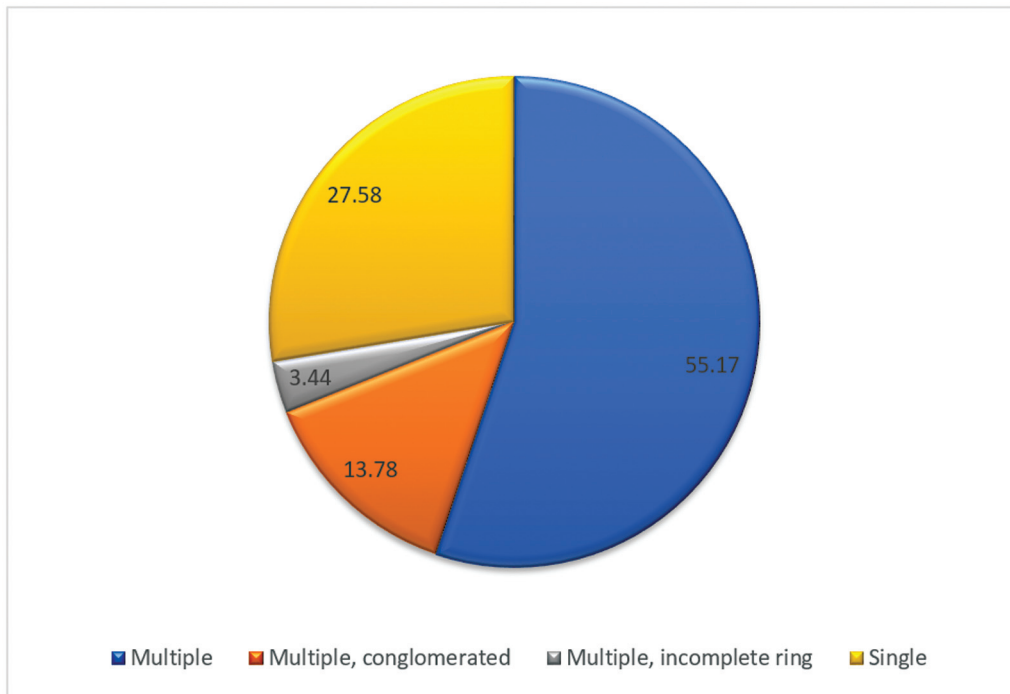


**Fig. 3** Distribution of nonseizure manifestations in different pathological subgroups. NCC, neurocysticercosis.

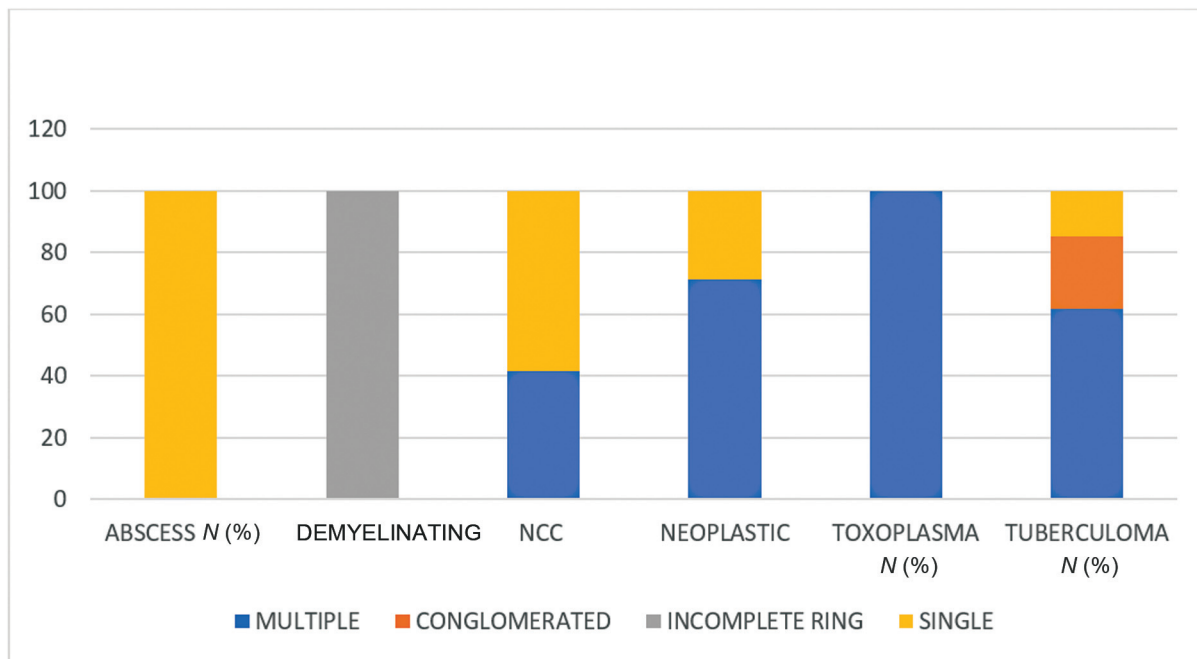
(7/12) of patients had single lesions and 41.66% (5/12) had multiple nonconglomerated enhancement patterns. In the neoplastic subgroup, 71.4% (5/7) had multiple lesions and 28.57% (2/7) had single lesions. Among the abscess subgroup, both cases had solitary lesions. All the lesions in the

demyelinating group had incomplete ring enhancement patterns. The solitary case of toxoplasma in our group had multiple ring enhancement patterns.

The number of lesions in the studied participants ranged from a minimum of 1 lesion per patient to a maximum of 24



**Fig. 4** Pattern of lesions among study participants in percentage.



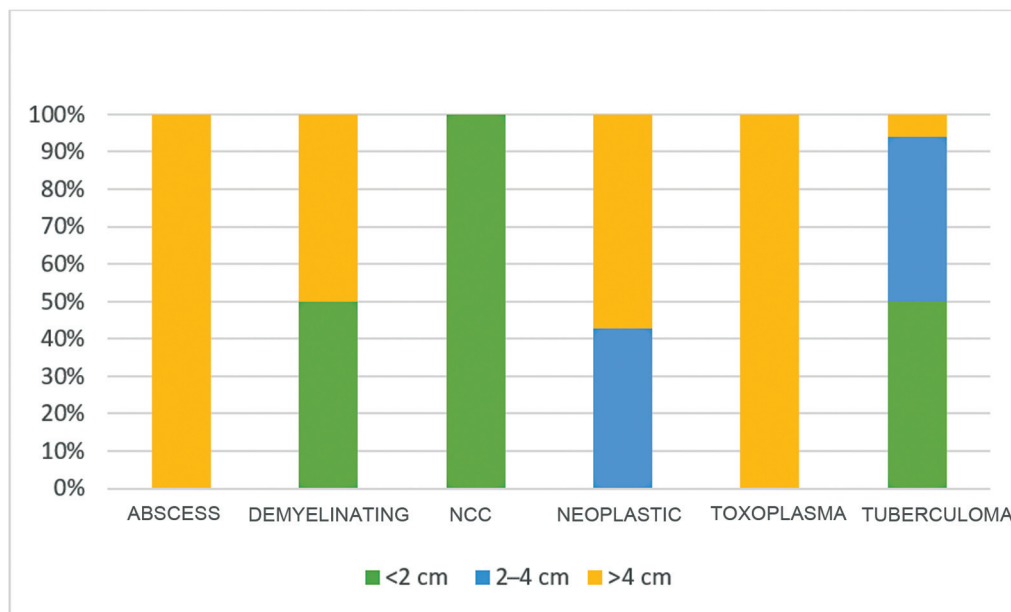
**Fig. 5** Distribution of lesion burden with contrast enhancement pattern in different pathologies. NCC, neurocysticercosis.

lesions per patient with a mean of 4.5 lesions per patient (SD=4.152) with a total of 287 counted lesions.

The maximum mean number of lesions per patient was observed in the tuberculoma subgroup with a median of 6 lesions per patient, followed by demyelinating (5), neoplastic (4), NCC (3), toxoplasma (2), and abscess (1). The size of RELs ranged from a minimum of 1 mm to a maximum of 70 mm with a mean size of 21.79 mm (SD= 1.64).

The mean size of the lesion in the tuberculoma subgroup was 1.98 cm and that in the NCC subgroup was 0.76 cm. In other etiologies like abscess, the mean size was 4.6 cm; it was 4.3 cm in neoplastic lesions, 2.5 cm in demyelinating lesions, and 5.00 cm in toxoplasmas.

► **Fig. 6** depicts the size of lesions in different pathological subgroups. In the tuberculoma subgroup, 50% (17/34) of cases had size less than 2 cm, 44.11% (15/34) had lesion



**Fig. 6** Distribution of lesion size in different diagnostic categories. NCC, neurocysticercosis.

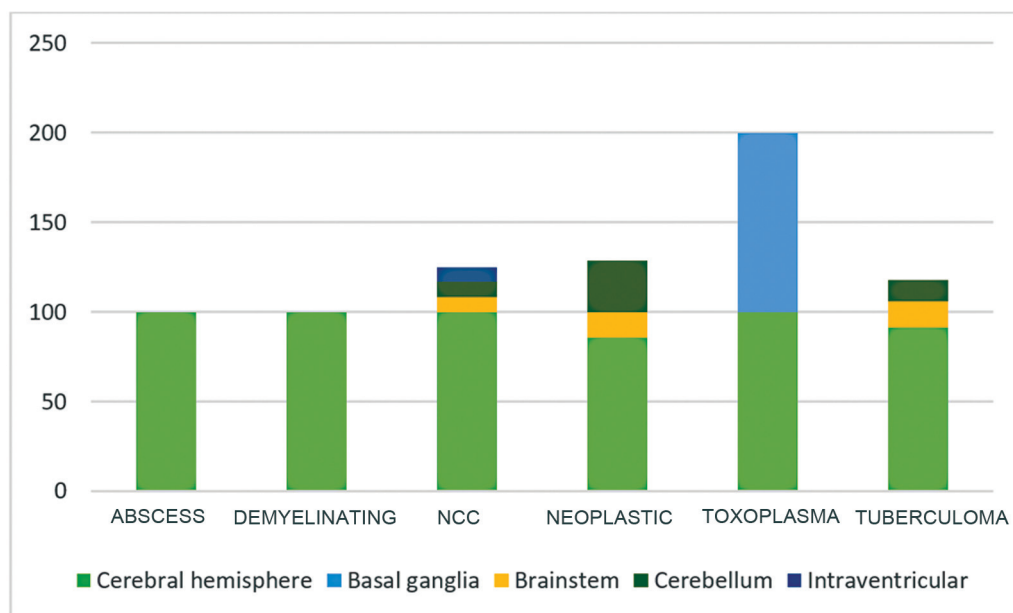
size between 2 and 4 cm, and 5.88% (2/34) had a diameter greater than 4 cm. In the NCC subgroup, all cases had a size less than 2 cm in diameter.

Cerebral hemispheres, basal ganglia, brain stem, cerebellum, and ventricles were the sites involved in the studied patients with RELs as depicted in ►**Fig. 7**. In the tuberculoma subgroup, 91.17% (31/34) patients had lesions in the cerebral hemispheres, 14.7% (5/34) had brain stem, and 11.76% (4/34) had cerebellar involvement.

In the NCC subgroup, all patients (100%) had cerebral hemispheric involvement with 8.33% (1/12) each having brain stem, cerebellar, and intraventricular involvement. In

all, 85.71% (6/7) of the neoplastic subgroup had cerebellar hemispheric involvement, 28.57% (2/7) cerebellar, and 14.28% (1/7) brain stem involvement. Two of the brain abscesses and demyelinating lesions were localized to cerebral hemispheres. The patient with toxoplasma had lesions distributed in the cerebral hemispheres and basal ganglia.

Different sequences of MRI such as T1W, T2-weighted (T2W), T2 fluid-attenuated inversion recovery (FLAIR), diffusion-weighted imaging (DWI), and MRS characteristics were studied among the tuberculoma and NCC subgroups. Among 12 studied NCC subjects, marked T1 hypointensity was seen in 8 cases (66.67%), hypointensity in 3 (25%), and



**Fig. 7** Regional distribution of lesions in different pathologies. NCC, neurocysticercosis.



**Table 2** T1-weighted MRI characteristics between the NCC and tuberculoma subgroups

Diagnosis	T1			Total	p-value
	Hypo (N)	Iso (N)	Marked hypo (N)		
NCC	3	1	8	12	0.001
Tuberculoma	23	10	1	34	
Total	26	11	9	46	

Abbreviations: MRI, magnetic resonance imaging; NCC, neurocysticercosis.

isointensity in 1 (8.34%). Among 34 cases of tuberculoma, 23 (67.64%) showed hypointensity, 10 (29.41%) were isointense, and 1 (2.94%) had marked hypointensity on T1 sequences (► **Table 2**).

On T2 sequence MRI, the NCC subgroup showed hyperintensity in 11/12 (91.67%) subjects and 1 (8.33%) showed hypointensity. In the tuberculoma subgroup, 32 of 34 (94.12%) subjects showed hyperintensity and 2 (5.88%) showed hypointensity (► **Table 3**).

On T2 FLAIR sequence, 8 of 12 (66.67%) patients with NCC diagnosis showed full fluid suppression and 4 (33.34%) subjects showed no suppression. In the tuberculoma subgroup, 21 of 34 (61.76%) patients had no fluid suppression, 9 of 34 (26.47%) had partial suppression, and 4 of 34 (11.76%) showed full fluid suppression (► **Table 4**).

On DWI in the NCC subgroup, only 1 of 12 (8.33%) showed diffusion restriction and 7 of 34 (20.58%) tuberculoma cases showed diffusion restriction (► **Table 5**).

On MRS, lipid lactate peak and choline-to-creatine ratio (Chol/Cre ratio) were compared between the NCC and tuberculoma subgroups. A normal lipid lactate peak was observed among 10 (83.33%) of 12 subjects in the NCC subgroup. Among patients with tuberculoma, half (50%) of the cases showed high lipid lactate peak (► **Table 6**).

The mean Chol/Cre ratio in the NCC and tuberculoma subgroups was 1.05 (SD = 0.162) and 1.96 (SD = 0.451), respectively. The Chol/Cre ratio was less than 1.2 in four subjects and between 1.2 and 2.0 in eight subjects in the NCC subgroup. Among the patients with tuberculoma, 20 patients showed a Chol/Cre ratio between 1.2 and 2.0, 13 had a ratio of more than 2, and 1 had a ratio of less than 1.2 (► **Table 7**).

In the NCC subgroup, the mean cerebrospinal fluid (CSF) cell counts were 8.33 (SD: 11.396), mean protein was 44.5 mg/dL (S.D = 16.138), and mean CSF sugar 70.92 mg/dL (SD = 6.788). Among the tuberculoma subgroup, the mean CSF cell counts observed were 27 (SD = 23.286) with the mean CSF protein of

80.56 mg/dL (S.D = 47.62) and mean CSF sugar of 61.41 mg/dL (SD = 20.55).

The CSF cell counts, protein, and sugar were abnormal only in 16.67% of the NCC subgroup, whereas in the tuberculoma subgroup, the CSF cells were abnormal in 76.47%, protein in 91.17%, and sugar in 91.17% (► **Table 8**).

► **Figs. 8** and **9** show sample cases from the study reflecting tuberculomas and NCC, respectively.

## Discussion

The age of study participants ranged from 12 to 72 years with a median age of 32.2 years. Thirty-four of 58 cases were diagnosed as tuberculomas (58.6%) and 12 (20.8%) as NCC, 7 (11.9%) as neoplastic (metastasis and astrocytoma), 2 (3.4%) as brain abscess, 2 (3.4%) as demyelinating lesions (ADEM and tumefactive multiple sclerosis), and 1 (1.7%) as toxoplasma. In a CT study of 110 patients with multiple enhancing brain lesions, Garg et al reported the infectious pathology as the most common etiology with tuberculoma having an incidence of 27% followed by NCC 9.09%. Forty-five cases in this particular study remained undiagnosed after the initial workup.<sup>12</sup>

However, a study by Schwartz et al<sup>13</sup> reported that 40% were gliomas, 30% metastases, 8% abscesses, and 6% demyelinating disease among 221 RELs in MRI, suggesting neoplastic etiology as the commonest in their studied group. This difference can be due to the low prevalence of infectious diseases in the western world.

Among all patients with RELs, seizures were reported in nearly 75% at presentation. Garg et al<sup>12</sup> reported seizures as the presenting symptom in 39% of cases. However, in a study of the pediatric population by Varma et al,<sup>14</sup> seizures were reported in 98% of cases at presentation, which could be attributed to a physiologically increased epileptogenic potential in the early developmental phases. In our study,

**Table 3** T2-weighted MRI characteristics between the NCC and tuberculoma subgroups

Diagnosis	T2		Total	p-value
	Hyper (N)	Hypo (N)		
NCC	11	1	12	0.768
Tuberculoma	32	2	34	
Total	43	3	46	

Abbreviations: MRI, magnetic resonance imaging; NCC, neurocysticercosis.

**Table 4** T2 FLAIR MRI characteristics between the NCC and tuberculoma subgroups

Diagnosis	T2 FLAIR			Total	p-value
	Full suppression (N)	No suppression (N)	Partial suppression (N)		
NCC	8	4	0	12	0.001
Tuberculoma	4	21	9	34	
Total	12	25	9	46	

Abbreviations: FLAIR, fluid-attenuated inversion recovery; MRI, magnetic resonance imaging; NCC, neurocysticercosis.

**Table 5** DWI MRI characteristics between the NCC and tuberculoma subgroups

Diagnosis	DWI		Total	p-value
	No restriction (N)	Restriction (N)		
NCC	11	1	12	0.659
Tuberculoma	27	7	34	
Total	38	8	46	

Abbreviations: DWI, diffusion-weighted imaging; MRI, magnetic resonance imaging; NCC, neurocysticercosis.

**Table 6** Lipid lactate peak in MRS between the NCC and tuberculoma subgroups

Diagnosis	Lipid lactate		Total	p-value
	Normal (N)	High (N)		
NCC	10	2	12	0.044
Tuberculoma	17	17	34	
Total	27	19	46	

Abbreviations: MRS, magnetic resonance spectroscopy; NCC, neurocysticercosis.

**Table 7** Chol/Cre ratio in MRS between the NCC and tuberculoma subgroups

Diagnosis	Chol/Cre ratio			Total	p-value
	Less than 1.2	Between 1.2 and 2	More than 2		
NCC	4	8	0	12	0.002
Tuberculoma	1	20	13	34	
Total	5	28	13	46	

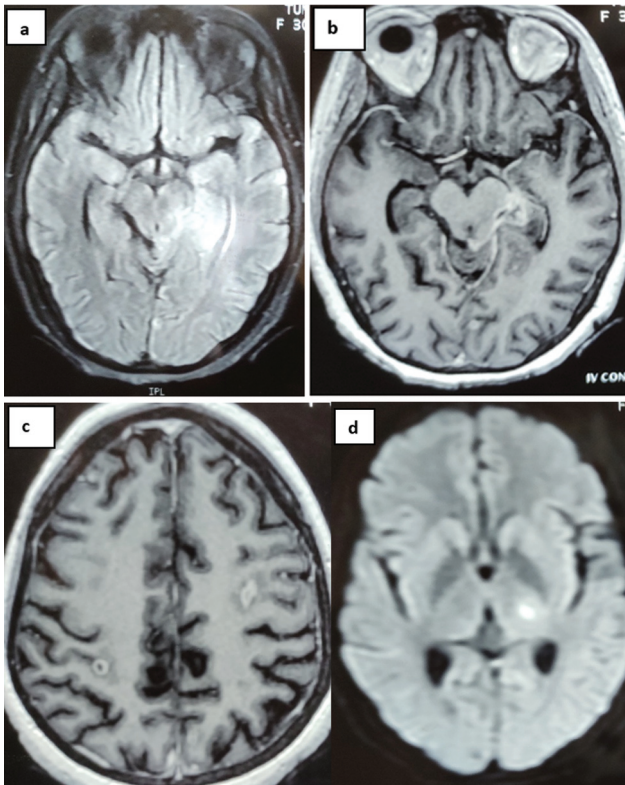
Abbreviations: Chol/Cre ratio, choline-to-creatine ratio; CSF, cerebrospinal fluid; MRS, magnetic resonance spectroscopy; NCC, neurocysticercosis.

**Table 8** Descriptive statistics of CSF cell counts, protein, and sugar in the NCC and tuberculoma subgroups

Diagnostic category		CSF cells	Protein	Sugar
NCC	Mean	8.33	44.5000	70.92
	N	12	12	12
	Standard deviation	11.396	16.13860	6.788
Tuberculoma	Mean	27.00	80.5588	61.41
	N	34	34	34
	Standard deviation	23.286	47.62555	20.553
Total	Mean	22.13	71.1522	63.89
	N	46	46	46
	Standard deviation	22.318	44.53412	18.408
p-value		0.011	0.014	0.125

Abbreviations: CSF, cerebrospinal fluid; NCC, neurocysticercosis.

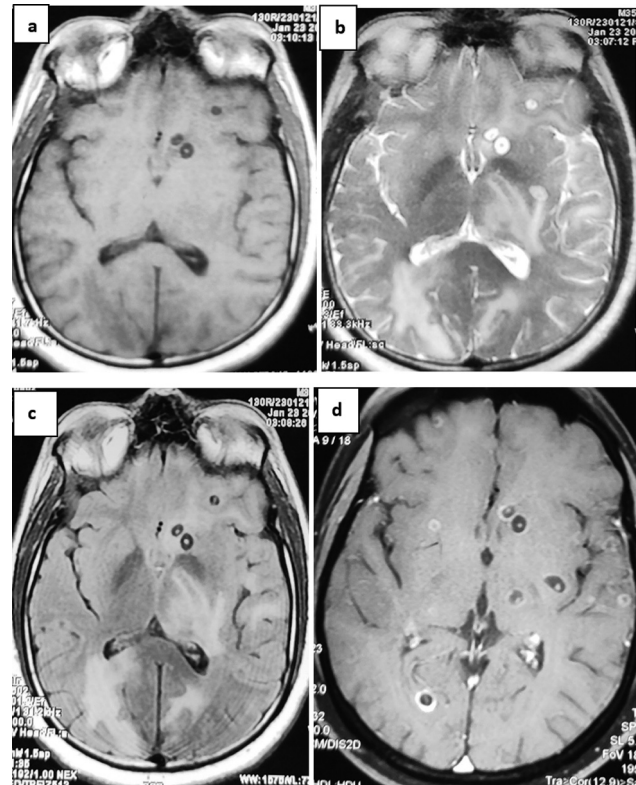




**Fig. 8** Hyperintense lesion on T2 fluid-attenuated inversion recovery (FLAIR) image involving (a) a part of the left medial temporal lobe and adjacent midbrain in a patient of tuberculous meningitis. (b,c) Focal meningeal enhancement in the same region with exudates on axial T1 with contrast and additional contrast enhancing lesions, the one in the left frontal lobe depicting conglomeration. (d) Restricted diffusion lesion seen in the left thalamus on diffusion-weighted imaging (DWI) indicating an acute infarction secondary to tubercular endarteritis.

41.47% of patients presented with focal to bilateral tonic-clonic seizures, 17.24% had focal onset seizures, 15.51% had generalized onset tonic-clonic seizures, and 25.86% did not report any seizures. In a similar study, Gandhi and Khalid<sup>15</sup> reported focal onset seizures in 32.5%, secondary generalized seizures in 27.5%, and generalized seizures in 40% of cases.

Out of the two most prevalent etiologies of RELs in our study, NCC had the highest seizure incidence at presentation, seen in 92% of cases, while in the tuberculoma group, the incidence was reported to be 68%. The proportion of focal onset seizures with or without generalization was 77% in NCC and approximately 81% in tuberculoma, with statistically insignificant results. Carpio et al<sup>16</sup> reported a seizure incidence of 58.1% in a study of NCC. In a study of seizures in tuberculous meningitis by Misra et al,<sup>17</sup> seizures were reported in 34.2% of cases, and tuberculoma was seen in 38.5% of seizure cases. In another study of tuberculous meningitis with or without tuberculomas by Song et al,<sup>18</sup> seizures were reported in 20.3% cases, with focal seizures seen in 23.9%. A slightly higher seizure frequency for tuberculomas in our study could be attributed to an overall higher chance of seizures in parenchymal tuberculomas compared with tuberculous meningitis in isolation.



**Fig. 9** Multiple hypointense lesions with a central dotlike hyperintensity on (a) axial T1-weighted image (T1WI) in a patient diagnosed with neurocysticercosis (NCC). The same lesions showing hyperintense signal with central hypointensity on (b) axial T2WI with (c) full fluid-attenuated inversion recovery (FLAIR) suppression. (d) Multiple lesions at a higher level on axial T1WI after gadolinium administration showing ring enhancement pattern, some of them showing eccentric dots characteristic of scolex.

Among all the patients with RELs, headache was present in 91.37%, vomiting in 51.72%, fever in 36.2%, motor deficit in 34.48%, visual disturbance in 29.31%, cranial nerve deficit in 24.13%, and altered sensorium in 22.41% of cases. Our findings are consistent with the results from other studies. Garg et al reported the frequency of headache in a study of multiple RELs to be 88%, vomiting to be 59%, fever to be 21%, motor deficit to be 29%, cranial nerve palsy to be 8%, and altered sensorium to be 35%.<sup>12</sup> Wasay et al in a similar study reported fever in 79% of patients, decreased consciousness in 60%, headache in 57%, and nausea and vomiting in 53% of the patients.<sup>19</sup>

In the tuberculoma subgroup, 94.11% of patients had headaches, 52.94% each had fever and vomiting, 44.11% had a motor deficit, 32.35% had visual disturbance, 29.41% had cranial nerve abnormalities, and 23.52% had altered sensorium as the nonseizure manifestations. Harder et al, in a study of intracranial tuberculomas, reported headache in 60%, multiple symptoms including visual disturbance and ataxia in 70%, and fever in 25%.<sup>20</sup>

In the NCC subgroup, headache was present in 75% of cases, vomiting in 16.66% cases, and visual disturbance and motor deficit in 8.3% cases each. In a study of NCC from Eastern India, Bhattacharjee et al reported headache with a frequency of 63.2% and cranial nerve deficit in 10.5%.<sup>21</sup> In a

study of NCC in the pediatric population, Balaji reported headache with vomiting in 15.4% of cases and altered sensorium in 5.8% cases.<sup>22</sup>

Hemiparesis, monoparesis, paraparesis, and ataxia were the common motor deficits encountered in 34.5% of the study group. Hemiparesis was present in 15.5%, monoparesis and ataxia in 6.9% each, and paraparesis in 5.2% of cases. In all, 65.5% had no motor deficit. Hemiparesis was reported as the most common motor deficit (80%), followed by monoparesis (20%) in a similar study by Gandhi and Khalid.<sup>15</sup>

Abnormal fundus examination was associated with 36.20% ( $n=21/58$ ) of studied participants.

Papilledema was present in 15.5% of patients, choroid tubercles in 13.8%, optic neuritis in 3.4%, and choroid tubercles with papilledema in 3.4% of the studied subjects. Garg et al reported papilledema in 5% of cases presenting with RELs.<sup>12</sup> Kent et al reported choroid tubercles in 7% of cases in a study of tuberculous meningitis.<sup>23</sup>

MRI study of the participants in our study revealed 55.17% of patients had multiple discrete RELs, 27.58% had single lesions, 13.78% had conglomerated lesions, and 3.44% had multiple incomplete RELs. The incidence of solitary and multiple lesions in the study by Gandhi and Khalid was 90 and 10%, respectively.<sup>15</sup> Similarly, Varma et al reported the incidence of solitary lesions to be 77.1% and multiple lesions to be 22.9%.<sup>14</sup>

In the tuberculoma subgroup, 61.76% of patients had multiple discrete RELs, 23.52% had conglomeration, and 14.7% had single RELs. In the NCC subgroup, 58.33% of patients had single lesions and 41.66% had multiple discrete RELs. In the neoplastic subgroup, 71.4% had multiple lesions and 28.57% had single lesions. All the lesions in the demyelinating group had an incomplete ring enhancement pattern. The median number of lesions in the tuberculoma subgroup was six and that in the NCC subgroup was four. Our findings match with the observations drawn from other studies. Wasay et al, in a study of 100 tuberculoma cases, found 31% of cases having single lesions and 69% having multiple lesions.<sup>19</sup> Bhattacharjee et al while studying NCC in children reported 71.1% of lesions to be solitary and 28.9% of the lesions to be multiple.<sup>21</sup> Kim et al in a small study reported the incidence of conglomerate lesions in tuberculoma to be 100%.<sup>4</sup> Conglomerate lesions are, however, not considered pathognomonic of tuberculomas and have been reported to be equally frequent in NCC. Garg et al in a large study of NCC showed conglomeration to occur with a frequency of 58%.<sup>24</sup>

The mean size of lesions in the tuberculoma subgroup was 19.8 mm and that in the NCC subgroup was 7.6 mm. In the tuberculoma subgroup, 50% of cases had a size less than 2 cm, 44.11% had lesion size between 2 and 4 cm, and 5.88% had a diameter greater than 4 cm. In the NCC subgroup, all cases had a size less than 2 cm in diameter ( $p=0.009$ ), signifying a strong association between size and the etiology. In a similar study, Patil et al showed that 66% of all the RELs were less than 2 cm in size, 26% were between 2 and 4 cm, and 8% were more than 4 cm.<sup>25</sup> The size distribution of lesions in tuberculoma in the study by Wasay et al was as follows:

86% lesions were less than 1 cm, 11% lesions were between 1 and 3 cm, and 3% lesions were greater than 3 cm.<sup>19</sup> Sonmez et al in a similar study of tuberculoma patients reported 90% of the lesions to be less than 2.5 cm and only 10% lesions were greater than 2.5 cm.<sup>26</sup> All these studies, including ours, depict the correlation of smaller-sized lesions with NCC.

Cerebral hemispheres, basal ganglia, brain stem, cerebellum, and ventricles were the sites involved in the studied patients with RELs. In the tuberculoma subgroup, 91.17% of patients had lesions in the cerebral hemispheres, 14.7% had brain stem, and 11.76% had cerebellar involvement. The incidence of supratentorial distribution of tuberculoma lesions in the study by Arseni was 33.33%, while cerebellar and brainstem distribution was 62.18 and 4.47%, respectively.<sup>27</sup>

In the NCC subgroup, all patients (100%) had cerebral hemispheric involvement, with 8.33% having additional involvement of brain stem or cerebellar or intraventricular regions. These findings match with the results from the study of NCC by Bhattacharjee et al who also reported the lesion distribution to be supratentorial in 100% of cases.<sup>21</sup> Garg et al, in a similar study of NCC cases, reported 96% of the lesion distribution to be supratentorial, 3% to be brainstem, and 1% to be cerebellar.<sup>24</sup> Observations from these studies including ours show that tuberculomas tend to have a higher prevalence of infratentorial distribution than NCCs.

Out of a total of 64 lesions of NCC, 38 lesions were vesicular, 8 colloidal, 10 granular-nodular and, 8 calcified. Nine cases had lesions in two or more stages, whereas the rest had vesicular stage lesions only.

On T1 sequences, 82.75% of all the lesions were hypointense and 17.25% of the lesions were isointense, while on T2W imaging (T2WI), 91.37% lesions were hyperintense, 3.44% were isointense, and 5.17% were hypointense. A comparison was made between the two most prevalent etiologies: tuberculoma and NCC subgroups. In the NCC subgroup, 66.66% were markedly hypointense on T1 sequences, 25% were slightly hypointense, and 8.33% were isointense. In the tuberculoma subgroup, only 2.94% of lesions were markedly hypointense, 67.64% were slightly hypointense, and 29.41% were isointense ( $p=0.001$ ). On T2 sequences, 91.66% of the lesions in the NCC subgroup were hyperintense and 8.33% of the lesions were hypointense. Among the tuberculoma subgroup, 94.11% of the lesions were hyperintense and 5.88% were hypointense ( $p=0.768$ ). On T2 FLAIR sequence, 66.66% of NCC lesions showed FLAIR suppression, that is, became hypointense as CSF signal and 33.33% showed no suppression. Among the tuberculoma subgroup, 61.76% of lesions had no FLAIR suppression, 26.47% had partial suppression, and only 11.76% showed full suppression ( $p=0.001$ ). On DWI, the frequency of diffusion restriction lesions in NCC and tuberculoma was 8.33 and 20.58%, respectively. Our results are consistent with the data from other studies ( $p=0.659$ ).

Parry et al,<sup>28</sup> in a similar study, showed 100% of NCC lesions to be hypointense on T1W images and hyperintense on T2WIs reflecting the vesicular nature of all the lesions. In the same study, in the tuberculoma group, 61% of the lesions

were isointense on T1 and 39% were hypointense. On T2W sequences, 38.4% of tuberculoma lesions were hypointense on T2 and 61.6% were hyperintense on T2. The authors also concluded that diffusion restriction was rare in NCC as compared with tuberculomas (mean apparent diffusion coefficient [ADC] value NCC vs. tuberculoma = 1.64 vs. 1.027).<sup>28</sup> In a radiological study for the utility of MRI and MRS in distinguishing tuberculomas from NCC, Maheshwarappa et al found no diffusion restriction in NCC lesions, while diffusion restriction was noted in 82.35% of tuberculoma lesions.<sup>11</sup> T2 FLAIR suppression was noted in 75% of NCC lesions by Thite et al.<sup>29</sup> Patil et al, in a similar study, showed all the lesions in the NCC to be hypointense on T1W images and hyperintense on T2WI with 57.89% of the lesions showing T2 FLAIR suppression.<sup>25</sup> Findings from all these studies show that NCC lesions are usually hypointense on T1, hyperintense on T2, with the majority of the lesions showing T2 FLAIR suppression—higher in vesicular than colloid stage and no diffusion restriction. In contrast, tuberculomas can be hypo- or isointense on T1 depending on the presence or absence of caseous necrosis, hyperintense on T2 with minimal or no FLAIR suppression, and a proportion of lesions showing diffusion restriction.

Out of 64 lesions in the NCC group, 18 (28.1%) lesions were thick walled and 38 lesions were thin walled, whereas in the tuberculoma group, 186 of 244 lesions (76.22%) were thick walled.

Significant surrounding edema was noted in 26 (40.6%) lesions in the NCC group and 192 (78.6%) lesions in the tuberculoma group. Central dot sign or target sign was noted in 15.2% of tuberculoma lesions. Eccentric and central dot signs in combination were seen in 35% of NCC lesions, with eccentric dots being more frequent. However, the results were not statistically significant.

On MRS, lipid lactate peak and Chol/Cre ratio were compared between the NCC and tuberculoma subgroups. Elevated lipid lactate peak was observed in 16.67% in the NCC subgroup and it was normal in 83.33%. In the tuberculoma subgroup, half of the patients had high lipid lactate peaks ( $p = 0.044$ ).

The Chol/Cre ratio was less than 1.2 in 33.33% and between 1.2 and 2.0 in 66.66% of subjects in the NCC subgroup. However, 58.82% of patients in the tuberculoma subgroup showed a Chol/Cre ratio between 1.2 and 2.0, while 38.23% showed a ratio greater than 2 and 1 case was reported to have a ratio of less than 1.2 ( $p = 0.002$ ). The mean Cho/Cre ratio in the tuberculoma subgroup was 1.95 and in the NCC subgroup, it was 1.06. The results from the study by Parry et al showed 75% of the tuberculoma lesions showing elevated lipid peak, with 41.67% also demonstrating elevated lactate peak, while none of the lesions demonstrated to have elevated lipid peak. However, elevated lactate peak was seen in 33.33% cases. In the same study, the author reported a mean Chol/Cr ratio of 0.95 and 1.36 in the NCC and tuberculoma subgroups, respectively.<sup>28</sup> Similarly, in the study by Maheshwarappa et al,<sup>11</sup> none of the NCC lesions were found to have elevated lipid peak, but 94.11% of tuberculoma lesions were demonstrated to have elevated lipid peaks. In the same study, the Cho/Cre ratio was reported

as normal in all cases of NCC and elevated ( $>1$ ) in 41.17% of tuberculomas. All these studies have come to the conclusion that NCC lesions show normal MRS findings, while a significant proportion of tuberculoma lesions show elevated lipid peak and mildly elevated Cho/Cre ratio.

CSF cell count was abnormal in 60.3% and elevated protein was seen in 75.9% of cases. On comparing the CSF results among the tuberculoma and NCC groups, minimal abnormalities were observed in the NCC group. CSF cell count and protein were abnormal in 16.66% of NCC cases, whereas in the tuberculoma subgroup, cell count was abnormal in 76.47% of cases and CSF protein was elevated in 91.17% of cases. Our results are different from those shown by Garg et al in their study of multiple RELs. The authors reported abnormal CSF in only 18% of cases.<sup>12</sup> Morales et al in a study of NCC reported normal CSF analysis in 58.3% and elevated protein in 37.5%.<sup>30</sup> The CSF cell count has been reported to be elevated in the range of 100 to 500 cells/ $\mu\text{L}$  in tuberculous meningitis.<sup>31</sup> However, it is expected to be low in tuberculomas without meningitis.

## Conclusion

RELs include a diverse spectrum of pathologies. Establishing the definitive diagnosis remains a challenge particularly in centers lacking the facility for less invasive stereotactic biopsy. Tuberculoma was the most common diagnosis with 58.6% of cases, followed by NCC (20.8%). The frequency of seizure at presentation in our study was 74.14%, with focal seizure being the most common seizure. NCC had a slightly higher frequency of seizures as compared with tuberculoma (91.66 vs. 67.65%). Nonseizure manifestations included headache, vomiting, fever, altered sensorium, visual disturbance, motor deficit, and cranial nerve abnormalities. Cerebral hemispheres, basal ganglia, brain stem, cerebellum, and ventricles are the sites involved in the studied patients with RELs. The characteristic features on different MR sequences and MRS can aid in making a reliable diagnosis and distinguishing between tuberculoma and NCC.

## Statement of Conformation to the Declaration of Helsinki

All procedures performed in studies involving human participants were in accordance with the ethical standards of the institutional and/or national research committee and with the 1964 Helsinki Declaration and its later amendments or comparable ethical standards. Informed consent was obtained from all individual participants involved in the study.

## Author Contributions

G.P.M. and C.P. developed the concept. R.B. designed the study. C.P. and S.A.P. collected the data. K.C.G. conducted the literature overview and was involved in discussions. S.A.P. analyzed the data and performed the statistical analysis.

## Conflict of Interest

None declared.



## References

- 1 Omuro AM, Leite CC, Mokhtari K, Delattre JY. Pitfalls in the diagnosis of brain tumours. *Lancet Neurol* 2006;5(11):937–948
- 2 Smirniotopoulos JG, Murphy FM, Rushing EJ, Rees JH, Schroeder JW. Patterns of contrast enhancement in the brain and meninges. *Radiographics* 2007;27(02):525–551
- 3 Wetzel SG, Kollmann T. Neurotuberculosis. In: Hähnel S, ed. *Inflammatory Diseases of the Brain*. Berlin: Springer; 2009:75–83
- 4 Kim TK, Chang KH, Kim CJ, Goo JM, Kook MC, Han MH. Intracranial tuberculoma: comparison of MR with pathologic findings. *AJNR Am J Neuroradiol* 1995;16(09):1903–1908
- 5 Del Brutto OH, Nash TE, White AC Jr, et al. Revised set of diagnostic criteria for neurocysticercosis (in reply to Garg and Malhotra). *J Neurol Sci* 2017;373:350–351
- 6 Lucato LT, Guedes MS, Sato JR, Bacheschi LA, Machado LR, Leite CC. The role of conventional MR imaging sequences in the evaluation of neurocysticercosis: impact on characterization of the scolex and lesion burden. *AJNR Am J Neuroradiol* 2007;28(08):1501–1504
- 7 Rajshekhar V. Etiology and management of single small CT lesions in patients with seizures: understanding a controversy. *Acta Neurol Scand* 1991;84(06):465–470
- 8 Pretell EJ, Martinot C Jr, Garcia HH, Alvarado M, Bustos JA, Martinot CCysticercosis Working Group in Peru. Differential diagnosis between cerebral tuberculosis and neurocysticercosis by magnetic resonance spectroscopy. *J Comput Assist Tomogr* 2005;29(01):112–114
- 9 Sharma B, Sharma S. Neurocysticercosis (NCC) vs central nervous system (CNS) tuberculoma in children: dilemma over clinico-radiological diagnosis? *Open J Pediatr* 2016;06:245–251
- 10 Hanumaiah R, Patwari S. Diagnostic dilemma in differentiating neurocysticercosis (NCC) and tuberculomas (TB) on imaging Poster presented at: ECR 2017 - European Congress of Radiology Annual Meeting. ; March 1–5, 2017; Budapest, Hungary
- 11 Maheshwarappa RP, Agrawal C, Bansal J. Tuberculoma versus neurocysticercosis: can magnetic resonance spectroscopy and diffusion weighted imaging solve the diagnostic conundrum? *J Clin Diagn* 2002;13(06):1–6
- 12 Garg RK, Desai P, Kar M, Kar AM. Multiple ring enhancing brain lesions on computed tomography: an Indian perspective. *J Neurol Sci* 2008;266(1–2):92–96
- 13 Schwartz KM, Erickson BJ, Lucchinetti C. Pattern of T2 hypointensity associated with ring-enhancing brain lesions can help to differentiate pathology. *Neuroradiology* 2006;48(03):143–149
- 14 Varma KK, Pranaya P, Kumar VR. . The clinical profile of ring-enhancing lesions among children below 12 years presenting with epileptic and non-epileptic manifestations in a tertiary care hospital. *IJHCR* 2021;4(04):184–187
- 15 Gandhi RG, Khalid TMA. A study of clinical profile and etiology ring enhancing lesion in CT scan brain at a tertiary care center. *Int J Advances Medicine* 2019;6(03):574–579
- 16 Carpio A, Fleury A, Romo ML, et al. New diagnostic criteria for neurocysticercosis: Reliability and validity. *Ann Neurol* 2016;80(03):434–442
- 17 Misra UK, Kumar M, Kalita J. Seizures in tuberculous meningitis. *Epilepsy Research* 2018;148:90–95
- 18 Song X, Wen L, Li M, Yu X, Wang L, Li K. New-onset seizures in adults with tuberculous meningitis during long-term follow-up: Characteristics, functional outcomes and risk factors. *Int J Infect Dis* 2020;93:258–263
- 19 Wasay M, Khealani BA, Moolani MK, et al. Brain CT and MRI findings in 100 consecutive patients with intracranial tuberculoma. *J Neuroimaging* 2003;13(03):240–247
- 20 Harder E, Al-Kawi MZ, Carney P. Intracranial tuberculoma: conservative management. *Am J Med* 1983;74(04):570–576
- 21 Bhattacharjee S, Biswas P, Mondal T. Clinical profile and follow-up of 51 pediatric neurocysticercosis cases: a study from Eastern India. *Ann Indian Acad Neurol* 2013;16(04):549–555
- 22 Balaji J, D M. Clinical and radiological profile of neurocysticercosis in South Indian children. *Indian J Pediatr* 2011;78(08):1019–1020
- 23 Kent SJ, Crowe SM, Yung A, Lucas CR, Mijch AM. Tuberculous meningitis: a 30-year review. *Clin Infect Dis* 1993;17(06):987–994
- 24 Garg A, Kaur KP, Devaranjan Sebastian LJ, et al. Conglomerate ring-enhancing lesions are common in solitary neurocysticercosis and do not always suggest neurotuberculosis. *Ann Indian Acad Neurol* 2019;22(01):67–72
- 25 Patil YP, Patel CR, Kuber RS, Sekhon RK. Characteristics of ring enhancing lesions in brain in correlation with MRI and MR spectroscopy. *IJHCR* 2021;4(01):120–127
- 26 Sonmez G, Ozturk E, Sildiroglu HO, et al. MRI findings of intracranial tuberculomas. *Clin Imaging* 2008;32(02):88–92
- 27 Arseni C. Two hundred and one cases of intracranial tuberculoma treated surgically. *J Neurol Neurosurg Psychiatry* 1958;21(04):308–311
- 28 Parry AH, Wani AH, Shaheen FA, Wani AA, Feroz I, Ilyas M. Evaluation of intracranial tuberculomas using diffusion-weighted imaging (DWI), magnetic resonance spectroscopy (MRS) and susceptibility weighted imaging (SWI). *Br J Radiol* 2018;91(1091):20180342
- 29 Thite H, Sahoo K, Shaha P, Goyal V, Tyagi V, Aggarwal D. Magnetic resonance imaging in characterisation of intra-cranial ring enhancing lesions in correlation with MR spectroscopy. *JMSCR* 2018;6(01):32009–32016
- 30 Morales NM, Agapejev S, Morales RR, Padula NA, Lima MM. Clinical aspects of neurocysticercosis in children. *Pediatr Neurol* 2000;22(04):287–291
- 31 Marx GE, Chan ED. Tuberculous meningitis: diagnosis and treatment overview. *Tuberc Res Treat* 2011;2011:798764