



A Unique Case of Bilateral Traumatic Renal Artery Avulsion Treated with Endovascular Stenting

Mehreen Yousuff¹  Kimberley Ugodulunwa² Simon Travis¹

¹Department of Radiology, Nottingham University Hospitals Trust, Nottingham, United Kingdom

²Department of Interventional Radiology, University of Nottingham Medical School, Nottingham, United Kingdom

Address for correspondence Mehreen Yousuff, MBBS, BSc (Hons), FRCR, Department of Radiology, Nottingham University Hospitals Trust, Nottingham, United Kingdom (e-mail: mehreenyousuff@hotmail.com).

J Clin Interv Radiol ISVIR 2024;8:53–55.

Abstract

Keywords

- ▶ blunt abdominal trauma
- ▶ renal artery avulsion
- ▶ bilateral renal artery stenting

Traumatic renovascular injury secondary to blunt abdominal trauma is rare, especially cases involving renal artery avulsion. We present a unique case of bilateral traumatic renal artery avulsion that was successfully treated endovascularly with bilateral stenting and thrombectomy, resulting in a nephron sparing outcome and cessation of dialysis.

Introduction

Renal trauma accounts for approximately 1 to 5% of all trauma patients, the majority (80–90%) of which are secondary to blunt abdominal trauma.¹

We present a case of bilateral traumatic renal avulsion secondary to blunt abdominal trauma treated successfully via endovascular treatment and restoration of renal function, of which there has been no previous published literature.

Case Report

A 43-year-old man was crushed under a bus and presented to the emergency department as a trauma call. Trauma computed tomography (CT) demonstrated normal sized kidneys bilaterally, with poor parenchymal and renal artery enhancement with retroperitoneal hemorrhage, without active bleeding (▶ Fig. 1). His estimated glomerular filtration rate (eGFR) on arrival to hospital was 9. After a prolonged period of stabilization, he was referred to interventional radiology for revascularization.

A 5Fr C2 catheter was used to cannulate the renal arteries in turn via retrograde access from the right common femoral artery. Renal angiography demonstrated partial avulsion of the proximal right renal artery with nonenhancement of the renal parenchyma (▶ Fig. 2). On the left, there was contrast extravasation in the region of the mid renal artery with no enhancement of the distal renal arteries or renal parenchyma consistent with complete left renal artery avulsion (▶ Fig. 3). Using a 2.7 Fr Progreat microcatheter and a 0.014 Fathom guidewire, both renal arteries were selectively cannulated and stented with Atrium covered balloon expandable stents (Getinge) with restoration of bilateral renal enhancement. Check angiography subsequently demonstrated multiple filling defects within the segmental left renal arteries consistent with thrombus. This was then aspirated with adequate angiographic result (▶ Fig. 3).

The patient was then admitted onto intensive care and commenced on hemodialysis. The renal function slowly improved post-revascularization approximately 1 month after the procedure with the eGFR stabilizing at 49. The patient no longer required dialysis on discharge.

article published online
October 30, 2023

DOI <https://doi.org/10.1055/s-0043-1774799>.
ISSN 2457-0214.

© 2023. Indian Society of Vascular and Interventional Radiology. All rights reserved.

This is an open access article published by Thieme under the terms of the Creative Commons Attribution-NonDerivative-NonCommercial-License, permitting copying and reproduction so long as the original work is given appropriate credit. Contents may not be used for commercial purposes, or adapted, remixed, transformed or built upon. (<https://creativecommons.org/licenses/by-nc-nd/4.0/>)

Thieme Medical and Scientific Publishers Pvt. Ltd., A-12, 2nd Floor, Sector 2, Noida-201301 UP, India

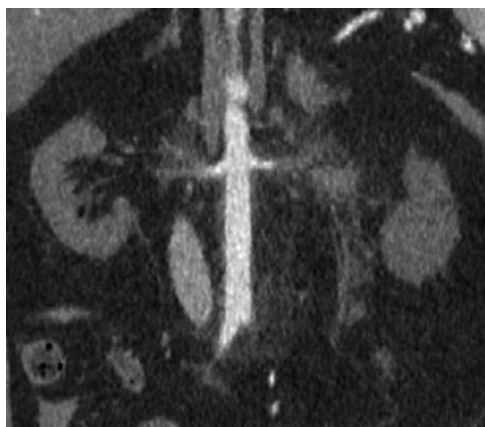


Fig. 1 Coronal reformat of dual bolus computed tomography showing abrupt nonopacification of the renal arteries bilaterally and poor renal enhancement.

Discussion

Renal artery avulsion secondary to blunt abdominal trauma is a rare and life-threatening injury. Contrast-enhanced CT is the current gold standard for quick identification of trau-

matic renal injuries therefore facilitating timely treatment. Traumatic renal injuries are traditionally classified into five grades and characterizes them based on increasing parenchymal and vascular injury.²

Our case discusses a patient with bilateral traumatic renal avulsion (American Association for the Surgery of Trauma (AAST) grade V) successfully treated endovascularly, of which there has been no published literature.

Renovascular injuries are associated with significant other injuries and a high mortality rate.³ Over the past decade, there has been a transition toward nonoperative management, including minimally invasive procedures. The main endovascular treatments offered in the context of trauma are embolization and stenting. The most important factor in preserving renal function is re-establishing blood flow as quickly as possible with the optimal revascularization time being between 6 and 12 hours.⁴ Surgical renal artery revascularization is associated with high complication rate; therefore, many surgeons would be dissuaded from attempting it.^{4,5} Endovascular stenting can be used in renal artery avulsion as described in a case of second-order renal artery avulsion treated with a stent graft resulting in a nephron sparing outcome.⁵

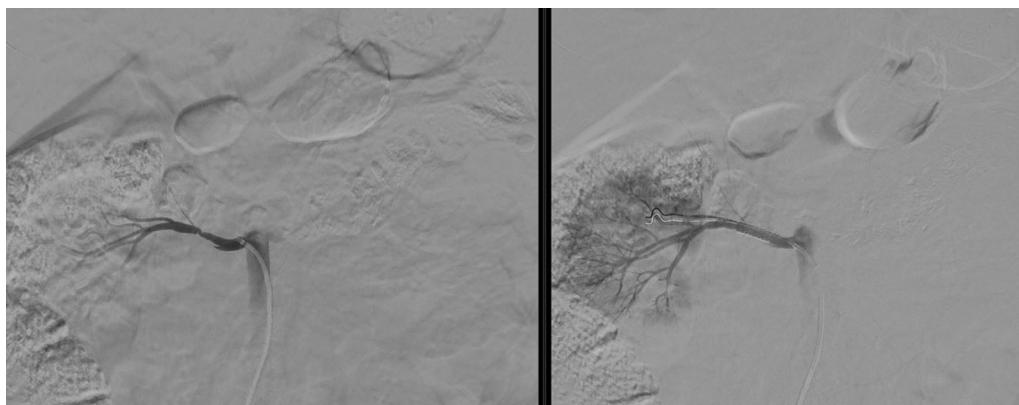


Fig. 2 Angiographic images demonstrating the vascularity of the right renal artery pre- (right) and post- (left)-endovascular stenting.

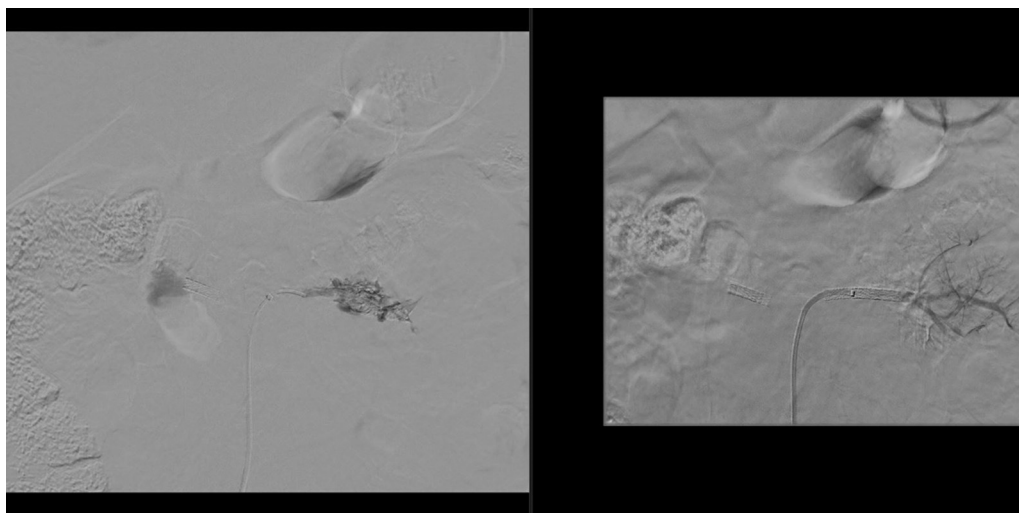


Fig. 3 Angiographic images of the left renal artery showing vascularity pre- (right) and post-stenting.

This case is unique as despite the prolonged time to treatment and subsequent thrombus formation within the second-order renal arteries, endovascular stenting was able to re-establish renal artery blood flow and allow the patient to be discharged without requiring lifelong dialysis.

Conclusion

Traumatic renal artery avulsion is a rare and life-threatening injury that requires prompt diagnosis and management. This case describes a good clinical outcome after endovascular stenting with cessation of renal dialysis and stabilization of renal function for bilateral renal artery avulsion despite a prolonged time before treatment.

Conflict of Interest
None declared.

References

- 1 Singh S, Sookraj K. Kidney Trauma. [Updated 2021 Jul 19]. In: StatPearls [Internet]. Treasure Island (FL): StatPearls Publishing; 2022 Jan-. Accessed August 16, 2023 at: <https://www.ncbi.nlm.nih.gov/books/NBK532896/>
- 2 Tinkoff G, Esposito TJ, Reed J, et al. American Association for the Surgery of Trauma Organ Injury Scale I: spleen, liver, and kidney, validation based on the National Trauma Data Bank. *J Am Coll Surg* 2008;207(05):646–655
- 3 Santucci RA, Wessells H, Bartsch G, et al. Evaluation and management of renal injuries: consensus statement of the renal trauma subcommittee. *BJU Int* 2004;93(07):937–954
- 4 Spirnak JP, Resnick MI. Revascularization of traumatic thrombosis of the renal artery. *Surg Gynecol Obstet* 1987;164(01):22–26
- 5 Sangthong B, Demetriades D, Martin M, et al. Management and hospital outcomes of blunt renal artery injuries: analysis of 517 patients from the National Trauma Data Bank. *J Am Coll Surg* 2006;203(05):612–617