

# Post COVID-19 Large Vessel Vasculopathy in a Previously Healthy Young Male

Bingwen Eugene Fan, MRCP<sup>1,2,3,4</sup> Shravan Sadasiv Mucheli, MRCP<sup>3,4,5,6</sup> Yee Lin Tang, FRCPath<sup>3,4,7</sup>  
 Enming Yong, MRCS<sup>3,4,8</sup> Rinkoo Dalan, FRCP<sup>3,4,9</sup> Christine Cheung, PhD<sup>3,10</sup>  
 Barnaby Edward Young, PhD<sup>3,4,5,6</sup> David Chien Boon Lye, FRCP<sup>3,4,5,6</sup> Linfa Wang, PhD<sup>11,12</sup>  
 Chee Wah Tan, PhD<sup>11</sup> Kiat Hon Tony Lim, FRCPath<sup>13</sup> Christina Lai Lin Sum, MSc<sup>14</sup>  
 Christian Aledia Gallardo, MD<sup>1,3</sup> Dheepa Christopher, FRCP<sup>1,2,3,4</sup> Bernard Pui Lam Leung, PhD<sup>15,16</sup>  
 Xin Rong Lim, MRCP<sup>3,4,16</sup> Shiun Woei Wong, MRCP<sup>3,4,17</sup> Yew Woon Chia, FRCP<sup>3,4,17</sup>  
 Vanessa Cui Lian Chong, MRCP<sup>1,2,3,4</sup> and The COVID-19 Clotting and Bleeding Investigators

<sup>1</sup> Department of Haematology, Tan Tock Seng Hospital, Singapore, Singapore

<sup>2</sup> Department of Laboratory Medicine, Khoo Teck Puat Hospital, Singapore, Singapore

<sup>3</sup> Lee Kong Chian School of Medicine, Nanyang Technological University, Singapore, Singapore

<sup>4</sup> Yong Loo Lin School of Medicine, National University of Singapore, Singapore

<sup>5</sup> Department of Infectious Diseases, Tan Tock Seng Hospital, Singapore, Singapore

<sup>6</sup> National Centre for Infectious Diseases, Singapore, Singapore

<sup>7</sup> Department of Pathology, Tan Tock Seng Hospital, Singapore, Singapore

<sup>8</sup> Department of General Surgery, Tan Tock Seng Hospital, Singapore, Singapore

<sup>9</sup> Department of Endocrinology, Tan Tock Seng Hospital, Singapore, Singapore

Address for correspondence Bingwen Eugene Fan, MRCP, Department of Haematology, Tan Tock Seng Hospital, Singapore, Singapore (e-mail: Bingwen\_Eugene\_Fan@ttsh.com.sg).

<sup>10</sup> Institute of Molecular and Cell Biology, A\*STAR, Singapore, Singapore

<sup>11</sup> Programme in Emerging Infectious Diseases, Duke-NUS Medical School, Singapore, Singapore

<sup>12</sup> Singhealth Duke-NUS Global Health Institute, Singapore, Singapore

<sup>13</sup> Department of Pathology, Singapore General Hospital, Singapore, Singapore

<sup>14</sup> Department of Laboratory Medicine, Tan Tock Seng Hospital, Singapore, Singapore

<sup>15</sup> Health and Social Sciences, Singapore Institute of Technology, Singapore

<sup>16</sup> Department of Rheumatology, Allergy and Immunology, Tan Tock Seng Hospital, Singapore, Singapore

<sup>17</sup> Department of Cardiology, Tan Tock Seng Hospital, Singapore, Singapore

Semin Thromb Hemost 2024;50:660–663.

The rising incidence of thrombosis post-coronavirus disease 2019 (COVID-19)<sup>1,2</sup> places an increased burden on health care systems, as even young patients with prior asymptomatic severe acute respiratory syndrome coronavirus 2 (SARS-CoV-2) infection can suffer from delayed catastrophic thrombosis.<sup>3</sup> Mechanistically, post-COVID-19 thrombosis may arise from persistent thromboinflammation,<sup>4</sup> in turn arising from chronic hypercoagulability, endothelial dysfunction, inflammation,<sup>5</sup> neutrophil extracellular trap formation, and platelet hyperactivation,<sup>6</sup> which are detectable in some patients who have recovered from COVID-19. Here, we present radiological and histopathological evidence of chronic, large vessel vasculopathy associated with recurrent post-COVID-19 thrombosis in a young male.

A healthy 35-year-old Indian male migrant worker, with no past significant medical history, presented to the National Centre for Infectious Diseases (NCID) with acute right lower

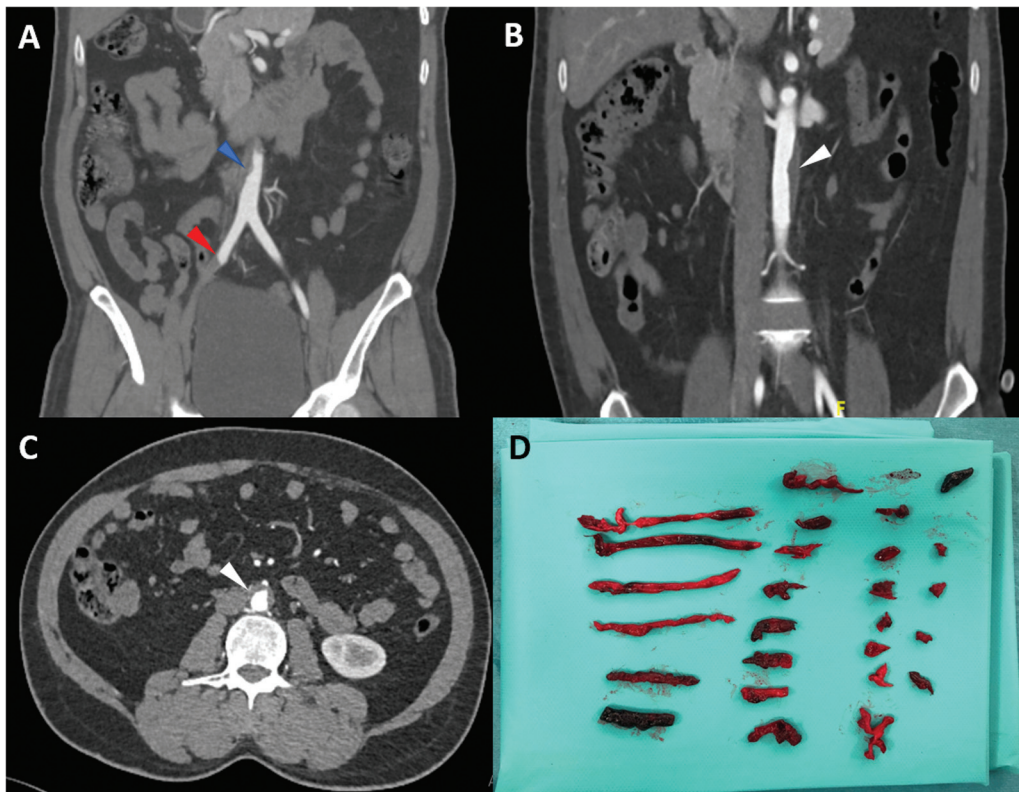
limb pain. Examination revealed a cold and pale right lower limb with nonpalpable pulses. Full blood count, prothrombin time, activated partial thromboplastin time (aPTT), liver function, renal function, HbA1c, and fasting lipids were normal. Additional hemostasis testing revealed hypercoagulability with raised fibrinogen of 6.0 g/L (1.8–4.5 g/L), factor VIII of 196% (60–150%), von Willebrand factor (VWF) antigen of 200% (56–200%), and D-dimer of 2.26 µg/mL (fibrinogen equivalent units; <0.5 µg/mL). aPTT clot waveform analysis (using Dade Actin FSL reagent; Siemens Healthineers, Singapore) demonstrated hypercoagulability with an elevated delta change of 76.6%, increased clot velocity (min1) of 7.39/s (2.85–6.65/s), increased clot acceleration, with elevated median Min2 of 3.48%/s<sup>2</sup> (0.46–1.08%/s<sup>2</sup>), and increased clot deceleration, with elevated median Max2 of 2.90%/s<sup>2</sup> (0.37–0.91%/s<sup>2</sup>). Thrombophilia screen, including tests for antiphospholipid syndrome and paroxysmal nocturnal hemoglobinuria, was

article published online  
September 25, 2023

Issue Theme Editorial Compilation  
—Part XV; Guest Editors: Emmanuel  
J. Favaloro, PhD, FFS (RCPA),  
Leonardo Pasalic, FRCPA, FRACP,  
PhD, and Giuseppe Lippi, MD

© 2023. Thieme. All rights reserved.  
Thieme Medical Publishers, Inc.,  
333 Seventh Avenue, 18th Floor,  
New York, NY 10001, USA

DOI <https://doi.org/10.1055/s-0043-1774793>.  
ISSN 0094-6176.



**Fig. 1** (A) Computed tomography image during first admission showing occlusion of the right external iliac artery (*red arrow*). Eccentric thrombus of the abdominal aorta (*blue arrow*) is the likely source of embolus. The rest of the aorta was normal with no mural thickening, calcification, dissection, or periaortic inflammation to suggest vasculitis. (B, C) Computed tomography aortogram performed on second admission (15 months from the first episode of acute ischemic limb) showing extensive irregular aortic wall filling defects and stenosis (*white arrows*). (D) Emboli from the common femoral artery (CFA)/profunda and superficial femoral artery.

negative, and antithrombin and protein C and S levels were also normal. Computed tomography (CT) angiogram revealed an occlusion of the right external iliac artery with propagation of the thrombus into the bifurcation of the popliteal artery. An eccentric thrombus of the abdominal aorta was the likely source of embolus (**Fig. 1A**). Electrocardiography did not reveal atrial fibrillation and transthoracic echocardiogram showed a normal ejection fraction with no thrombus. Nasopharyngeal SARS-CoV-2 polymerase chain reaction (PCR) swabs were negative, whereas blood SARS-CoV-2 IgG (Abbott Architect i System) returned positive, indicating recent infection by SARS-CoV-2. This was consistent with the patient's significant epidemiological risk with documented COVID-19 (ancestral, pre- $\alpha$  strain) amongst his dormitory contacts.

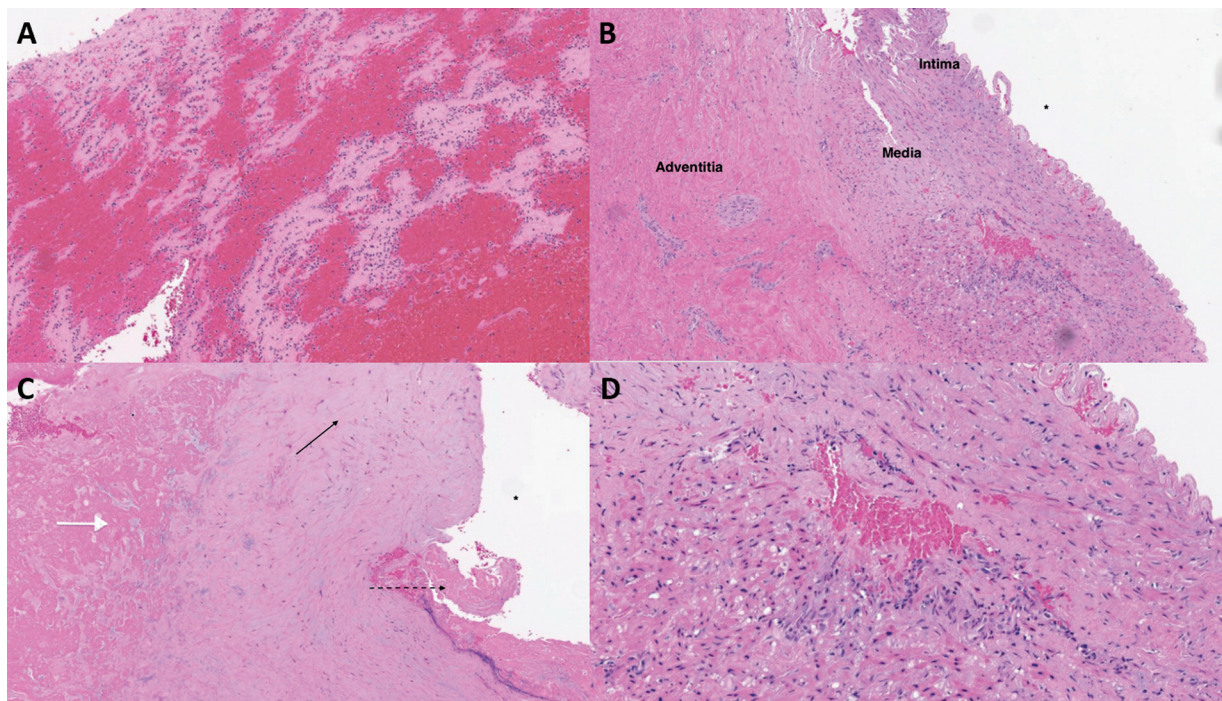
An emergency right femoral embolectomy and lower limb fasciotomy was performed. Intraoperatively, large amounts of soft but adherent clots were obtained from the common femoral artery (CFA), profunda femoris artery (PFA), superficial femoral artery (SFA), and proximally from the external iliac artery. Retrieved clots were sent to the National Public Health Laboratory for COVID-19 serology testing and returned negative. Postoperatively, the right foot dorsalis pedis and posterior tibial pulses were biphasic on Doppler but not easily palpable. The patient was anticoagulated with unfractionated heparin before switching to low-molecular-weight heparin and then onto apixaban 5 mg twice daily. He was followed up in the outpatient clinic and completed

6 months of apixaban. He then returned to India and defaulted his clinic follow-ups. However, 15 months from his first episode of ischemic limb, he presented to us again with right lower limb pain. Testing for COVID-19 with nasopharyngeal SARS-CoV-2 PCR swabs was negative. CT angiogram (**Fig. 1B, C**) revealed a stable complete occlusion of the right external iliac artery up to the proximal right CFA and interval development of occlusive disease from the mid/distal right SFA to the popliteal artery. This scan revealed irregular aortic wall filling defects and stenosis (**Fig. 1B, C**), which were not present on his CT angiogram a year earlier. An emergency right transfemoral and trans-popliteal embolectomy and bovine patch repair of femoral popliteal artery was performed. The surgical team was unable to pass a size 3 Fogarty catheter beyond 40 cm from right CFA; hence, a decision was made to perform a trans-popliteal arterial open embolectomy. Intraoperative findings revealed that the right CFA was inflamed and thickened with 70% narrowing of lumen noted, with the PFA origin obliterated by inflammatory changes and no back bleeding noted. Large amounts of fresh thrombi were thrombectomized distally (**Fig. 1D**) from the SFA with fair back bleeding noted. The popliteal artery was inflamed and thickened with 80% luminal narrowing. A size 3 Fogarty catheter was passed down to the level of the dorsalis pedis with minimal clot embolectomized. Postoperatively, the right dorsalis pedis signal was biphasic, while the right posterior tibial signal remained

absent. The postoperation day 1 CT aortogram and angiogram showed successful recanalization of the right external iliac artery, CFA, SFA and popliteal artery (P1 segment) with an incidental acute pulmonary embolism in the lobar and segmental branches of right lower lobe pulmonary artery. An ultrasound Doppler of the venous system in both lower limbs also revealed a deep vein thrombosis of the right superficial femoral vein and right common femoral vein. Postoperatively, he was continued on unfractionated heparin, then switched to low-molecular-weight heparin and transitioned to rivaroxaban 20 mg every morning, together with aspirin 100 mg and atorvastatin 40 mg daily. Histological examination of the right femoral artery thrombi (►Fig. 2A) showed an organizing hematoma with layering of red blood cells, inflammatory cells, and fibrin, while sections from the femoral artery showed expansion of the media by accumulation of hyaline and myxoid material with fragmentation of the smooth muscle layers, with extensive transmural fibrosis (►Fig. 2B, C). There was also evidence of angiogenesis within the media (►Fig. 2D). The thrombi retrieved had no bacterial growth, on both aerobic and anaerobic cultures. Tissue from the femoral artery wall as well as thrombi tested negative for SARS-CoV-2 spike protein on immunohistochemistry and PCR testing.

Remarkably, the vasculopathy and vessel stenosis had developed within a span of less than 2 years in a previously healthy, young adult male with no cardiovascular risk factors, with preceding asymptomatic COVID-19 infection. We observed histological evidence of damage and scarring of the femoral arterial wall as evidenced by extensive fibrosis and

accumulation of fibromyxoid material within the media of the femoral arterial wall, angiogenesis, and thrombosis, as well as radiological findings of large vessel stenosis, which are likely arising from persistent endothelial dysfunction and hypercoagulability. Although we have no direct evidence that our case reflects the direct outcome of prior SARS-CoV-2 infection, the findings correlate with our previous study on recovered COVID-19 patients, with elevated inflammatory proteins (C-reactive protein [CRP]), endothelial markers (VWF antigen), and coagulation parameters (factor VIII, D-dimer, and hypercoagulability on clot waveform analysis).<sup>5</sup> Sykes et al performed a study evaluating biomarkers and the arterial histology of small gluteal vessels in a matched cohort of patients, 3 months after hospitalization for COVID-19 with risk factor-matched controls.<sup>7</sup> This showed similar findings of increased intercellular adhesion molecule 1, vascular cell adhesion molecule 1, peak CRP, and peak ferritin; VWF activity, factor VIII levels, and fibrinogen were increased at enrolment; and factor VIII remained persistently high at 28 to 60 days postdischarge. Gluteal small artery biopsy showed greater collagen abundance as well as enhanced vascular fibrosis and myosin light chain phosphorylation. In a case-control series evaluating the impact of SARS-CoV-2 on arterial stiffness and structure, Szeghy et al found higher carotid artery stiffness and aortic stiffness among young adults 3 to 4 weeks post-SARS-CoV-2 infection.<sup>8</sup> Coincidentally, we observed heavily fibrous plaques in the coronary arteries without a necrotic core or calcium deposition on intravascular ultrasound in post-COVID-19 ST-segment elevation myocardial infarction occurring 80 to 174 days after SARS-CoV-2



**Fig. 2** (A) HE  $\times$  4: section from the thrombus shows layering of red blood cells, inflammatory cells, and fibrin. (B) HE  $\times$  4: expansion of the media by accumulation of hyaline/myxoid material with fragmentation of the smooth muscle layers. There is also extensive transmural fibrosis. (C) HE  $\times$  4: accumulation of fibromyxoid material in the media (black arrow). The endothelium is ulcerated with fragmentation of the internal elastic lamina (dotted arrows). There seems to be dissection of blood and fibrin through the media (white arrow). (D) HE  $\times$  10: higher power showing expansion of the media by hyaline/myxoid material. Angiogenesis is present in the media.

infection.<sup>9</sup> The absence of SARS-CoV-2 spike protein in the thrombi and vessel wall in our case supports the hypothesis that persistent COVID-19 endothelial dysfunction is caused by an exaggerated immune response to previous viral infection, which results in indirect endothelial injury, coagulopathy, and platelet hyperactivation with resultant thrombosis, rather than chronic endothelial infection by SARS-CoV-2.<sup>10</sup>

Endothelial dysfunction remains the cornerstone in post-COVID-19-associated thrombosis, where chronic dysregulation of the endothelium can foster large vessel vasculopathy, even in previously healthy patients. Further studies are required to better characterize the mechanisms of chronic endotheliopathy, to identify patients at risk for persistent dysfunctional immune response and its vascular complications, and to establish therapeutic targets for effective medical treatment.

#### Ethical Approval

This study was approved by the National Healthcare Group Domain Specific Review Board (2020/01426): cross-sectional study of long-term endothelial, hematological, and cardiovascular complications after recovery from COVID-19.

#### Data Availability Statement

The data that support the findings of this study are available from the corresponding author upon reasonable request.

#### Patient Consent

Informed consent was obtained by the study team.

#### Author Contributions

B.E.F. had full access to all data and takes responsibility for the integrity of the data. Drafting of the manuscript: B.E. F., V.C.L.C.. Performing of laboratory tests: C.L.L.S., K.H.T.L., C.W.T. Acquisition, analysis, or interpretation of data and critical revision of manuscript for important intellectual content: all authors.

#### Funding

This work was supported by a National Healthcare Group-National Centre for Infectious Diseases (NHG-NCID) COVID-19 Centre Grant (COVID19 CG008).

#### Conflict of Interest

None declared.

#### Acknowledgments

The authors greatly appreciate the efforts of our fellow health care workers during the pandemic. Special thanks to Sysmex Corporation (Japan), Diagnostica Stago (France), and All Eightys (Singapore) Pte Ltd for their technical support.

#### References

- 1 Fan BE, Cheung C. Post COVID-19 arterial thromboembolism: a clear and present danger. *Semin Thromb Hemost* 2022;48(01): 112–114
- 2 Xie Y, Xu E, Bowe B, Al-Aly Z. Long-term cardiovascular outcomes of COVID-19. *Nat Med* 2022;28(03):583–590
- 3 Fan BE, Umapathi T, Chua K, et al. Delayed catastrophic thrombotic events in young and asymptomatic post COVID-19 patients. *J Thromb Thrombolysis* 2021;51(04):971–977
- 4 Nicolai L, Kaiser R, Stark K. Thromboinflammation in long COVID—the elusive key to postinfection sequelae? [published online ahead of print, May 11, 2023] *Thromb Haemost* 2023;21(08): 2020–2031
- 5 Fan BE, Wong SW, Sum CLL, et al; COVID-19 Clotting and Bleeding Investigators. Hypercoagulability, endotheliopathy, and inflammation approximating 1 year after recovery: assessing the long-term outcomes in COVID-19 patients. *Am J Hematol* 2022;97(07): 915–923
- 6 Wang SSY, Chee K, Wong SW, et al; COVID-19 Clotting and Bleeding Investigators. Increased platelet activation demonstrated by elevated CD36 and P-selectin expression in 1-year post-recovered COVID-19 patients. [published online ahead of print, Feb 13, 2023] *Semin Thromb Hemost* 2023;49(05): 561–564
- 7 Sykes RA, Neves KB, Alves-Lopes R, et al. Vascular mechanisms of post-COVID-19 conditions: Rho-kinase is a novel target for therapy. *Eur Heart J Cardiovasc Pharmacother* 2023;9(04): 371–386
- 8 Szeghy RE, Province VM, Stute NL, et al. Carotid stiffness, intima-media thickness and aortic augmentation index among adults with SARS-CoV-2. *Exp Physiol* 2022;107(07):694–707
- 9 Wong SW, Fan BE, Huang W, Chia YW. ST-segment elevation myocardial infarction in post-COVID-19 patients: a case series. *Ann Acad Med Singap* 2021;50(05):425–430
- 10 Nicosia RF, Ligresti G, Caporarello N, Akilesh S, Ribatti D. COVID-19 vasculopathy: mounting evidence for an indirect mechanism of endothelial injury. *Am J Pathol* 2021;191(08): 1374–1384