



Spring-Assisted Cranial Expansion for Multisuture Craniosynostosis: First Case Report from the Indian Subcontinent

Rajendra S. Gujjalanavar¹ Rajalaxmi Doddamani¹ Vybhav Deraje¹ Swaroop Gopal²

¹Department of Plastic Surgery, Sakra World Hospital, Bengaluru, Karnataka, India

²Department of Neurosurgery, Sakra World Hospital, Bengaluru, Karnataka, India

Address for correspondence Vybhav Deraje, MBBS, MS, DNB, Aesthetica Veda, 222/220/A, 2nd Floor, Above BMW Deutsche Motoren, Whitefield Main Road, Sadaramangala, Bengaluru 560048, Karnataka, India (e-mail: vybhavd84@gmail.com).

Indian J Plast Surg 2023;56:461–465.

Abstract

Keywords

- ▶ spring-assisted cranial expansion
- ▶ posterior vault expansion
- ▶ multisuture craniosynostosis

We present a first use case report from the Indian subcontinent of a 5-month-old child with multisuture craniosynostosis with raised intracranial pressure managed by spring-assisted cranial expansion followed by traditional fronto-orbital advancement and cranial vault remodeling. We emphasize the advantages of spring-assisted cranial expansion in extremely young infants with raised intracranial pressure over posterior vault distraction osteogenesis and open posterior vault remodeling.

Introduction

Spring-assisted cranial expansion is gaining traction around the world for selected cases of craniosynostosis like sagittal synostosis. For multisuture craniosynostosis, the treatment is usually tailored according to individual patient needs and situations. Children with multisuture craniosynostosis can develop raised intracranial pressure (ICP) and are also predisposed to develop Chiari I malformation due to underdevelopment of the posterior cranial fossa.¹ The traditional technique of fronto-orbital advancement and cranial vault remodeling can lead to massive blood loss and morbidity and best done after the age of 9 months to 1 year. Spring-assisted cranial expansion² is a technique that can focus on expanding the posterior vault of the skull without the above disadvantages and hence available as a tool even in early infancy when there is imminent or established raised ICP. We report a first use case of the spring-assisted cranial expansion technique

for multisuture craniosynostosis child in the Indian subcontinent.

Case Report

A 5-month-old male child (weight 6.5kg) with abnormal shaped head and prominent eyes presented to our outpatient clinic (▶**Fig. 1**). The child had turribrachycephaly, mild exophthalmos, closed anterior fontanelle, and a head circumference of 42 cm. There was no evidence of papilloedema. Computed tomography (CT) head showed multisuture craniosynostosis with overt signs of raised ICP like scalloping of cranial bones (▶**Fig. 2**), copper-beaten appearance, tight brain, shallow orbits, underdeveloped posterior cranial fossa, and Chiari I malformation. Craniosynostosis panel did not reveal any specific genetic abnormality.

A two-stage surgical plan was made. The first stage would involve expansion of the posterior cranial fossa using springs

article published online
October 6, 2023

DOI <https://doi.org/10.1055/s-0043-1774789>.
ISSN 0970-0358.

© 2023. Association of Plastic Surgeons of India. All rights reserved. This is an open access article published by Thieme under the terms of the Creative Commons Attribution-NonDerivative-NonCommercial-License, permitting copying and reproduction so long as the original work is given appropriate credit. Contents may not be used for commercial purposes, or adapted, remixed, transformed or built upon. (<https://creativecommons.org/licenses/by-nc-nd/4.0/>)
Thieme Medical and Scientific Publishers Pvt. Ltd., A-12, 2nd Floor, Sector 2, Noida-201301 UP, India

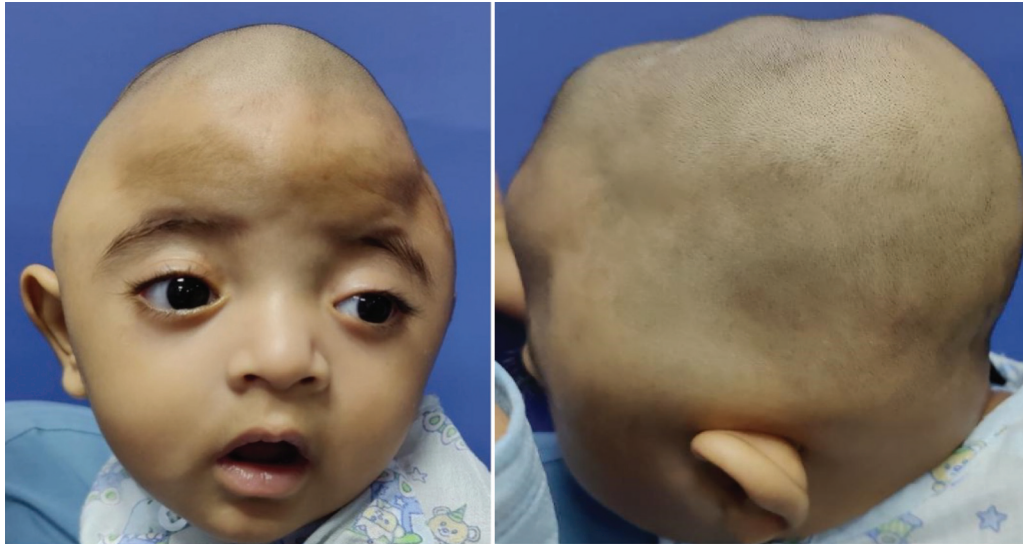

Fig. 1 Preoperative picture demonstrating turribrachycephaly and mild exophthalmos.

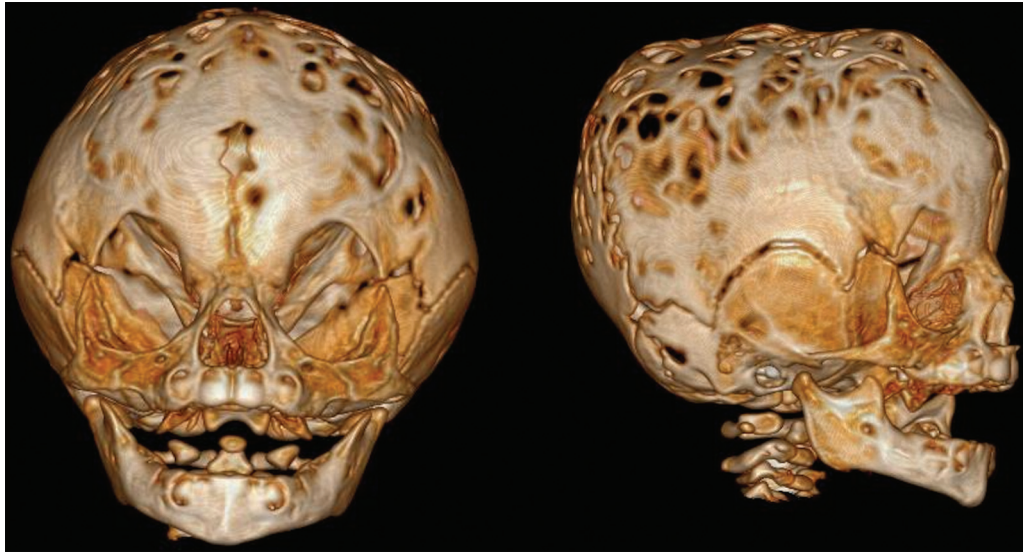


Fig. 2 Computed tomography scan showing multisuture craniostenosis with scalloping of cranial bones.

followed by a second stage (3 months later) involving removal of springs, fronto-orbital advancement, and cranial vault remodeling.

In the first stage, the child was taken up for strip craniectomy of bilateral lambdoid sutures and placement of springs. The child was placed in prone position after general anesthesia. Local anesthesia was infiltrated (mixture of 0.25% bupivacaine and 2% Xylocaine with adrenaline) into prospective incision lines. Two linear incisions (4cm each) were made on lambdoid sutures bilaterally. Subgaleal dissection was performed to create space and expose the skull over bilateral lambdoid sutures. Strip (2 cm) of periosteum was removed over the sutures. Burr holes were made and 2 cm strip of lambdoid suturectomy was done bilaterally. Stainless steel springs (Designed by Mr Owase Jeelani, Neurosurgeon, Great Ormond Street Hospital, UK and The Active Spring Company Limited, Essex, UK) were fabricated

locally in Bengaluru and sterilized by autoclaving (►Fig. 3). Two springs were placed in the gap of the strip craniectomy on both sides with the footplates of the springs nestling into precreated matched notches on the bone margin (►Fig. 4). This results in a transverse distraction force across the suturectomy site. The springs are placed with their opening ends facing each other and equidistant on either sides of the midline. Special care is taken to separate the dura from the under surface of the bone over the complete length of the sutures to avoid tearing of the dura during the expansion phase. Hemostasis was achieved. Scalp was closed in layers using Monocryl 5-0 sutures. A gentle compression head bandage was given. Blood transfusion was not required (total blood loss—50 mL). The baby was shifted to the ward after few hours of observation in the recovery room. The child was discharged on the second postoperative day.

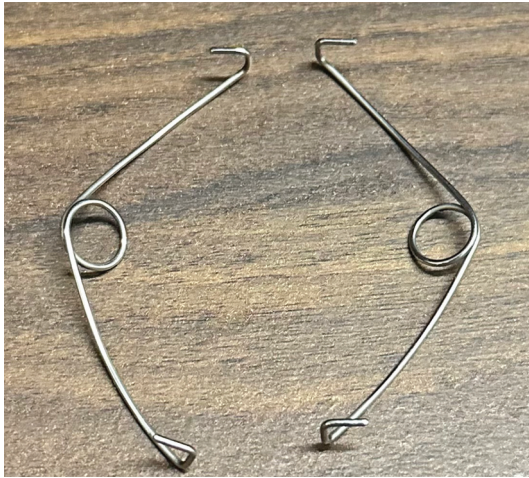

Fig. 3 Springs fabricated locally as per design physics shared by Mr Owase Jeelani & The Active Springs Company Limited, UK.

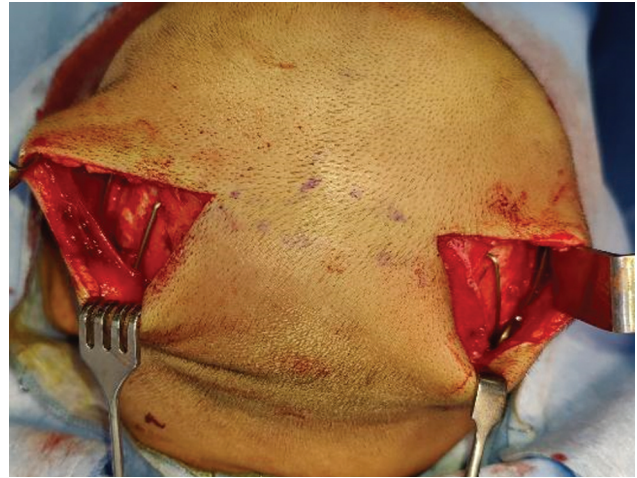


Fig. 4 Spring placement.

The wounds healed by 7th day without any complications. X-ray of the skull was performed to observe the spring position every 15 days (► **Fig. 5**). Significant improvement in posterior fossa volume was noted in the CT scan done 3 months later. The total intracranial volume increased from 736.96cc preoperatively to 982.52cc post spring-assisted cranial expansion (► **Fig. 6**). A resolution of Chiari I malformation was also noted. There was no papilloedema.

The second-stage surgery was performed 3 months after the first surgery. A standard fronto-orbital advancement and cranial vault remodeling was done along with the removal of springs (► **Fig. 7**). A reasonable aesthetic outcome (► **Fig. 8**) was achieved by the second surgery in addition to resolution of signs of raised ICP that was achieved by the spring-assisted cranial expansion.

Discussion

Management of multisuture craniosynostosis (nonsyndromic and syndromic) needs a “horses for courses”

approach. A protocol cannot be followed usually due to wide spectrum of the disease. Our patient was a 5-month-old male child with multisuture craniosynostosis with overt radiological signs of raised ICP. Performing a standard fronto-orbital advancement and cranial vault remodeling in such a small child has the danger of severe morbidity like bleeding, need for transfusions, and need for intensive care unit (ICU) stay and hence was not an option. When compared with the traditional anterior approach for cranial expansion, expanding the posterior vault leads to larger intracranial volume.³ Focusing on expansion of posterior cranial vault is a prudent approach also because the morphology is such that there is lack of development of posterior cranial fossa resulting in Chiari I malformation and raised ICP in these cases. To achieve this there are three main techniques, namely traditional open posterior vault remodeling, posterior vault distraction osteogenesis,⁴ and spring-assisted posterior vault expansion.²

We picked spring-assisted posterior vault expansion because of the following reasons:

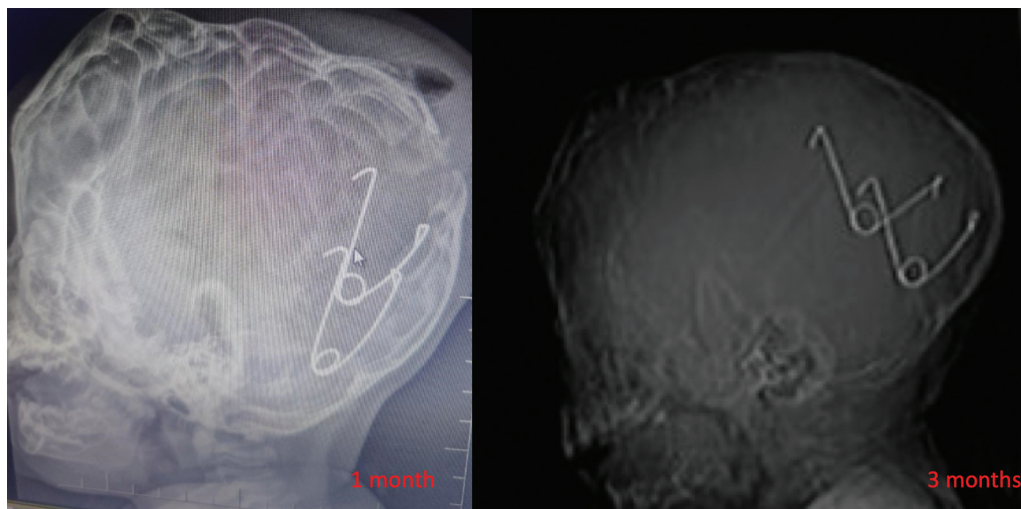


Fig. 5 X-rays showing spring opening at 1 and 3-month post-placement.

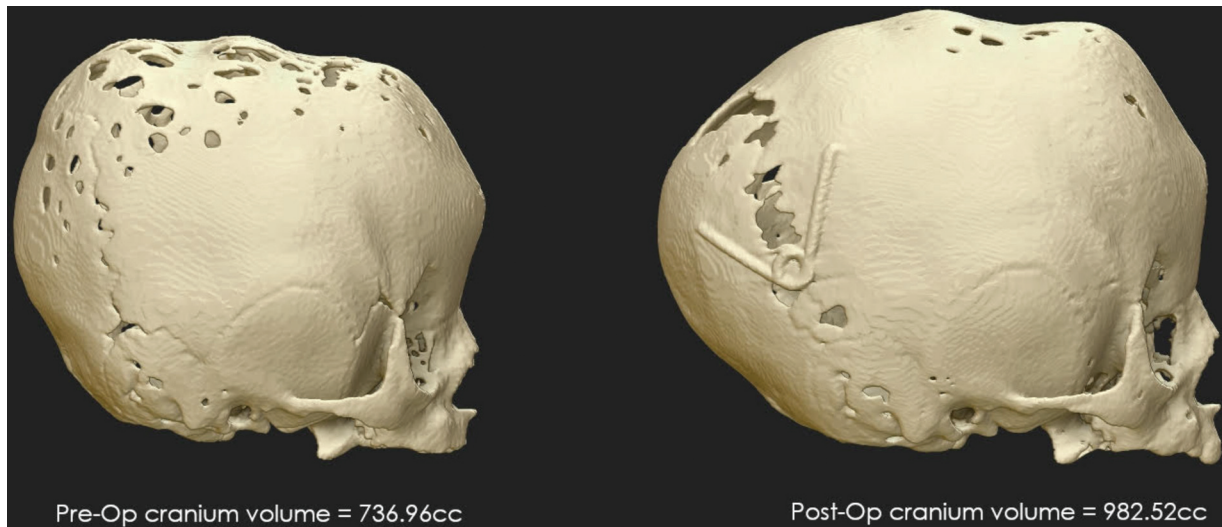


Fig. 6 Computed tomography scans showing 33.3% increase in intracranial volume (predominantly expansion of posterior vault).

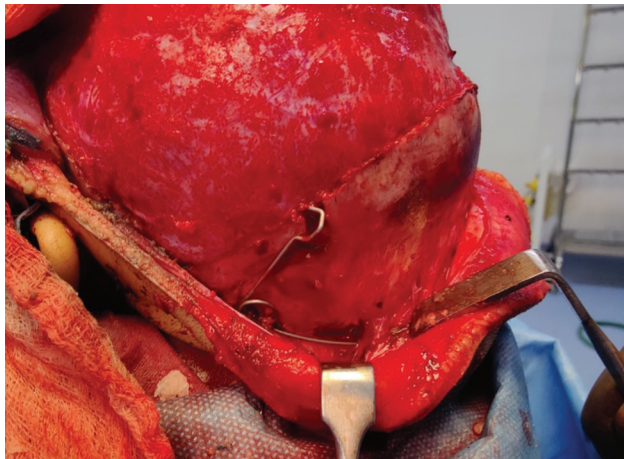


Fig. 7 Spring removal during second-stage surgery.

1. The child was young (5 months) and fragile (weight—6.5kg). Performing an open posterior vault remodeling entails significant morbidity and blood loss and also has a high chance of relapse at that age.
2. Waiting until the baby achieves good body weight was not an option because of the established signs of raised ICP.
3. Achieving scalp wound closure is also a challenge after open posterior vault remodeling. Spring-assisted posterior vault expansion leads to gradual expansion followed by bone deposition in the expanded space that leads to lesser chances of relapse and easier soft tissue closure during surgery.¹
4. The CT scan showed significant thinning of the bone and scalloping. Placing a distractor (posterior vault distraction osteogenesis) on such thin bone can lead to hardware failure.

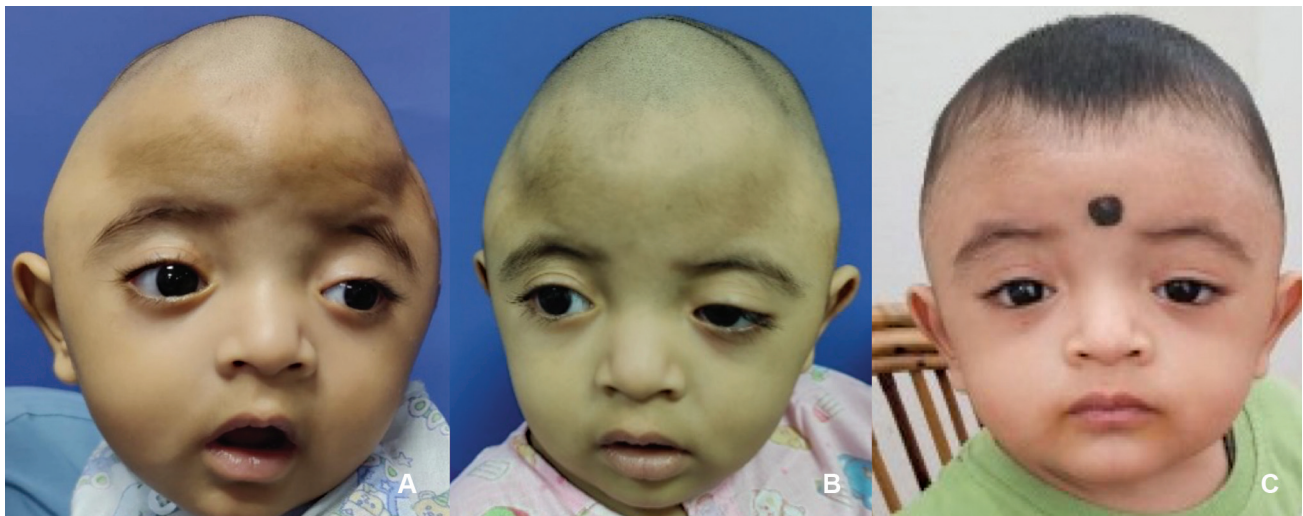

Fig. 8 (A) Preoperative, (B) post-spring-assisted cranial expansion, and (C) post-fronto-orbital advancement and cranial vault remodeling aesthetic outcome.

5. Springs are completely internal compared with a distractor that have a point of entry or exit. This means lesser chances of infection with springs when compared with distractors.⁵
6. The cost of fabrication of a pair of springs was INR 3,000, which in comparison to distractors (INR 1,00,000–3,00,000) is extremely economical. Both procedures require a second stage to remove hardware.

Spring-mediated cranial expansion used for the treatment of sagittal synostosis has been proved to be safe, efficacious, and minimally invasive.⁶ Spring-assisted cranioplasty was first described by Lauritzen et al,² where fused sutures are released and metal springs placed on the bony borders to widen the skull gradually in scaphocephaly. The same principles can be applied to multisuture craniosynostosis to expand the skull and reduce ICP and improve the morphology of the skull.

Spring-assisted cranial expansion allows us to intervene early when compared with traditional techniques.⁷ Early intervention has enabled us to treat the raised ICP without having to put the child through a major surgery in early infancy. This has also spared the forehead approach for the second stage 3 months later, when the child is more robust physiologically.

In comparison to the traditional techniques, spring-assisted cranial expansion has been found to be advantageous in many aspects like duration of surgery, blood loss, need for ICU stay, extent of cranial volume expansion, and hence is gaining traction in many craniofacial units around the world.^{1,8} There are no reports of springs usage from the Indian subcontinent to date and hence this case report is a unique first use case of spring-assisted cranial expansion for multisuture craniosynostosis.

The intracranial volume increased by 33.3% in our case that ensured timely resolution of raised ICP and reversal of Chiari I malformation. Larger and more structured studies are required to compare this with the outcomes that can be achieved with open posterior vault remodeling and posterior vault distraction osteogenesis like the ones by Nowinski et al.⁹

Complications of spring-assisted cranial expansion can be spring migration, spring breakage, dural tear, and cerebrospinal fluid leaks that are comparable to the ones associated with distractors.¹⁰ Springs can be applied in children with very thin bone too, since these springs are available in three different sizes and configurations (thickness, angulation).¹ There are high chances of hardware failure with distractors in thin bone. Another limitation of springs is the variable and uncontrollable vector of expansion and hence a close monitoring using X-rays is periodically required.

Limitation of our report is that we do not have long-term follow-up. We intend to collect more data from our future cases and design a credible study in the future.

Conclusion

Spring-assisted cranial expansion is an established mode of treatment for sagittal craniosynostosis. In multisuture craniosynostosis or syndromic craniosynostosis, as in our case, spring-assisted cranial expansion can be used in early infancy to relieve raised ICP, where distractors have contraindications. Further studies are required to establish spring-assisted cranial expansion as the gold standard for such cases, especially due to the economic advantages of springs over distraction in the low-middle income countries.

Conflict of Interest

None declared.

Acknowledgments

We would like to thank Mr Owase Jeelani, Neurosurgeon, Great Ormond Street Hospital, London, UK and The Active Springs Company Limited, UK for graciously sharing the physics and design of Springs; Mahalasa Medical Technology, Bengaluru, India, for help in fabrication of springs, and Osteo3D, Bengaluru, India, for help in three-dimensional models and volume metrics calculation.

References

- 1 Breakey RWF, van de Lande LS, Sidpra J, et al. Spring-assisted posterior vault expansion—a single-centre experience of 200 cases. *Childs Nerv Syst* 2021;37(10):3189–3197
- 2 Lauritzen CGK, Davis C, Ivarsson A, Sanger C, Hewitt TD. The evolving role of springs in craniofacial surgery: the first 100 clinical cases. *Plast Reconstr Surg* 2008;121(02):545–554
- 3 Choi M, Flores RL, Havlik RJ. Volumetric analysis of anterior versus posterior cranial vault expansion in patients with syndromic craniosynostosis. *J Craniofac Surg* 2012;23(02):455–458
- 4 Carlson AR, Taylor JA. Posterior vault distraction osteogenesis: indications and expectations. *Childs Nerv Syst* 2021;37(10):3119–3125
- 5 Jeelani N. Spring-assisted distraction: principles and techniques. In: Di Rocco DP C, Rutka J, eds. *Textbook of Pediatric Neurosurgery*. New York, USA: Springer; 2019:1–15
- 6 David LR, Plikaitis CM, Couture D, Glazier SS, Argenta LC. Outcome analysis of our first 75 spring-assisted surgeries for scaphocephaly. *J Craniofac Surg* 2010;21(01):3–9
- 7 Arko L IV, Swanson JW, Fierst TM, et al. Spring-mediated sagittal craniosynostosis treatment at the Children's Hospital of Philadelphia: technical notes and literature review. *Neurosurg Focus* 2015;38(05):E7
- 8 de Jong T, van Veelen ML, Mathijssen IM. Spring-assisted posterior vault expansion in multisuture craniosynostosis. *Childs Nerv Syst* 2013;29(05):815–820
- 9 Nowinski D, Di Rocco F, Renier D, SainteRose C, Leikola J, Arnaud E. Posterior cranial vault expansion in the treatment of craniosynostosis. Comparison of current techniques. *Childs Nerv Syst* 2012;28(09):1537–1544
- 10 Thomas GP, Wall SA, Jayamohan J, et al. Lessons learned in posterior cranial vault distraction. *J Craniofac Surg* 2014;25(05):1721–1727