



Complete Hydatidiform Mole with a Coexisting Viable Male Fetus Detected by Cell-Free DNA

Mackenzie Lemieux, BS¹ Lauren Kus, MD¹ Kali Stewart, MD¹ Mai He, MD, PhD²
Jackson Rowe, MD² Matthew Brady, MD¹ Katherine Bligard, MD¹ Megan Lawlor, MD¹
Jeannie Kelly, MD MS¹

¹ Department of Obstetrics and Gynecology, Division of Maternal Fetal Medicine, Washington University School of Medicine, St. Louis, Missouri

² Department of Pathology and Immunology, Washington University School of Medicine, St. Louis, Missouri

Address for correspondence Mackenzie Lemieux, BS, Washington University School of Medicine, 660 Euclid Ave., St. Louis, MO 63110 (e-mail: l.mackenzie@wustl.edu).

AJP Rep 2023;13:e49–e52.

Abstract

Keywords

- ▶ complete hydatidiform mole
- ▶ twin pregnancy
- ▶ molar pregnancy
- ▶ noninvasive prenatal testing
- ▶ SNP-based

Complete hydatidiform mole with coexisting fetus (CHMCF) is rare, and diagnosis is challenging due to limited data. Here, we present the case of a patient with noninvasive prenatal test (NIPT) resulting in “likely molar pregnancy” in the second trimester. Subsequent ultrasound confirmed a cystic appearing portion of the placenta. At 22 weeks, the patient delivered a demised fetus and two placentas. Pathology was consistent with CHMCF. This case is the first to show primary detection of a CHMCF with single-nucleotide polymorphism (SNP)-based NIPT prior to ultrasound identification. Our case suggests the use of SNP-based NIPT as an alternative noninvasive method to guide shared decision-making and clinical management for patients with this diagnosis.

A molar pregnancy with a morphologically normal coexisting fetus is exceedingly rare.¹ There exist no specific guidelines or larger series on the diagnosis and management of patients with this condition. Thus, case reports have been critical in providing information to guide patient education, shared decision-making, and medical management. Limited literature exists regarding use of single-nucleotide polymorphism (SNP)-based noninvasive prenatal test (NIPT) to evaluate suspected molar pregnancies^{2,3} and use of NIPT as a preliminary method to identify this rare condition and refer patients to specialized providers has not yet been described.

Case Report

A 27-year-old G4P2012 with no prior medical history presented to the emergency department at 7 weeks' gestation

with abdominal pain and bleeding. Her human chorionic gonadotropin (hCG) was elevated at 114,759 mIU/mL and ultrasound confirmed an intrauterine pregnancy; she was discharged with the diagnosis of threatened abortion. A subsequent first trimester dating ultrasound at 11 weeks was normal. The patient's SNP-based NIPT result at 12 weeks' gestation returned inconclusive; a repeat at 16 weeks' gestation resulted high risk for “a possible triploid, vanishing twin, or unrecognized multiple gestation” with “suspected complete paternal uniparental disomy (UPD), most consistent with a molar pregnancy.”

The patient was referred for maternal–fetal Medicine (MFM) consultation at 19 weeks. Detailed anatomy ultrasound demonstrated a normal-appearing fetus, a cervical length within normal limits, but a portion of the placenta appeared abnormal and cystic (▶**Fig. 1A**, ▶**Video 1**). The

received
July 7, 2023
accepted
August 8, 2023

DOI <https://doi.org/10.1055/s-0043-1774727>.
ISSN 2157-6998.

© 2023. The Author(s).

This is an open access article published by Thieme under the terms of the Creative Commons Attribution-NonDerivative-NonCommercial-License, permitting copying and reproduction so long as the original work is given appropriate credit. Contents may not be used for commercial purposes, or adapted, remixed, transformed or built upon. (<https://creativecommons.org/licenses/by-nc-nd/4.0/>)

Thieme Medical Publishers, Inc., 333 Seventh Avenue, 18th Floor, New York, NY 10001, USA

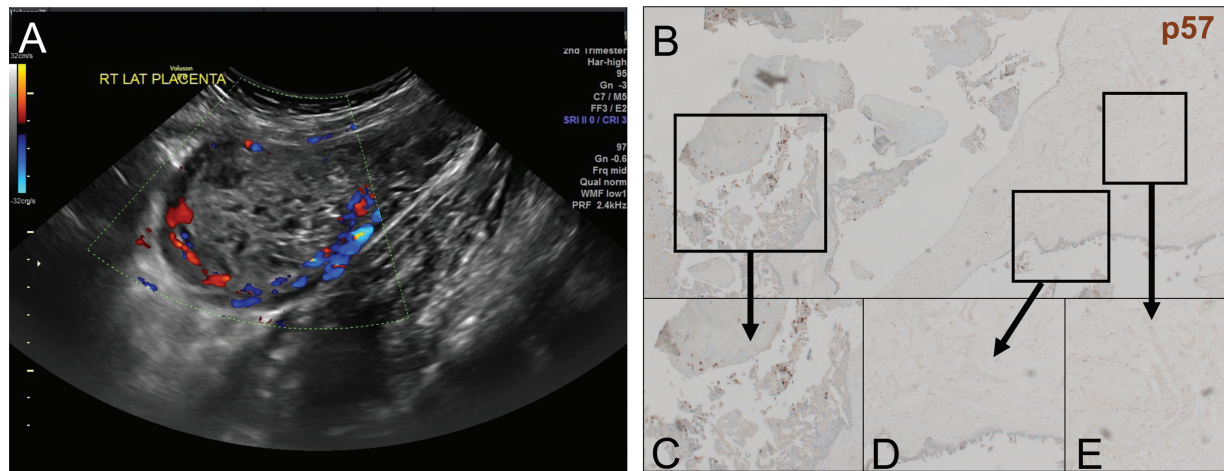


Fig. 1 (A) shows ultrasound findings at gestational age 19w3d highlighting the highly vascular molar-appearing tissue in the uterus. (B–E) Placental pathology from the molar appearing placenta. Enlarged chorionic villi are seen with empty stroma (cistern formation) with no fetal capillaries or fetal red blood cells. (B) shows a tissue sample with p57 stain. (C) shows extravillous trophoblasts stained p57 positive as an internal control. (D) shows villous cytotrophoblast that are p57 negative from the molar appearing villi. (E) shows villous stromal cells that are p57 negative from the molar appearing villi.

patient was counseled that these findings were concerning for a twin pregnancy with one normal fetus and a mole, and that continued pregnancy increased risks of postpartum hemorrhage, preeclampsia, and development of gestational trophoblastic disease. The patient elected to continue the pregnancy. Amniocentesis was performed for confirmatory genetic testing of the normal fetus, which showed normal chromosomal microarray and 46, XY karyotype. Placental biopsy was deferred after shared decision-making due to vascularity of the abnormal placenta and concerns for bleeding (►Fig. 1A).

Video 1

The video depicts posterior cystic placental tissue that appears separate from a normal appearing placenta, concerning for twin pregnancy with one normal appearing fetus and one molar pregnancy. Online content including video sequences viewable at: <https://www.thieme-connect.com/products/ejournals/html/10.1055/s-0043-1774727>.

At 22 weeks' gestation, the patient presented with vaginal spotting and abdominal pain. The cervix was fully dilated with bulging membranes in the vagina; ultrasound showed fetal bradycardia with an estimated fetal weight of 501 g. After periviability counseling, the patient declined caesarean but desired attempt at neonatal resuscitation. Her labor progressed and an intrauterine fetal demise was diagnosed intrapartum. She had an uncomplicated vaginal delivery of the demised fetus followed by spontaneously delivery of two intact placental masses. A transabdominal ultrasound was performed and although there appeared to be a thin endometrial stripe, a suction dilation and curettage was per-

formed to ensure complete uterine evacuation due to high suspicion for molar pregnancy.

Pathology findings were notable for one normal placenta and one placenta with multiple transparent vesicles of varying size that resembled a cluster of grapes and red-brown parenchyma with hydropic changes. Microscopically, disrupted placental tissue admixed with blood clot were notable for enlarged chorionic villi with empty villous stroma (“cistern formation”) with no fetal capillaries or fetal red blood cells. Tissue staining for p57, an imprinting marker of maternal expression and paternal imprinting, was negative in the cytotrophoblast and villous stromal cells within the chorionic villi, consistent with a complete hydatidiform mole (CHM; ►Fig. 1B–E). Given that the patient had two placentas, one of which diagnosed a CHM by pathology, and one of which supporting a normal fetus, the final diagnosis was a complete hydatidiform mole with coexisting fetus (CHMCF).

Overall, the patient had an uncomplicated postpartum recovery. We counseled the patient on weekly hCG monitoring until levels are undetectable, followed by monthly hCG levels for 6 months due to her diagnosis of a CHM.⁴ We also educated the patient on the importance of contraception during hCG trending so that detection of gestational trophoblastic disease is not impaired. So far, her hCG has been trended for over 2 months with a most recent value of 6.0 IU/L. The current plan is to continue trending until 3 consecutive values of less than 5.0 IU/L are achieved and then follow with monthly testing for 6 months.

Discussion

To the best of our knowledge, this is the first description of a case of CHMCF that was initially detected with SNP-based NIPT prior to ultrasound screening. The abnormal NIPT findings resulted in immediate referral to MFM for further evaluation and counseling. The combination of NIPT with

ultrasound allowed for sufficient management and clinical decision-making without the need to invasively sample the placenta and risk bleeding in an otherwise healthy patient. We feel that SNP-based NIPT is a safe and effective method to detect CHMCF and guide care for patients.

The incidence of molar pregnancy is 1 in every 100 pregnancies in the United States, with higher rates in developing countries.⁵ There are two types of molar pregnancies: complete and partial. A CHM occurs when either a single sperm or two sperm fertilize an egg without nuclear DNA, leading to 46,XX or 46,XY genotypes, all paternal. In a CHM, no embryonic tissue is present. In a partial hydatidiform mole (PHM), an egg is fertilized by multiple sperm leading to triploid (69, XXY) and possibly tetraploid (92, XXXY) genotypes. Fetal development may occur in these cases, but the fetus is often severely growth-restricted and nonviable.⁶ Between 1 in 20,000 and 1 in 100,000 pregnancies are affected by the coexistence of a CHM or PHM and a normal fetus¹ (→Fig. 2). The first description of CHMCF was in 1914 where the patient presented with severe hemorrhage and subsequent abortion of a 4-month-old fetus and two placentas, one molar and one normal.⁷

Antenatal complications and postpartum disease are very common in patients with CHMCF. In a recent meta-analysis of 244 cases of CHMCF, the rate of maternal complication was 80% including preeclampsia, vaginal bleeding, and hyperthyroidism.⁸ Of continuing pregnancies, only 50% were live

births with 78% of deliveries preterm. The clinical course our patient experienced was not uncommon, as the incidence of intrauterine fetal demise reported in the meta-analysis was 40%.⁸ While no maternal death was reported, gestational trophoblastic neoplasia (GTN) occurred in 34% of continued pregnancies. In a case series by Irani et al,⁹ of 14 total cases, antenatal complications occurred in all patients that delivered and the rate of GTN was 28%. Interestingly, compared to CHM, patients with CHMCF have an increased likelihood of developing GTN.¹

A literature review suggests that NIPT can successfully detect additional fetal haplotypes in genetically abnormal pregnancies.¹⁰ However, when an additional fetal haplotype is detected, only 11% are true triploidy, with other possibilities including vanished twin, pregnancy loss, viable twins, or molar pregnancy.¹¹ In our case, the NIPT result of “suspected complete paternal UPD” was consistent with diagnosis of a CHM. The ability of NIPT to accurately detect a CHM was first noted in 2015 by Simon et al.² In a case of suspected CHMCF or partial hydatidiform mole with coexisting fetus by early second trimester ultrasound, Gabra et al³ used NIPT as a secondary detection method to guide counseling and management as opposed to placental biopsy due to risks of bleeding from an abnormal placenta.³ Importantly, the risk of no growth or insufficient samples with placental biopsy has been reported as high as 40% in molar pregnancy cases.⁹ Similar to Gabra et al,³ we also chose to avoid placental

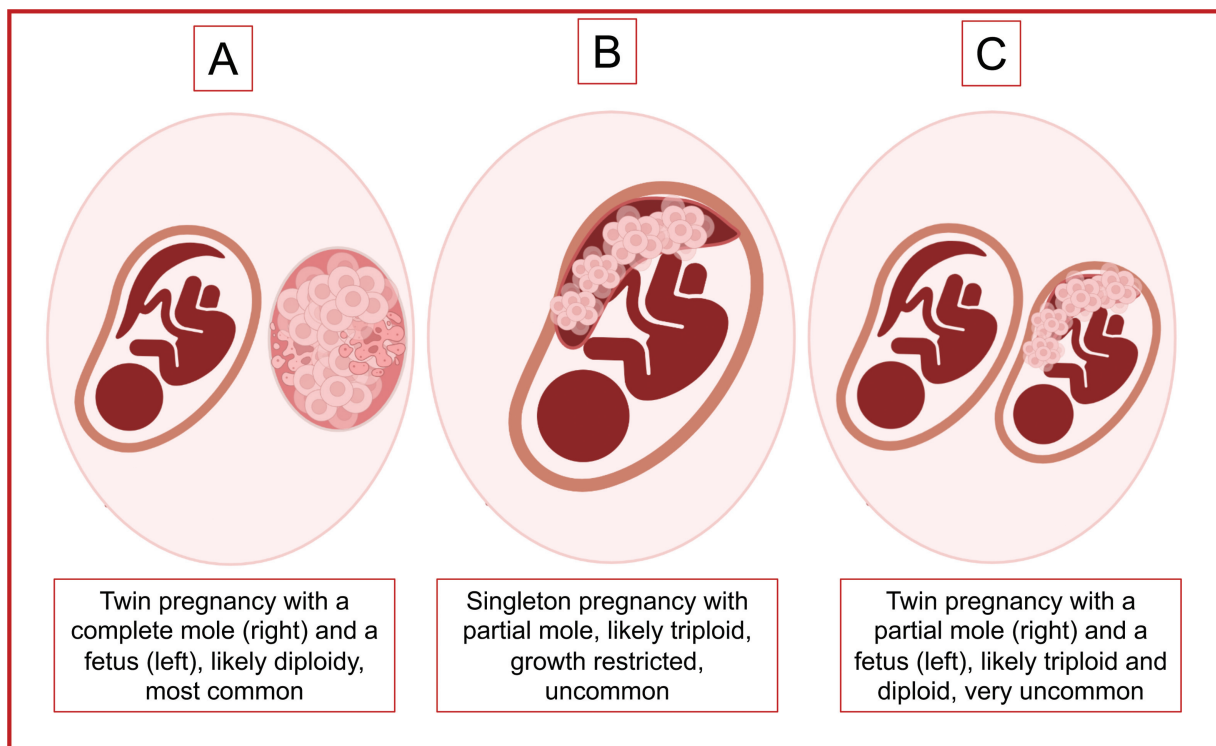


Fig. 2 Schematic showing three types of molar pregnancies with coexisting fetus. (A) is a depiction of a twin pregnancy with both a complete mole and a normal fetus. Of the three possibilities this is the most common, although overall this entity is very rare. Given the diploid fetus and diploid complete mole, all karyotypes in this entity should be diploid. (B) depicts a singleton pregnancy in which a partial mole is present with a likely growth restricted, non-viable, and triploid fetus. (C) is the least common of the three and depicts a twin pregnancy with one partial mole displaying some fetal parts and a co-twin normal fetus. This schematic was illustrated by author M.L.

biopsy due to the vascularity of the molar placenta and the fact that placental biopsy results would not have altered the clinical management of the pregnancy due to a strong patient preference for expectant management. While chorionic villus sampling and placental biopsy has been used for confirmation of triploidy,¹²⁻¹⁴ NIPT can offer a noninvasive method to guide counseling.

Conclusions

In summary, we present a case of a twin pregnancy with a normal male fetus and CHM initially detected by NIPT. Given the paucity of data about this rare pregnancy complication, shared decision-making between patient and clinicians should guide clinical recommendations. Our case adds to the limited literature and highlights that SNP-based NIPT may provide early suspicion of CHMCF, especially when first ultrasound signs of disease have not yet been detected and invasive diagnostic testing is not performed.

Conflict of Interest

None declared.

References

- 1 Steller MA, Genest DR, Bernstein MR, Lage JM, Goldstein DP, Berkowitz RS. Clinical features of multiple conception with partial or complete molar pregnancy and coexisting fetuses. *J Reprod Med* 1994;39(03):147-154
- 2 Simon AL, Su B, Demko Z, Rabinowitz M, Harmon ER, Gross SJ. Detection of complete molar pregnancy by single-nucleotide polymorphism-based non-invasive prenatal testing. *Ultrasound Obstet Gynecol* 2015;46(04):506-507
- 3 Gabra MG, Gonzalez MG, Bullock HN, Hill MG. Cell-free DNA as an addition to ultrasound for screening of a complete hydatidiform mole and coexisting normal fetus pregnancy: a case report. *AJP Rep* 2020;10(02):e176-e178
- 4 Wolfberg AJ, Feltmate C, Goldstein DP, Berkowitz RS, Lieberman E. Low risk of relapse after achieving undetectable HCG levels in women with complete molar pregnancy. *Obstet Gynecol* 2004;104(03):551-554
- 5 Braga A, Obeica B, Werner H, et al. A twin pregnancy with a hydatidiform mole and a coexisting live fetus: prenatal diagnosis, treatment, and follow-up. *J Ultrason* 2017;17(71):299-305
- 6 Creasy RK, Resnik R, Iams JD. *Creasy and Resnik's Maternal-Fetal Medicine: Principles and Practice*. 6th ed. Philadelphia, PA: Saunders/Elsevier; 2009
- 7 Luker G. Twin pregnancy; hydatidiform mole associated with normal ovum; abortion at four months. *Proc R Soc Med* 1914;7 (Obstet Gynaecol Sect):113
- 8 Zilberman Sharon N, Maymon R, Melcer Y, Jauniaux E. Obstetric outcomes of twin pregnancies presenting with a complete hydatidiform mole and coexistent normal fetus: a systematic review and meta-analysis. *BJOG* 2020;127(12):1450-1457
- 9 Irani RA, Holliman K, Debbink M, et al. Complete molar pregnancies with a coexisting fetus: pregnancy outcomes and review of literature. *AJP Rep* 2021;12(01):e96-e107
- 10 Curnow KJ, Wilkins-Haug L, Ryan A, et al. Detection of triploid, molar, and vanishing twin pregnancies by a single-nucleotide polymorphism-based noninvasive prenatal test. *Am J Obstet Gynecol* 2015;212(01):79.e1-79.e9
- 11 Kantor V, Jelsema R, Xu W, et al. Non-invasive prenatal screening for fetal triploidy using single nucleotide polymorphism-based testing: differential diagnosis and clinical management in cases showing an extra haplotype. *Prenat Diagn* 2022;42(08):994-999
- 12 Braga A, Uberti EM, Fajardo MdoC, et al. Epidemiological report on the treatment of patients with gestational trophoblastic disease in 10 Brazilian referral centers: results after 12 years since International FIGO 2000 Consensus. *J Reprod Med* 2014;59(05): (06):241-247
- 13 Arigita M, Illa M, Nadal A, et al. Chorionic villus sampling in the prenatal diagnosis of placental mesenchymal dysplasia. *Ultrasound Obstet Gynecol* 2010;36(05):644-645
- 14 Bovicelli L, Ghi T, Pilu G, et al. Prenatal diagnosis of a complete mole coexisting with a dichorionic twin pregnancy: case report. *Hum Reprod* 2004;19(05):1231-1234