

Micro-neurorrhaphy In peripheral Nerve Injuries

Prof. F.M. Tripathi
Dr. R.S. Kesari
Dr. A.K.Rai
Dr. U.Prakash
Prof. S. Mishra

KEY WORDS

MicroNeurorrhaphy, Secondary repair.

ABSTRACT

Results of Repair under magnification, of 30 cases of peripheral nerve injuries of different nerves at different site, are presented. Success rate of the repair depends upon the meticulous care taken during surgery.

INTRODUCTION

Peripheral nerve injuries are common in upper limbs due to various types of trauma. Majority of the them are managed primarily locally, without the nerve repair.

When patient comes late and the primary wound is repaired elsewhere then secondary repair needs to undertaken when scar settles and adjoining area becomes soft and supple. If skin is scarred it needs to be replaced by good quality skin flap before attempting the nerve repair. Use of nerve grafts may be done whenever the defect in the nerve is large and it is not possible to approximate ends. Repairs done under magnification give superior results.

MATERIAL AND METHOD

The present study is based on the observations of 30 cases of peripheral nerve injuries of different

sites and different sides of the body. All these cases were of old nerve injuries except 2 who had nerve injury per-operatively.

Electro-diagnostic studies were done in 18 cases and same was repeated after the repair of the nerve. Evaluation of the result was done by clinical tests and electro-diagnostic tests were done whenever practical. After the repair of the nerve, patients were also given physiotherapy and other orthopaedic appliances.

FOLLOW UP
Radial Nerve (Table 1) :

3 months follow up showed signs of sensory recovery. At 6 months sensory improvement was almost complete and there was progressive motor improvement. Same case at one year of follow up found to have normal motor function and sensations. One case of radial nerve injury was seen at 16 months interval and had about 80% sensations with normal motor function.

TABLE-1:
Follow-up of Radial Nerve Injury Patients.

Case No.	Date of Operation	3 Months	6 Months	9 Months	12 Months	15 Months	18 Months
3.	27.1.86	-	-	-	-	-	Sensory 80% Motor normal
25	19.5.88	M+ S+	M+ S- Normal				

Media Nerve (Table - 2)

Out of 5 cases of median nerve 3 came to follow up clinic. At 3 months post. op. two cases had sensory recovery. The one who had hyperaesthesia became normal after neurolysis. Electrical Burns patient did not do well.

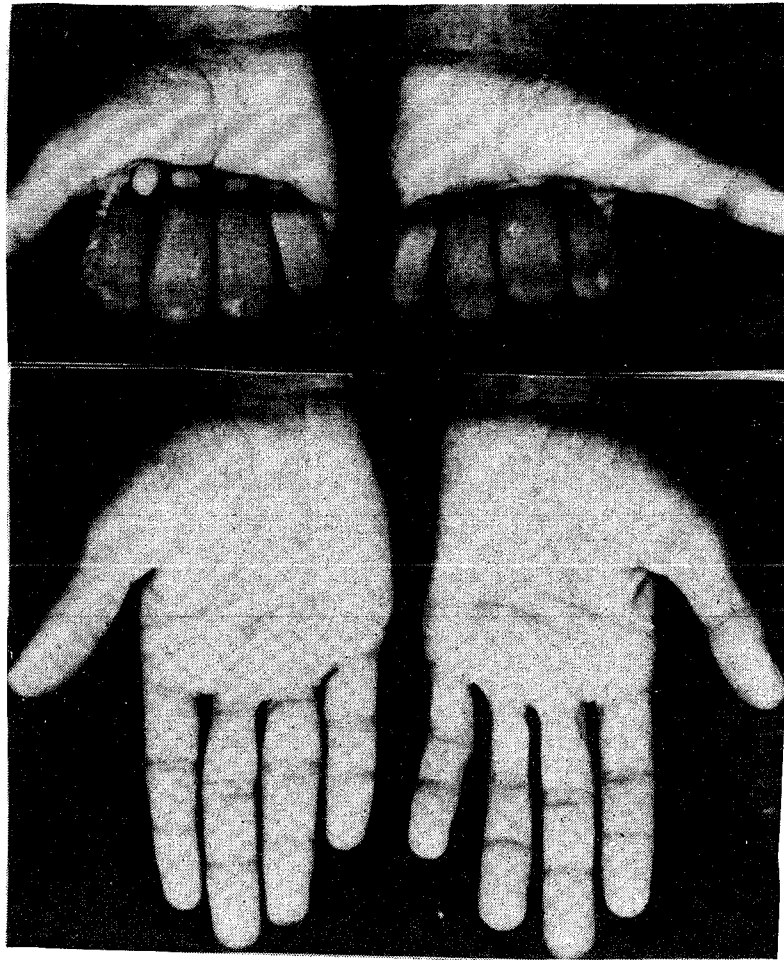
TABLE - 2
Follow up of Median Nerve Injury Patients

Case No.	Date of Operation	3 Months	6 Months	9 Months	12 Months
19.	14.3.87	-	-	-	-
20.	28.3.88	-	-	-	-
26	14.11.88	14.12.88 Sensory (+) Motor (-)	-	-	-
	25.1.89	Sensory (+) Motor (-)			
30	28.9.88	Hyperaesthesia (-)	-	-	-
16	15.2.88	Sensory (-) Motor (-)	-	-	-

Ulnar Nerve (Table - 3) :

In 3 months follow up, there was sensory improvement of 25% and motor improvement in the form of movement at MP, PIP and DIP joints, but clawing was still present. One case at 32 months follow up had 25% of sensory improvement but he had impaired motor improvement. Clawing was still present.

Photographs 1



Figures :

1. Regenerating repaired ulnar nerve at wrist (left hand)
2. Repaired ulnar nerve showing good fist grip (left hand)

TABLE - 3 :
Follow up of ulnar nerve injuries.

Case No.	3 Months	6 Months	9 Months	12 Months	32 Months
1	-	-	- Motor (+)	-	Sensory (+)
4	-	-	-	-	-
9	-	-	-	-	-
10	Sensory (+) Motor (+)	-	-	Sensory (+) Motor (+)	-
11	-	-	-	-	-
12	Sensory (+) - Motor (+)	-	-	-	-
15	-	-	-	-	-
28	-	-	-	-	-
29	-	-	-	-	-
33	-	-	-	-	-

Combined ulnar and median nerve lesions
(Table 4) :

Four cases of seven combined nerve injuries came for follow up after 3 months. Only one of them had mild sensory improvement and there was no motor improvement. Two patients had motor and sensory improvement at the end at 6 months. At the end of 18 months patient had 25% sensory improvement and motor improvement (Grade III) but clawing was still present.

One case with full sensory improvement and with grade IV power came at the end of 2 years. His nerve conduction velocity showed normal values but thenar and hypothenar wasting and mild clawing was present.

TABLE - 4 : Follow up cases of combined ulnar and Median nerve injury.

Case No.	3 Months	6 Months	9 Months	12 Months	15 Months	18 Months	21 Months	24 Months
2	-	-	-	-	-	-	-	Sensory(+) Motor (+)
6	-	-	-	-	-	Sensory(+) Motor (+)	-	-
8	-	-	-	-	-	-	-	-
13	Sensory (+) Motor (+)	-	-	-	-	-	-	-
14	Sensory (+) Motor (-)	Sensory (+) Motor (+)	-	-	-	-	-	-
22	Motor (-) Sensory (-)	Motor (+) Sensory (+)	-	-	-	-	-	-
27	Motor (-) Sensory (-)	-	-	-	-	-	-	-

Posterior Interosseous Nerve (Table 5) :

In first 3 months no motor improvement was seen. After next four months (7 months Post. Op.) patient was free from wrist drop and power at wrist was of grade IV.

TABLE - 5 :
Follow up of Posterior Interosseous Nerve.

Case No.	3 Months	6 Months	9 Months	12 Months	15 Months	18 Months
17	Motor(-)	-	Motor(+)	-	-	-

Digital Nerve in Index Finger :

Patient could not be followed up as he did not return.

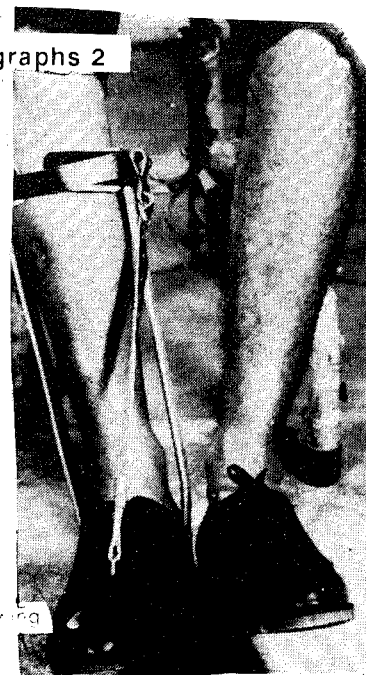Lateral Popliteal Nerve (Table 6) :

One case of lateral popliteal nerve injury came to follow up clinic after 3 months. There was sensory improvement of about 40% in distribution of the nerve. Motor improvement was of grade III.

The other patient with this nerve injury was seen

at 13 months. there was 25% sensory improvement and power at the ankle. Joint was of grade III with foot drop still persisting.

Photographs 2



Figures :

Improvement in foot drop following repair of lateral popliteal nerve.

TABLE - 6
Follow up of lateral Political Nerve Injury.

Case No.	3 Months	6 Months	9 Months	12 Months	15 Months	18 Months
24	29.988					
	Sensory(+)	-	-	-	-	-
	Motor (-)					
	27.10.88					
	Sensory (+)					
	Motor (+)					
5	-	-	-	-	Sensory (+)	-
					Motor (+)	

Digital Nerve In Sole

In first 3 months neither sensory nor motor improvement was noticed. At 6 months Tinels sign was positive only at the site of scar, suggesting obstruction in conduction. This was also confirmed by nerve conduction studies.

DISCUSSION

Results of repair were assessed in the follow up clinic by clinical tests and electrodiagnostic tests in some cases. P.J. Smith and G. Mott(1986) on peripheral nerve injuries advised that clinical tests including Tinel sign, although is simple and quick, can not be detected easily untill 2-3 months after injury. According to them two point discrimination test if correlated with electrical tests, an indication of regeneration can be obtained several months ahead of this clinical sign.

With the epineural repairs, Radial Nerve give satisfactory repair. Observation of other workers like J.Y. Alnot et al (1984) are similar to ours.

In median nerve, sensory recovery appears earlier to that of motor, within 3 months in 3 cases of present series. Median nerve being mixed nerve it becomes difficult to indentify the sensory and motor fibres separately but with the help of nerve stimulators and fascicular repair, results can be good. (Burke and-Brien 1976). Injuries of the median nerve at the wrist are repaired with funicular sutures and within 3 months, even the motor recovery can be expected much better (Grabb and his colleagues

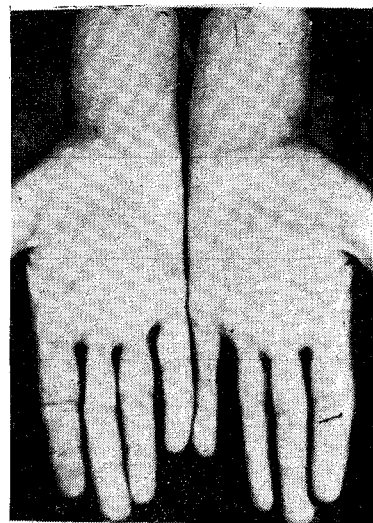
1970).

Suture also play important role. Finer the suture like 9/0, 10/0 better the results. O'Brien (1977). Buncke (1972) have advocated 7/0 or 8/0 nylon sutures to be inserted into the epineurium approximately 2 cms from each nerve end to act as tension relieving sutures.

Motor recovery in median nerve lesions is poorer as observed by Sunderland because small muscles of the hand atrophy very early if precautionary physio and occupational therapy measures are not instiuted well in time and regularly. As observed by other workers (Edwar, Almquist 1970) and the results are better in children than those in adults.

In case of ulnar nerve the sensory recovery is not as significant as in case of median nerve and motor recovery is also poorer because of degeneration of intrinsic muscles of the hand taking place quite early if no educational therapy is instituted.

Photograph 3



Figures :
Repaired ulnar nerve (Regeneration),
hypothenar atrophy, abducted little finger (in Right hand)

Though Jimmy A Chow et al (1986) have suggested that median and ulnar nerves have identifiable inner boundaries (inner epineurium) by which sensory to sensory and motor to motor group fas-

not indentify there boundaries even under magnification upto 6x.

Since area of sensory supply of ulnar nerve is less than of median in the hand, emphasis should be on for proper aligned repair of median nerve to achieve a good sensory hand. Motor functions can be regained by tendon transfers at a later date.

CONCLUSION :

In majority of the cases techniques of repair has been epineural with or without nerve graft under magnification. Results are good in radial nerve repairs over median and ulnar nerves. In lower limb results of repair of lateral popliteal nerve are satisfactory, although it takes a long time for the wrist drop and foot drop, to recover.

REFERENCE :

1. Alnot Jy, Oberlin Ch and Lahlou A. Radial Nerve Lesions of the Arm Series of 20 Nerve Repairs by Suture and Graft. *Act. Orthop. Quert.* 16 : 77-83, 1984.
2. Buncke JH. Digital Nerve Repairs. *Surgical Clinics of North America* 52: 1267-1285, 1972.
3. Burk P, O'Brien B, Mc C. A comparison of three techniques in Micro Nerve Repairs in dogs. *Hand* 10 : 135-143, 1978.
4. Grabb W.C., Bement S.I, Koepke G. H. and Green R. A. Comparison of Peripheral Nerve Suturing in Monkeys. *Plastic and Reconstructive Surgery* 46(1) : 31-37, 1970.
5. Millesi, Hanud. Reappraisal of Nerve Repair. *Surgical Clinics of North America* 61(2): 321-340, 1981 (April).
6. O'Brien B, Mc C. *Microvascular Reconstructive Surgery* Churchill Livingstone, Edingurgh, 1977.

AUTHOR'S NAME AND ADDRESS

1. Prof. F.M. Tripathi, Professor of Plastic Surgery (Microvascular Surgery)
2. Dr. R.S. Kesari, Junior Resident Surgery
3. Dr. A.K. Rai, Orthopaedic Surgeon
4. Dr. U. Prakash, Neurophysiologist
5. Prof. S. Mishra, Professor of Neurology

Division of Plastic Surgery,
Physiology and Neurology,
Institute of Medical Sciences,
Banaras Hindu University,
VARANASI - 221 005 (U.P.) INDIA.