

CLOSURE OF LUMBOSACRAL MENINGOMYELOCELE DEFECTS WITH TRIPLE RHOMBOID (LIMBERG) FLAPS

R. K. SHARMA

SUMMARY

The primary closure of the meningomyelocele defect is a challenging problem and calls for urgent closure of the defect. The author describes a method of closure of the lumbosacral meningomyelocele defect with the help of triple rhomboid flaps (Limberg). The defect is converted to a hexagon which incorporates three rhomboids, on which, three limberg flaps are designed utilising the laxity of available skin. The technique is simple to design and execute and is safe and reliable.

(Key Words : Meningomyelocele, Flaps)

The primary closure of the meningomyelocele defect presents a difficult problem and unless achieved, can lead to life threatening infection and neurological deterioration from the dessication of exposed spinal cord. Small defects can be closed directly by wide undermining. Paterson, (1959) estimated that in 25% of the patients of lumbosacral meningomyelocele, direct closure is not possible and some type of flap coverage is needed. In such patients we have used this technique of repairing the defect by local tissues.

Material and Methods

Between 1986-1988 a total of 24 patients were operated for meningomyelocele in the neurosurgery department of this hospital, and out of this 5 patients needed the local flap closure. All patients underwent surgical repair within a week of birth except one patient who came for surgery at the age of 20 years. The defects ranged from 4 cm² to 25 cm² in size.

Surgical Technique

Under endotracheal anaesthesia, the child is placed in prone position. The operative technique includes freeing of the neural elements from the cutaneous elements, developing sub-arachnoid space and achieving a water tight

closure of the dura. The skin defect now left is either circular or oval (Fig.1). This can be assumed to have a hexagonal shape, incorporating three rhomboids (Fig. 2). The availability of lax skin around the defect is assessed and even in very large defects, it is found to be so laterally and superiorly.

Three Limberg (rhomboid) flaps are designed in accordance with the availability of lax skin (Fig. 3). The skin is infiltrated with 1:200,000 adrenaline saline solution. After waiting for about 7-10 minutes the skin flaps are incised and the dissection is done in a relatively avascular plane just superficial to the muscle fascia. The occasional musculocutaneous perforators are electrocoagulated. The final closure of the defect is effected by transposing the three limberg flaps into the defect (Fig. 4). In defects which are not very large, even two limberg flaps are adequate for closure. There is minimal tension at the tip of flaps. (Fig. 5-8) show a series of photographs showing the design and execution of these flaps.

Discussion

A variety of techniques are available for the closure of myelomeningocele defects. Closure of small defects may be accomplished by

wide undermining and advancement of the local tissue, but chance of wound dehiscence is 41% (Luce and Walsh, 1985). The use of alloplastic material such as Teflon mesh has also been described (Winston, 1978). Early or delayed skin grafting after the dural closure does not provide durable soft tissue coverage and so is not recommended. For larger defects lateral relaxing incisions along the longitudinal axis of the trunk have been described. These in effect produce large bipedicle flaps (Habal, 1977). The amount of movement obtained with these bipedicle flaps is small and the tension on the suture line may be increased

with flexion and extension of spine (Cruz, 1983). Single rotation flap (Davies, 1977) or double rotation flaps (Patterson, 1959) have also been used, but these produce the secondary problem of flap donor defects in large lesions. More formidable operations may be indicated for larger defects, such as myoosseous flaps (Mustarde, 1968), the composite skin muscle flap (Desprez, 1971), the latissimus dorsi myocutaneous flap (Blaiklock 1981, McCraw, 1978), bilateral latissimus dorsi and trapezius musculocutaneous flap (McCraw, 1987). However these are extensive operations and the blood loss may average upto 300-5000 c.c.

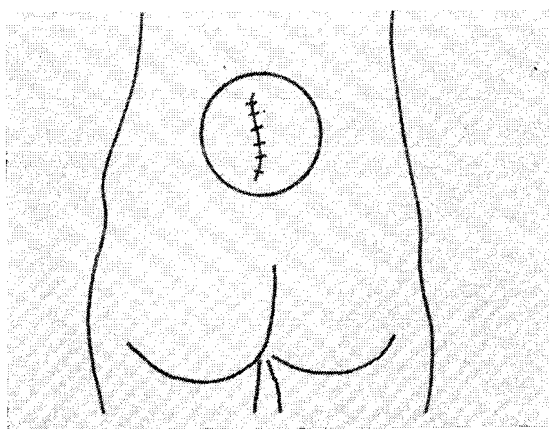


Fig. 1. Showing circular skin defect after the closure of dura.

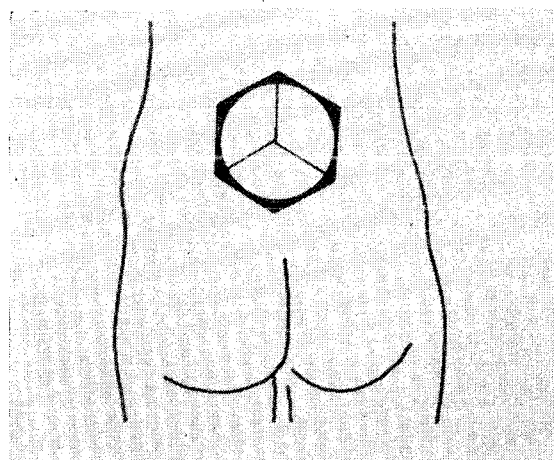


Fig. 2. Hexagon incorporating three rhomboids.

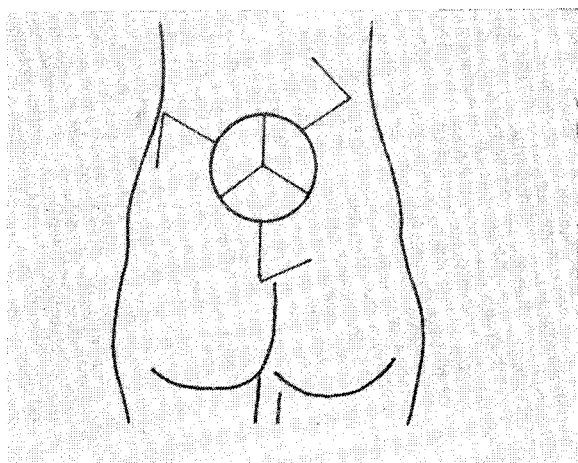


Fig. 3. Three rhomboid (Limberg) flaps designed.

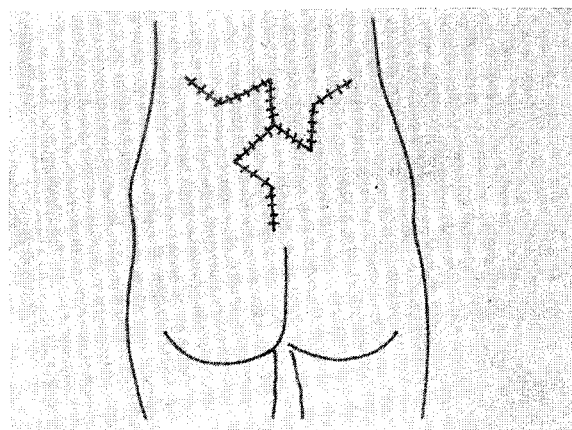


Fig. 4. Flaps transposed into the defect.

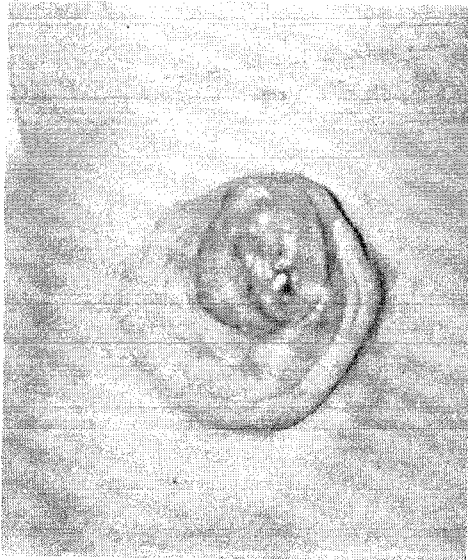


Fig. 5. Photograph showing a lumbosacral meningocele.

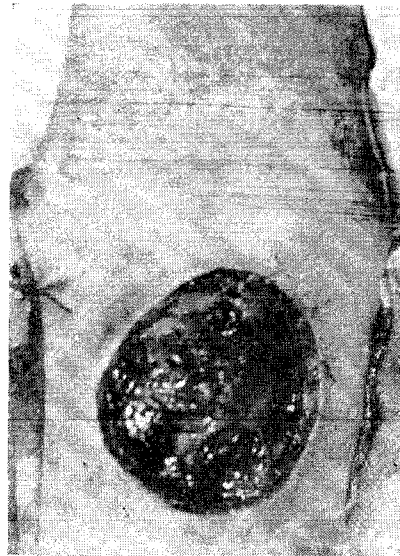


Fig. 6. Near circular skin defect after dural closure.

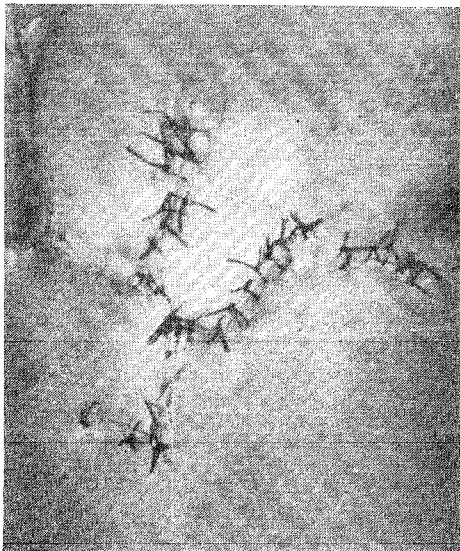


Fig. 7. Rhomboid flaps sutured in place.

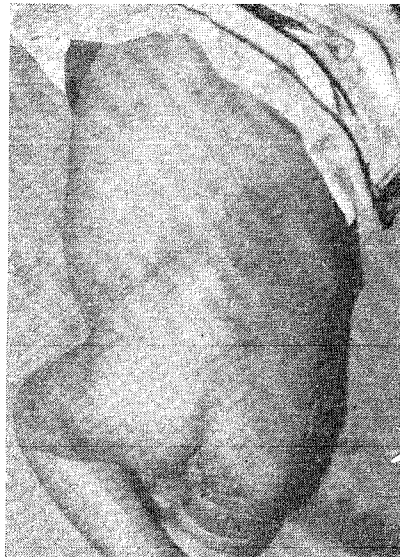

Fig. 8. Final results three months postoperative.

The concept of repairing skin defects with rhomboid flaps is not new, Limberg introduced it in 1946 (quoted by Jackson, 1985).

The use of triple rhomboid flaps in head and neck area is well established (Jackson, 1985), but its use in the closure of lumbosacral meningocele has not been employed so far. The triple rhomboid flap technique

offers the surgeon another alternative for the resurfacing of moderately large defects. Since most of the defects of lumbosacral meningocele are either circular or oval, these can easily be converted to a hexagon and three rhomboid flaps can be employed utilising the laxity of skin present superiorly and laterally. The advantages of this technique are, (i) it is

simple to design and execute, (ii) blood loss is minimal, (iii) there is lack of pin cushioning or trap dooring (Jackson, 1985). Further more, since this method employs cutaneous flaps which are strictly of random vascular pattern, it may be used in those situations where the skin may have already been undermined to secure access to paraspinous fascia for dural repair. In such cases, the use of myocutaneous flaps is precluded, since undermining dis-

rupts the musculocutaneous perforators that supply the skin territory of these flaps.

Our experience with patient using the triple rhomboid technique has been very encouraging. It has been very useful in closure of moderate to large sized defects without any complication with average blood loss of about 5-10 cc. This makes it a very safe and useful procedure in infants.

REFERENCES

1. BLAKLOCK, C. R., DERMITRIOV, E. L., RAYNER, C. R. W. : The use of latissimus dorsi myocutaneous flap in repair of spinal defects in spina bifida. *British Journal of Plastic Surgery*. 1981; 34 : 358.
2. CRUZ, N. I., ARIYAN, S., DUNCAN, C. C. AND CUONO, C. B. : Repair of lumbosacral myelomeningocele with double Z rhomboid flaps. *Journal of Neurosurgery*. 1983; 59: 714.
3. DAVIES, D. AND ADENDORFF D. J. : A large rotation flap raised across the midline to close the lumbosacral meningocele. *British Journal of Plastic Surgery*. 1977; 30 : 166.
4. DESPREZ, J. D., KIEHN, C. L. AND ECKSTEIN, W. : Closure of large meningocele defects by composite skin muscle transfer. *Plastic and Reconstructive Surgery*. 1971; 47 : 234.
5. HABAL AND M. B. VRIES, J. K. : Tension free closure of large meningocele defects. *Surgical Neurology*. 1977; 8 : 177.
6. JACKSON, I. T. : Local flaps in Head and Neck reconstruction. The C. V. Mosby Company St. Louis. 1985.
7. LUCC, E. A. AND WALSH, J. W. : Wound closure of myelomeningocele defect. *Plastic and Reconstructive Surgery*. 1985; 75 : 389.
8. LIMBERG, R. A. : Mathematical principles of local plastic procedures on the surface of human body. Leningrad, Govt. Publishing House for Medical Literature. 1946 (Quoted by Jackson, 1985).
9. MUSTARDE, J. C. : Reconstruction of spinal cord in severe spina bifida. *Plastic and Reconstructive Surgery*. 1968; 42 : 109.
10. MCCRAW, J. B., PENIX, J. O. AND BAKAR, J. W. : Repair of major defects of the chest wall and spine with latissimus dorsi myocutaneous flap. *Plastic and Reconstructive Surgery*. 1978; 62 : 197.
11. MCCRAW, J. B., PENIX, J. O., FREEMAN, B. G., VINGENT, M. P. AND WIRTH, F. H. : Soft tissue repair of myelomeningocele defects using bilateral latissimus dorsi and trapezius musculocutaneous flaps. *Annals of Plastic Surgery*. 1987; 18 : 147.
12. PATTERSON, T. J. AND TILL, K. : The use of rotation flaps following excision of lumbar myelomeningocele. An aid to closure of large defects. *British Journal of Surgery*. 1959; 46 : 606.
13. WINSTON, K. R., SCHUSTER, S. R. AND MICKLE, P. : Management of large skin defects in new born children with myelodysplasia : a new method. *Journal of Paediatric Surgery*. 1978; 13 : 303.

The Author

DR. RAMESH KUMAR SHARMA, M.S., M.Ch., *Diplomate National Board (Plastic)*, Assistant Professor, Department of Plastic Surgery, Postgraduate Institute of Medical Education and Research, Chandigarh.

Request for Reprints

DR. RAMESH SHARMA, Assistant Professor, Dept. of Plastic Surgery, P. G. I., Chandigarh-160012 (INDIA).