

## EPIGNATHUS

K. A. REDDY

### SUMMARY

*A rare case of epignathus of the premaxillary region associated with median cleft of the primary palate which was successfully operated is presented with review of literature.*

(Key Words: Tumours, Congenital-Jaws)

### Case Report

A female child aged 6 months was brought to us by the parents with a swelling in the midline of the upper lip associated with deformity of the lip and nose present since birth.

This child is the first born child after uneventful antenatal history and normal delivery, born to parents of consanguineous marriage.

On examination there was a swelling in the midline of the upper jaw associated with median cleft of the upper lip. The swelling was producing deformity of the nose, wide columella and bifid nose tip due to mechanical pressure.

The swelling was adherent to the premaxillary region of the upper jaw with notching in the midline. Hairs were seen growing from the anterior surface of the swelling. There was no intra-oral extension of the swelling. No other obvious congenital malformation could be detected.

### Treatment

Under general endotracheal anaesthesia the mass was completely excised upto the premaxilla. The median cleft of the lip was repaired in three layers incorporating a single Z-plasty. The bifid nose tip was repaired through

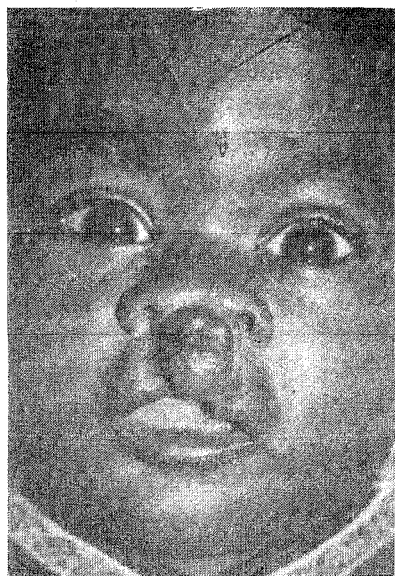

Fig. 1

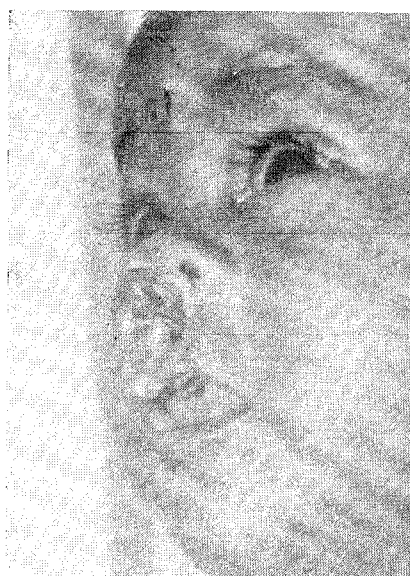

Fig. 2

Fig. 1 & 2. Pre-operative photographs showing the lesion with bifid nose tip and median cleft of the upper lip.

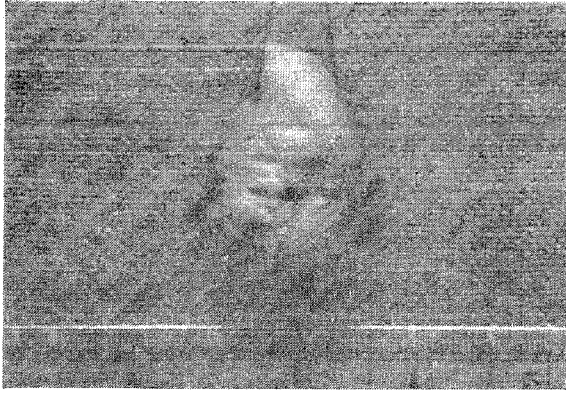


Fig. 3. Photograph of completely excised specimen.

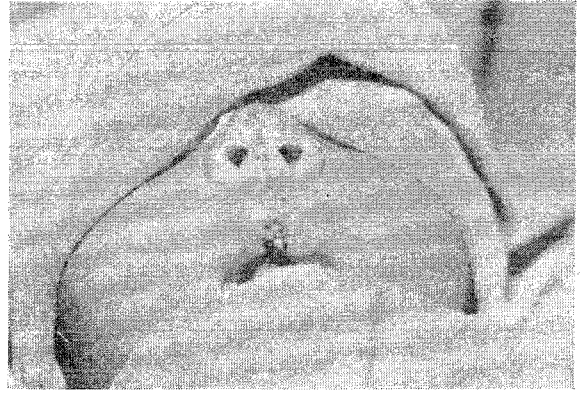


Fig. 4. Photograph immediately after excision and repair.

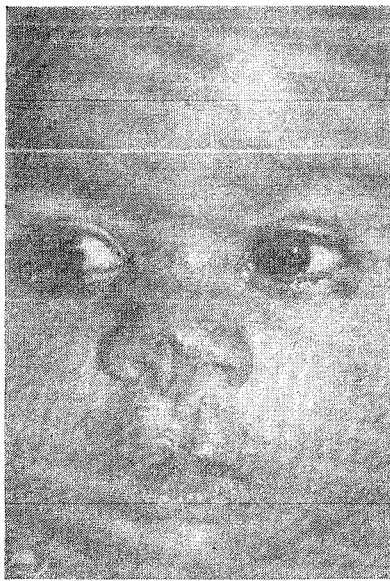

Fig. 5



Fig. 6

Fig. 5 & 6. Post-operative photograph after one week.

midcolumellar incision and by bringing the alar cartilages to the midline with 5/0 prolene sutures. The child had uneventful postoperative recovery. The sutures were removed on the 5th postoperative day and the patient was discharged on the 7th postoperative day.

#### Histopathology

*Macroscopic* : Lip like structure of  $2 \times 1\frac{1}{2} \times 1\frac{1}{2}$  cms. Cut section showed areas of gritty

feeling. Surface showed normal skin appearance with hair.

*Microscopic* : Section showed the structure of normal skin with underlying cartilagenous areas and fibromuscular tissue. No evidence of any infection or malignancy.

#### Discussion

Review of the available literature revealed only passing references and isolated case reports

of this extremely rare congenital abnormality (Mustarde, 1971; Stark, 1962; Yadava et al., 1983).

This is a teratoid lesion usually benign occurring in the midline of the upper or lower jaw, sometimes extending into the oral cavity.

It is more commonly seen in the premaxillary region. Due to mechanical factors, it is usually associated with median cleft of the lip and deformity of the nose, often with wide columella and bifid nose tip. Histopathological examination usually reveals, the ectoder-

mal, mesodermal and endodermal elements of embryonic nature.

### Conclusion

This case is reported because of its rarity and typical presentation. The treatment should always include the complete excision of the tumour upto the premaxilla and repair of the median cleft of the lip and associated nasal deformity. The operation should preferably be done as early as possible in order to avoid further increase in the size of the swelling and secondary deformity of the nose.

### REFERENCES

1. J. C. : MUSTARDE : Plastic Surgery in infancy and childhood, E & S Livingstone, Edinburgh and London ; 1971 : 109.
2. RICHARD B. STARK : Plastic Surgery, Harper & Medical Division, New York, 1962 : 379
3. V. N. S. YADAVA, D. S. SARDANA AND R. N. SRIVASTAVA : Epignathus (A case report), Indian Journal of Plastic Surgery, 1983; 1 : 42-43.

### The Author

DR. K. ANJI REDDY, M.S., (Gen.), M.S. (Plastic), *Professor of Plastic Surgery*, Rangaraya Medical College & Plastic Surgeon, Government General Hospital, Kakinada, Andhra Pradesh.

### Request for Reprints

DR. K. ANJI REDDY, M.S. (Gen), M.S. (Plastic), *Plastic Surgeon*, Syamalanagar-5th Lane, Guntur-6 (A. P.)