

MANAGEMENT OF SOFT TISSUE INJURIES OF THE FACE*

GAUTAM BISWAS

SUMMARY

Maxillofacial injuries now account for a large segment of patients in the casualty. This being, because of the increase in high speed vehicular traffic. A study conducted for one year, in 1983, showed that out of a total of 411 patients treated, 40% were those of soft tissue injuries of the face. Management of these wounds, after noting their site, character and time following injuries, to obtain optimum results, were carefully assessed.

Gentle handling of tissues, using non reactive suture materials with accurate reorientation, gave the best results.

(Key Words : Soft tissue, Trauma face)

Soft tissue injuries of the face are usually relegated to the background not being given the importance they deserve. These wounds differ from those elsewhere because of the unique character of the facial skin, its rich vascularity and its aesthetic importance.

Though the management of these injuries are well documented (Lawson, V., 1982); (Millord, 1969). A reassessment of management procedures were undertaken to outline the protocol necessary to obtain optimum results.

Material & Methods

A study of major soft tissue injuries of the face constituting 40% of maxillofacial injuries from December, 1987 to December, 1988 was undertaken (Chart 1). The commonest cause being vehicular accidents, constituting 80% of the study group.

Principles of Management

- Primary management of airway, bleeding, shock and control of pain.
- Thorough examination of patient as a whole, to rule out other injuries eg. cervical injuries, head injuries or other major organ trauma.

- Clinical and radiological assessment to rule out underlying fractures, constituting 28%, in our study.
- Tetanus prophylaxis.
- Prophylactic antibiotics were given only to grossly contaminated and contused wounds, and those with human or animal bites.
- Definitive repair done for injuries upto 24 hours old, delayed primary closure for older wounds or those grossly contaminated or crushed, without any compromise on quality of repair. In case of delayed primary repair, a few tacking sutures to maintain the tissue in their position was all that was done initially.
- All repairs were done under operating room conditions.
- Local infiltrative anaesthesia with 1: 100,000 adrenaline was most commonly used. General anaesthesia was used if other associated injuries of facial fractures required operative intervention.
- Wounds were thoroughly cleaned with saline, a detergent solution was used to clean the intact skin only. Lavage of the wound with a syringe and 19G

*Paper Presented at the Annual Conference of Plastic Surgeons' Winter Meeting Delhi, 1988.

- needle was used, to disimpact particulate matter. For deeply embedded particles the tip of a No. 11 scalpel blade helped prevent traumatic tattoos (Millard, 1969).
- Management differed with the nature of the wounds. Stellate wounds were excised with the long axis of the ellipse conforming to the resting skin tension line (RSTL). Abrasions were treated with non adherent dressings. Lacerations were closed in layers with absorbable sutures placed in deep tissues and fine interrupted non absorbable monofilament sutures (5/0 prolene) for skin approximation. Exact anatomic orientation, with tension free closure was the aim.
 - In case of large areas of tissue loss, skin to mucosa closure or coverage of the raw area with a split skin graft was done. Definitive repair being deferred to a later date.
 - Priority of soft tissue repair was given to identification and repair of important structures—facial nerve, parotid duct, lacrimal canaliculi, canthal ligaments and levator palpebrae.

Observation

A total of 411 patients attended the casualty with faciomaxillary injuries from December, 1987 to December, 1988. Soft tissue injuries alone accounted for 40% (165) of the injuries (Fig. 3 & 4), with an incidence of 28% (116) of the injuries consisting of both soft tissue and fractures (Fig. 1 & 2). The rest 32% (130) were of fractures alone. High speed vehicular trauma was the chief cause of these injuries with slower speed vehicles (cycle, cart, tractor), fall from height, gunshot injuries, human and animal bites being the other culprits (Tab. 1). Patients were mostly males (85%). It was observed that cheek, lip and chin was the site which faced the major brunt of trauma (Chart 2). Forehead and eyelid trauma, commonly observed in windscreen injuries, constituted the next important group.

Discussion

Management of soft tissues injuries of the face require a careful emphasis to detail, with meticulous tissue handling, and perfect anatomical orientation.

Wound infection secondary to primary closure is dependent on bacterial contamination, which is dependent on the total number of bacteria present and not on the type of bacteria (Lawson, 1982). Soil contaminated wounds are highly susceptible to infection as clay has a heavy anionic charge and acts to inactivate leucocytes and neutralises certain bacterias (Barwick 1914).

Reducing wound contamination by hydraulic water jet principle using a 20cc syringe with a 19G needle has been found to generate 7 lbs./Sq. inch pressure and significantly reduce bacterial count. Deeply embedded particles are manually disimpacted, preventing traumatic tattoos.

Because of the rich vascularity of the face, debridement was kept to a minimum as even flaps with a tenuous connection survive. Atraumatic tissue handling with use of non reacting sutures gave better results. It has been reported that nylon and polypropylene suture were associated with a lower infection rate (Edlic, 1979).

In case of tissue loss, definitive reconstruction was deferred as primary reconstruction would compromise the results in an already contaminated and crushed wound.

Important structures were managed primarily. Facial nerve branches proximal to mid pupillary line were always repaired under magnification (Walton, 1982). Parotid duct and lacrimal canaliculi were repaired over a stent, maintaining the patency of the duct.

In patients with human or animals bites, management was modified because of high level of bacterial contamination. Conflicting clinical results in the management of bites range from minimal infection following primary closure without use of prophylactic antibiotics (Schultz, 1972) to 29% infection rate even with

the use of prophylactic antibiotics (Thompson, 1973). Thorough debridement with delayed primary closure gave the best results.

Results

A total of 165 cases of soft tissue injuries of the face were treated during one year (1987-1988) at the Post-Graduate Institute of Medical Education and Research at Chandigarh. High speed vehicular traffic has been responsible for majority of the accidents. Facial wounds can be managed primarily upto 24 hours of injury.

Table 1. Causes of soft tissue injuries

	No.
High speed vehicles (Car, Trucks, Scooters, Motorcycles)	196
Slow speed vehicles (Tractor, cycle)	137
Fall from height	57
Gun shot injuries	12
Human bites	2
Animal bites	7
Total	411

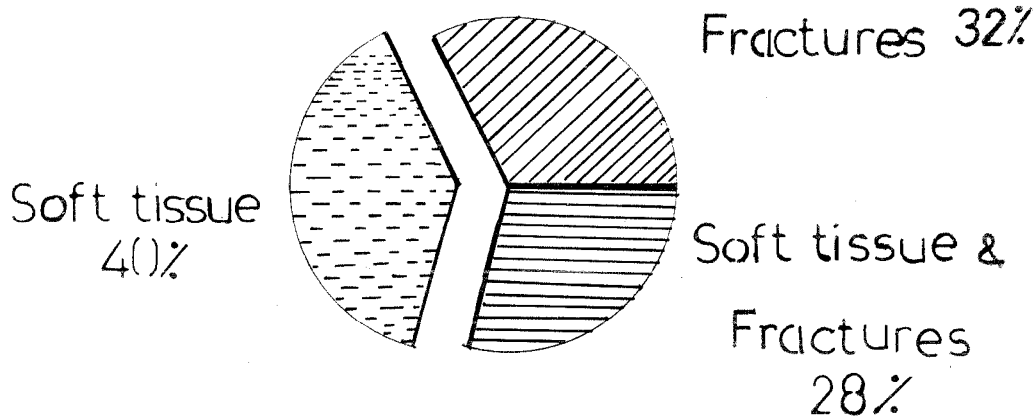


Chart 1-Breakup of Faciomaxillary injuries

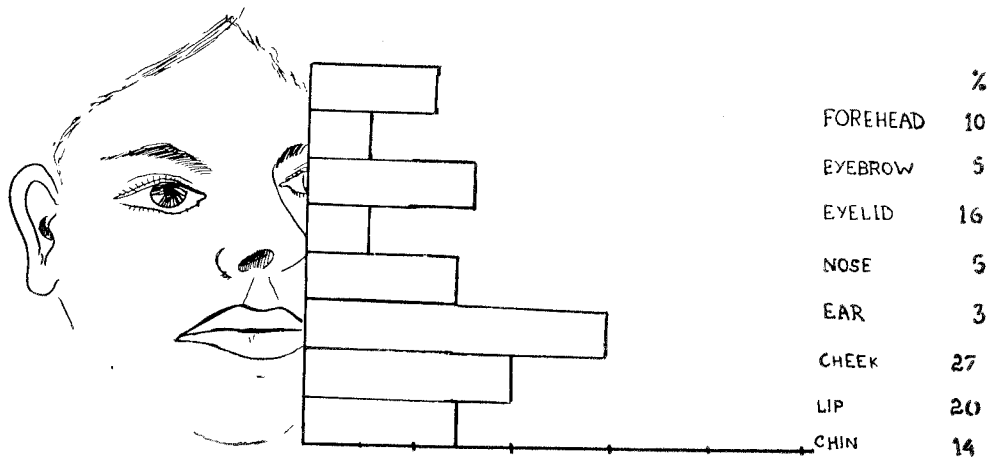


Chart 2-Incidence of soft tissue injuries at various sites.

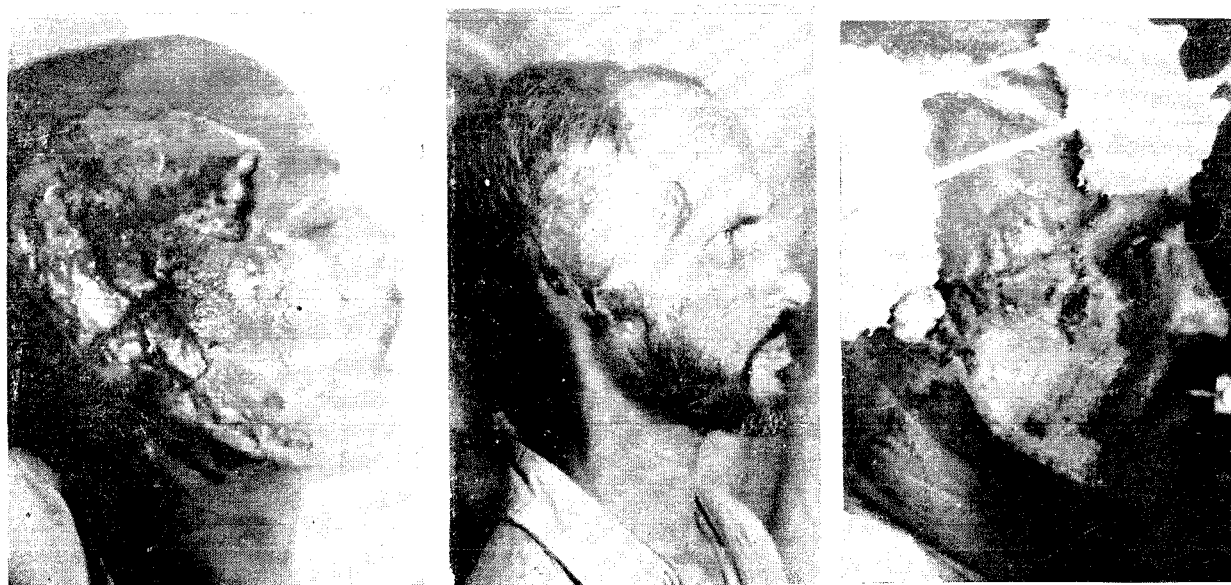

Fig. 1. Crush avulsion of temporal region with abrasion cheek with underlying Leforte II fracture maxilla. Split skin graft of temporal region. Abrasion healed with non adherent dressings.

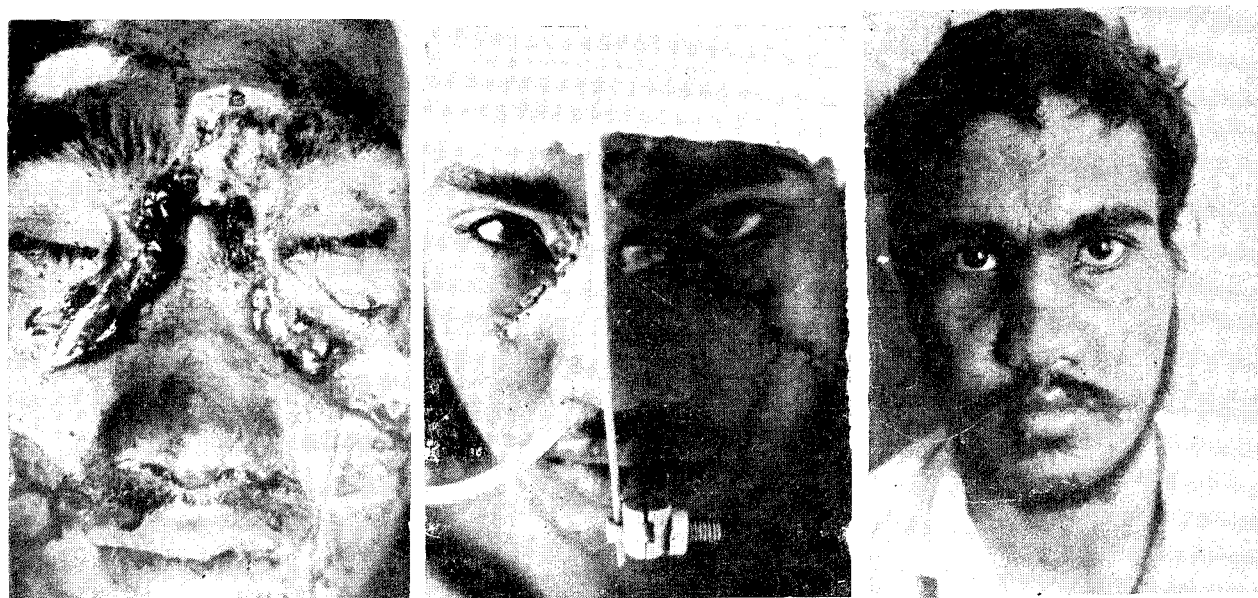

Fig. 2. Penetrating injury root of nose with disruption of medial canthal ligaments. Results following repair and cranio-maxillary fixation.

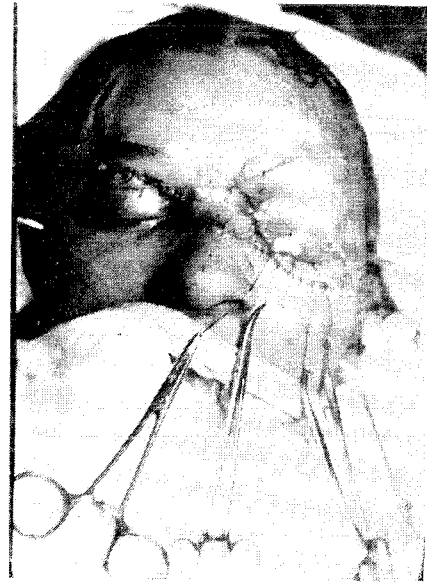
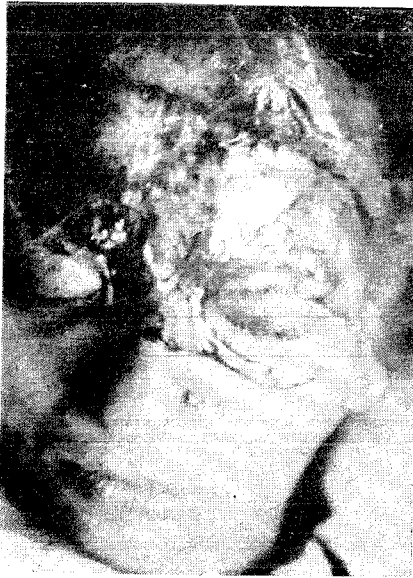
Fig. 3. Avulsion frontal region running along eyebrow, root of nose. Results following proper orientation of tissue.

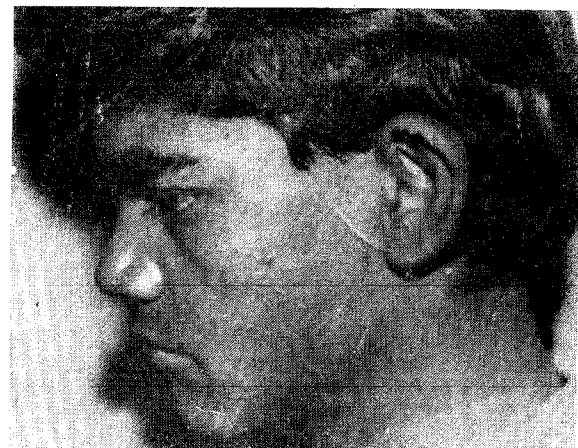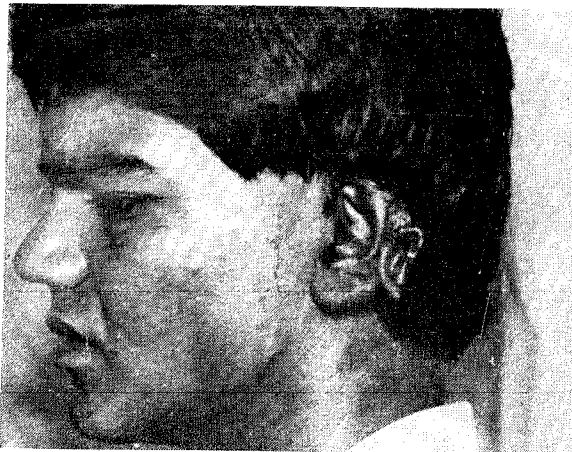


Fig. 4. Laceration helix of ear. Tissue attached with a flimsy pedicle. Repair in proper anatomical orientation.

Meticulous handling of tissues with the use of least reactive suture materials (5/0 prolene or monofilament nylon) with proper anatomical orientation in surface and depth, results in near normal form and function.

REFERENCES

1. BARWICK, W. S., KLEIN, H. : Soft tissue injuries of the face. Paediatric Plastic Surgery, C. V. Mosby, Co. 1984; 2 : 633-654.

2. DAVIS, P. K., SHAHEEN, O. H. : Soft tissue injuries of the face & scalp. Fractures of the larynx. Maxillofacial injuries N. L. Rowe, J. L. William, Churchill, Livingstone 1985; 1 : 184-213.
3. EDLIG, R. F., THACKER, J. G., BUCHANON, L., RODAHEAVEN, G. T. : Modern concepts of treatment of traumatic wounds. Advances in surgery. Chicago year book Med. Publishers, 1979; 13 : 169-197.
4. LAWSON, W. : Management of soft tissue injuries of the face. The otolaryngologic clinics of North America. Symposium on Plastic Surgery of the face. 1982; 15(1) : 35-48.
5. MILLARD, RALPH, JR. : Principle of soft tissue repair of facial injuries. Plastic & Maxillofacial trauma symposium. Nicholas G. Georgide, C. V. Mosby and Co. 1969; 1: 155-160.
6. MUSGRAVE, H. R. : Special problems of soft tissue repair of the eyelids, nose, lips, parotid gland and facial nerve and ears. Plastic & Maxillofacial trauma symposium. Georgide N. C., C. V. Mosby and Co. 1969; 161-712.
7. SCHULTZ, R. C., MC. MASTER, W. C. : The treatment of dog bite injuries especially those of the face. Plastic & Reconstructive Surgery. 1972; 49 : 494-500.
8. THOMPSON, H. G., SVITCK, V. : Small animal bites, the role of primary closure. Journal of Trauma. 1973; 13 : 20-23.
9. WALTON, R. L., HAGAN, K. F., PARRY, S. H., DELUCHI, S. F. : Maxillofacial trauma. The surgical clinics of North America. Trauma. 1982; 62(1) : 73-95.

The Author

DR. GAUTAM BISWAS, M.S., M.Ch., Deptt. of Plastic Surgery, P. G. I., Chandigarh-160012.

Request for Reprints

DR. GAUTAM BISWAS, Department of Plastic Surgery, P. G. I., Chandigarh-160012.