

Updates in Butterfly Graft Technique

Jonas R. Miller, MD¹  Joseph Madison Clark, MD, FACS¹

¹Division of Facial Plastic and Reconstructive Surgery, Department of Otolaryngology—Head and Neck Surgery, University of North Carolina at Chapel Hill, Chapel Hill, North Carolina

Facial Plast Surg 2023;39:621–624.

Address for correspondence Jonas R. Miller, MD, Division of Facial Plastic and Reconstructive Surgery, Department of Otolaryngology—Head and Neck Surgery, University of North Carolina at Chapel Hill, 170 Manning Drive, Campus Box #7070, Chapel Hill, NC 27599 (e-mail: Jonas_Miller@med.unc.edu).

Abstract

Keywords

- ▶ rhinoplasty
- ▶ butterfly graft
- ▶ dorsal preservation rhinoplasty
- ▶ nasal valve collapse
- ▶ spreader grafts

Nasal obstruction is a significant challenge greatly affecting individual quality of life. It is one of the most common presentations in the otolaryngology clinic, often persisting despite medical and, at times, surgical intervention. The butterfly graft has proven to be a veritable option addressing nasal valve collapse. Herein, we describe our most recent operative technique, highlight its application in ethnic rhinoplasty and revision cases, and discuss incorporation of dorsal preservation techniques in functional rhinoplasty.

Nasal obstruction remains a prevalent and significant problem greatly affecting individual quality of life. It can affect an individual's overall mood, energy, and interaction with the outside world.¹ Up to one-third of the population suffer from symptomatic nasal obstruction, where both structural and mucosal factors contribute to decreased nasal airflow.² Adequate nasal breathing, at a minimum, requires a patent nasal passage that can durably withstand resistance to airflow, intact mucociliary function, and intact thermoreceptors to sense adequate airflow.³

We have found that robust expansion of the patient's internal nasal valve (INV), in addition to correcting for any septal deviation, can significantly improve the patient's nasal airway. The INV is considered the narrowest corridor of the nasal airway, bordered by the dorsal septum medially and the caudal border of the upper lateral cartilage (ULC) superolaterally. Studies have shown that the INV can contribute to approximately two-thirds of anatomic nasal obstruction.⁴

To open the INV, first and foremost, an adequate septoplasty should be performed if a septal deviation is found to impact the nasal valve area. Additionally, multiple techniques have been employed to increase the cross-sectional area of the inferior corridor of the INV.⁵ Spreader grafts use harvested cartilage between the septum and ULC to statically increase the INV. However, this technique has shown mixed results clinically and in cadaveric models has shown sub-

optimal improvements in nasal airflow resistance.⁶ Additionally, spreader grafts are optimally used from straight septal cartilage but are challenging in revision cases where there is a dearth of primary septal cartilage. The butterfly graft (BFG) has proven durability in opening the INV in a reliable, repeatable manner in both primary and secondary rhinoplasty patients.^{7,8} In this article, we will review our current version of the basic surgical technique of the BFG, discuss implications in ethnic rhinoplasty and revision cases, and review incorporation of BFG in dorsal preservation rhinoplasty (DPR).

Operative Technique

First, attention is turned to the auricular graft harvest. Local anesthesia is injected into the supraperichondrial plane in the concha cavum, from the antihelical fold to the entrance of the external auditory canal, and in the subcutaneous layer posteriorly. An incision is then made along the antihelical fold, with a 5 to 8 mm limb extending toward the external auditory canal from the inferior aspect of the antihelical incision. The anterior portion of the cartilage graft is dissected in the supraperichondrial plane. The chondrotomy incision is made through the cartilage and the perichondrium, while palpating the posterior aspect to ensure complete release of the graft. The cartilage is then dissected along the posterior surface,

article published online
September 14, 2023

Issue Theme Functional
Rhinoplasty; Guest Editors:
Krista L. Olson, MD, and Sunthosh
Kumar Sivam, MD

© 2023, Thieme. All rights reserved.
Thieme Medical Publishers, Inc.,
333 Seventh Avenue, 18th Floor,
New York, NY 10001, USA

DOI <https://doi.org/10.1055/s-0043-1774332>.
ISSN 0736-6825.

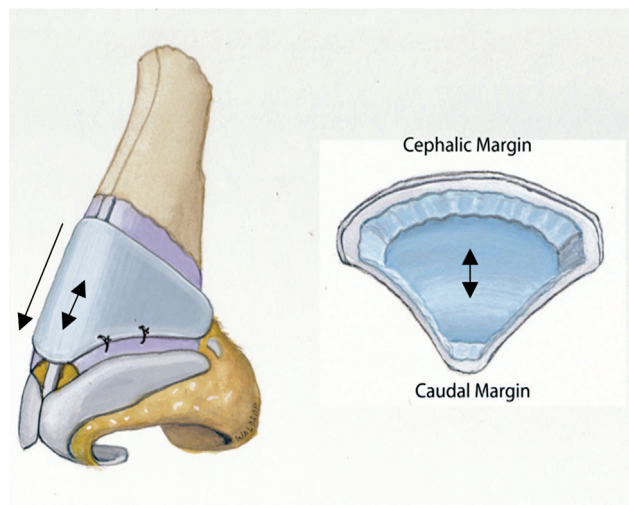


Fig. 1 Harvested butterfly graft demonstrating intact posterior perichondrium with scalloped edges. Long arrow indicates emphasis on placement of the graft as caudal as possible. Short arrow indicates emphasis on decreasing the cephalocaudal dimension as much as possible.

preserving the posterior perichondrium and ultimately the cartilage is delivered. A telfa bolster dressing is placed and removed on postoperative day 1.

Next, the auricular cartilage graft is carved for inset. This step is extremely important to ensure adequate fit, maintaining aesthetic continuity with the mid vault while maintaining support across the ULC to appropriately stent open the internal valve. The average size of the final cartilage graft is approximately 2 cm × 1 cm.⁹ The cephalic and lateral edges of the cartilage are beveled to ensure a cuff of perichondrium that helps camouflage the graft, especially at its cephalic transition with the dorsal septum (→ Fig. 1).

Attention is turned to the rhinoplasty portion of the surgery. The BFG can be inset from either an endonasal or open approach depending on patient's anatomy and surgeon preference. The senior author prefers the endonasal approach. While the external approach is a feasible way to perform BFG inset, the senior author prefers the endonasal approach, as the graft is naturally nested between the cartilaginous dorsum and the skin soft tissue envelope (SSTE) without excessive tissue dissection.

An intercartilaginous incision is made between the ULC and lower lateral cartilages. The ULC and dorsal septum are freed in a subnasal superficial muscular aponeurotic system (SMAS) plane to the rhinion, then dissection proceeds cephalically to the nasion in a subperiosteal plane. Next, an incision is made in the coronal plane, as caudally as possible, to include the anterior septal angle, allowing for graft inset. The concept is to match the removal of the dorsal septum/upper lateral crural articulation segment to the carved BFG dimensions, which can be seen in → Fig. 2. The ULC is further released from the septum to allow for mobility during inset. The BFG is initially secured to the medial and caudal corner of the ULC to center the graft. Then lateral sutures are placed to complete the valve opening, using 5-0 Polydioxanone suture on a P-2

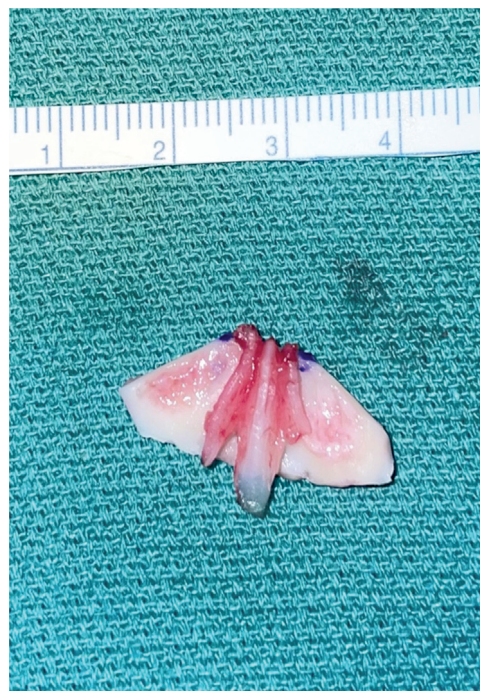

Fig. 2 This is the resected dorsal septum/ULC articulation (DSA) segment overlaid on the BFG, demonstrating matching cephalocaudal dimensions of graft with resected DSA. BFG, butterfly graft.

needle. All sutures require intact perichondrium on the convex (posterior) surface of the BFG.

Revision Rhinoplasty Considerations

Nasal airway obstruction may persist after primary rhinoplasty, with some estimates nearing 10%.¹⁰ Additionally, dorsal hump reduction and mid vault alteration frequently encountered in primary aesthetic rhinoplasty can cause medialization and posterior displacement of the ULCs, narrowing the INV.¹¹ These problems are often challenging to address with minimal primary septal cartilage available. Furthermore, spreader grafts lateralize the stenotic ULCs, but do not provide support against dynamic collapse. Flaring sutures can help, but this is often not sufficient to overcome the resultant nasal valve stenosis.¹² The BFG can be used in combination with other external valve augmentation techniques, such as batten grafts or lateral crural strut grafts. However, the BFG often provides sufficient improvement in nasal airflow as a stand-alone graft to minimize the need for additional cartilage in revision cases. The BFG is a preferred technique to address both the mid vault stenosis and collapse secondary to weakened dorsal septum and ULCs, supported by the natural contour of auricular cartilage.

Recently, we have looked at our own revision cases in a 3-year retrospective study of 375 patients with primary and secondary functional septorhinoplasty with BFG. Revision was for asymmetries or unacceptable fullness from the BFG in all cases, and none were for functional reasons. We had an approximate 2.4% revision rate. We found revision BFG surgery significantly improved appearance and maintained nasal airway perception, as measured by NOSE scores.¹³

Ethnic Rhinoplasty Considerations

Although Leong and Eccles suggested that the differences in nasal anatomy across ethnicities do not appreciably affect nasal physiology, tailored treatment of nasal airway obstruction must consider anatomic variation to achieve optimal functional and aesthetic results for patients.¹⁴ A “one size fits all” approach to the INV does not adequately address nasal airway obstruction across ethnicities.¹⁵ For example, it has been shown that nasal dilator strips may have varied impact on peak inspiratory flow between population groups, with efficacy affected by thickness of the skin envelope.¹⁶ Placement of the butterfly cartilage graft directly onto the ULCs will apply the greatest expansile force possible, and will also minimize the effect of the dorsal skin and soft tissue variable.¹⁶ Additionally, from an aesthetic perspective, given the thicker SSTE seen in non-Caucasian patients, the BFG is well camouflaged in the mid vault.

Butterfly Graft with Dorsal Preservation Rhinoplasty

The senior author has incorporated DPR techniques into his practice and is currently the favored approach to lower dorsal projection (if aesthetically appropriate). These techniques provide a unique complement to addressing challenges in functional septorhinoplasty. Previously, mid vault augmentation, either through spreader grafting or BFG, may lead to widening of the mid vault, often more visible in the classically thin skinned, narrow nose Caucasian patient, which are often those at greatest risk for internal valve stenosis (►Fig. 3).¹⁷ Although the increase in mid vault width is noticeable, there is no difference between BFGs and spreader grafts.¹⁸ In DPR, the bony and cartilaginous

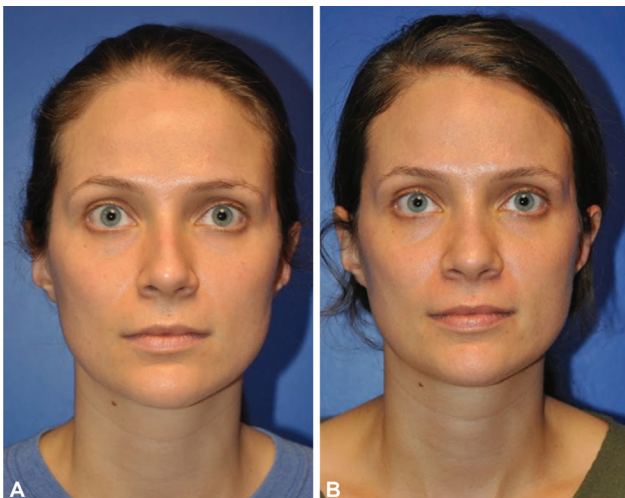

Fig. 3 (A) Preoperative frontal view of a young female patient with thin skin and severe nasal valve compromise. Preoperative NOSE (nasal obstruction symptom evaluation) score: 80. (B) Three-month postoperative frontal view after functional septorhinoplasty using butterfly graft and dorsal preservation “let down” technique. There is some residual SSTE excess that will continue to settle as her healing matures. Postoperative NOSE score: 0. SSTE, skin soft tissue envelope.

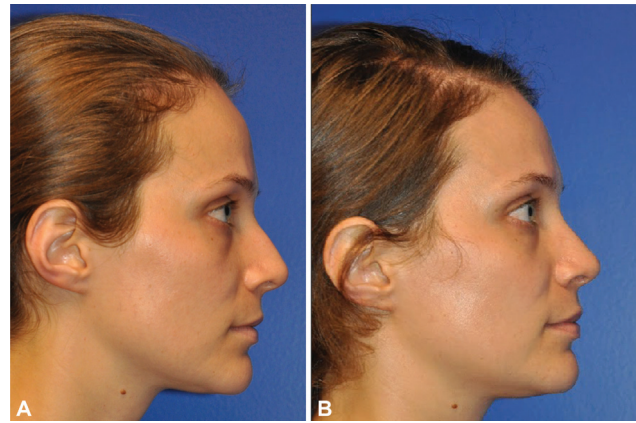

Fig. 4 (A) Preoperative lateral view showing mild dorsal convexity. (B) Three-month postoperative lateral view showing straightened dorsal profile employing DPR “let down” technique, providing excellent camouflage of the butterfly graft. DPR, dorsal preservation rhinoplasty.

dorsum is preemptively “let down,” maintaining the critical angle between the caudal border of the ULC and the dorsal septum, constituting the previously described superior corridor.⁵ By lowering the dorsum, there is a relative SSTE excess, resulting in a thicker “covering” of the mid vault (►Fig. 4). Additionally, when the dorsum is lowered in DPR, there is the potential for a natural shallowing in the supratip area that is conveniently counteracted by the BFG. In this way, when the BFG is employed for nasal valve collapse, there may be the potential for less noticeable volume in the mid vault.

Conclusion

Nasal obstruction is a challenging problem that requires a patient-specific, nuanced approach for satisfactory outcomes. Both medical and surgical treatment should be optimized. For over 20 years, BFG has proven to be a versatile method adaptable to many patient populations and especially useful in revision cases. Additionally, with gaining popularity of DPR techniques, selective incorporation of BFG can ensure that functional outcomes are not compromised.

Conflict of Interest
None declared.

References

- 1 Yamasaki A, Levesque PA, Bleier BS, et al. Improvement in nasal obstruction and quality of life after septorhinoplasty and turbinate surgery. *Laryngoscope* 2019;129(07):1554–1560
- 2 Lindsay RW. Disease-specific quality of life outcomes in functional rhinoplasty. *Laryngoscope* 2012;122(07):1480–1488
- 3 Hsu DW, Suh JD. Anatomy and physiology of nasal obstruction. *Otolaryngol Clin North Am* 2018;51(05):853–865
- 4 Chandra RK, Patadia MO, Raviv J. Diagnosis of nasal airway obstruction. *Otolaryngol Clin North Am* 2009;42(02):207–225, vii
- 5 Varman R, Clark M. Butterfly graft technique for addressing the internal nasal valve. *Facial Plast Surg* 2022;38(04):347–352

- 6 Brandon BM, Austin GK, Fleischman G, et al. Comparison of airflow between spreader grafts and butterfly grafts using computational flow dynamics in a cadaveric model. *JAMA Facial Plast Surg* 2018;20(03):215–221
- 7 Clark JM, Cook TA. The 'butterfly' graft in functional secondary rhinoplasty. *Laryngoscope* 2002;112(11):1917–1925
- 8 Friedman O, Cook TA. Conchal cartilage butterfly graft in primary functional rhinoplasty. *Laryngoscope* 2009;119(02):255–262
- 9 Howard BE, Madison Clark J. Evolution of the butterfly graft technique: 15-year review of 500 cases with expanding indications. *Laryngoscope* 2019;129(S1):S1–S10
- 10 Beekhuis GJ. Nasal obstruction after rhinoplasty: etiology, and techniques for correction. *Laryngoscope* 1976;86(04):540–548
- 11 Ballert JA, Park SS. Functional considerations in revision rhinoplasty. *Facial Plast Surg* 2008;24(03):348–357
- 12 Sinkler MA, Wehrle CJ, Elphinstone JW, Magidson E, Ritter EF, Brown JJ. Surgical management of the internal nasal valve: a review of surgical approaches. *Aesthetic Plast Surg* 2021;45(03):1127–1136
- 13 Varman R, Clark M. Butterfly graft secondary contouring in functional rhinoplasty. *Laryngoscope* in press
- 14 Leong SC, Eccles R. A systematic review of the nasal index and the significance of the shape and size of the nose in rhinology. *Clin Otolaryngol* 2009;34(03):191–198
- 15 Heiman AJ, Nair L, Kanth A, Baltodano P, Patel A, Ricci JA. Defining regional variation in nasal anatomy to guide ethnic rhinoplasty: a systematic review. *J Plast Reconstr Aesthet Surg* 2022;75(08):2784–2795
- 16 Kam AW, Pratt E, Harvey RJ. Comparing the effectiveness of nasal dilator strips: does race play a role? *J Laryngol Otol* 2015;129 (Suppl 1):S51–S56
- 17 Sheen JH. Spreader graft: a method of reconstructing the roof of the middle nasal vault following rhinoplasty. *Plast Reconstr Surg* 1984;73(02):230–239
- 18 Mims MM, Shockley WW, Clark JM. Casual observers' perception on the aesthetics of the butterfly graft. *Laryngoscope* 2023;133 (10):2578–2583