



# Aptis Distal Radioulnar Joint Arthroplasty: A Multicenter Evaluation of Functional Outcomes, Complications, and Patient Satisfaction

Shirley D. Stougie, PT<sup>1,2</sup> Leonieke C. van Boekel, MD, PhD<sup>4</sup> Annechien Beumer, MD, PhD<sup>3</sup>  
Peter Hoogvliet, MD, PhD<sup>1</sup> Simon D. Strackee, MD, PhD<sup>2</sup> J. Henk Coert, MD, PhD<sup>1</sup>

<sup>1</sup> Department of Plastic, Reconstructive and Hand Surgery, University Medical Center Utrecht, The Netherlands

<sup>2</sup> Department of Plastic, Reconstructive and Hand Surgery, Amsterdam University Medical Center, The Netherlands

<sup>3</sup> Department of Orthopedic Surgery, Amphia Hospital, Breda, The Netherlands

<sup>4</sup> Foundation for Orthopedic Research, Care and Education, Amphia Hospital, Breda, The Netherlands

Address for correspondence Shirley D. Stougie, PT, Department of Plastic, Reconstructive and Hand Surgery, Amsterdam University Medical Centre, The Netherlands  
(e-mail: s.d.stougie@amsterdamumc.nl).

J Wrist Surg 2024;13:318–327.

## Abstract

**Background** The Aptis distal radioulnar joint (DRUJ) implant has been commonly used to replace the DRUJ and restore wrist function in patients with a severely destroyed DRUJ.

**Objective** Promising results have been described in the literature. However, the clinical results in a multicenter setting are sparse and variable. This study evaluates the short- to midterm clinical results of 53 patients with a (mean) follow-up of 51 months.

**Patients and Methods** Fifty-three patients (59 implants) treated between 2011 and 2020 in three different institutions were retrospectively identified in a prospectively collected database. The main indication for Aptis DRUJ arthroplasty was a destroyed DRUJ and gross distal radioulnar instability and isolated DRUJ osteoarthritis. Functional outcome, complications, and patient satisfaction were evaluated. Patients completed the Patient-Rated Wrist Evaluation (PRWE) questionnaire and an additional questionnaire about patient satisfaction and return to hobby/work.

**Results** Implant survival was 92%, the surgical follow-up showed many complications (64.4%), and revision surgery was needed frequently (40.7%). In 13 cases, the follow-up was longer than 5 years. Three reimplantations had to be performed and two implants were permanently explanted. In spite of this all, wrist and forearm motion as well as pain reduction was adequate and patient satisfaction was reasonable (72.2%).

**Conclusion** The Aptis DRUJ arthroplasty is a viable option that can provide adequate wrist and forearm function after secure patient selection and surgical placement of the implant in the wrist with a good bone stock of the radius. The complication rate was found to be high, yet patient satisfaction was reasonable. In the case of secondary surgery, additional surgery seems to be needed. For primary surgery, the implant

## Keywords

- ▶ distal radioulnar joint
- ▶ arthroplasty
- ▶ functional outcomes
- ▶ complications
- ▶ joint replacement

received  
February 22, 2023  
accepted  
August 10, 2023  
article published online  
September 13, 2023

DOI <https://doi.org/10.1055/s-0043-1774317>.  
ISSN 2163-3916.

© 2023. The Author(s).

This is an open access article published by Thieme under the terms of the Creative Commons Attribution-NonDerivative-NonCommercial-License, permitting copying and reproduction so long as the original work is given appropriate credit. Contents may not be used for commercial purposes, or adapted, remixed, transformed or built upon. (<https://creativecommons.org/licenses/by-nc-nd/4.0/>)

Thieme Medical Publishers, Inc., 333 Seventh Avenue, 18th Floor, New York, NY 10001, USA

seems to be successful without complications. Different complications have been described, but further analysis is warranted to find the causes of complications and to objectify the performance of the Aptis DRUJ implant.

#### Level of Evidence IV.

Forearm and wrist fractures resulting in the destruction of the distal radioulnar joint (DRUJ) and distal radioulnar instability can compromise wrist function and hinder activities of daily living.<sup>1</sup> Other known causes of a dysfunctional DRUJ are degenerative osteoarthritis, rheumatoid arthritis, and congenital disorders.<sup>2</sup> When symptomatic DRUJ osteoarthritis occurs, many surgeons used to perform the traditional ulnar head resection or replacement procedures, which could result in pain and gross distal radioulnar instability.<sup>3–11</sup> To overcome these problems, Scheker et al<sup>12</sup> developed the (semi-)constrained Aptis DRUJ implant to concomitantly address the arthritic pain and ulnar instability while preserving wrist and forearm motion.

Previous conducted studies have shown promising short- and midterm functional outcomes, a high survival ratio, and considerable patient satisfaction.<sup>13–21</sup> However, in recent studies,<sup>13,22–28</sup> high complication rates and surgical revision rates (23–50%) are often debated. This discrepancy raises the question of whether the functional outcome, implant survival ratio, and patient satisfaction are valid indicators of the performance of the Aptis DRUJ arthroplasty. Oonk et al<sup>29</sup> suggested that the forearm kinematics are not yet completely understood and also not yet processed into the implant design or procedural steps of surgery. Data on functional outcome, complications, patient satisfaction, and return to hobby and/or work in a multicenter setting have not been reported much. The objective of this study is to describe the short- to midterm functional outcome, complications, patient satisfaction, and return to hobby and/or work of 53 patients who were treated with 59 Aptis DRUJ implants for a destroyed DRUJ and gross DRUJ instability and isolated DRUJ osteoarthritis within three different medical centers in The Netherlands.

## Methods

### Study Design

Patients treated with an Aptis DRUJ arthroplasty between 2011 and 2020 in three different institutions within The Netherlands were retrospectively identified in a prospectively collected database. Patients with a follow-up of less than 24 months were excluded. A letter was sent to the patients to ask for their attention to the upcoming survey. They were asked for written informed consent. A hundred patients were screened for eligibility and 53 patients (53%) agreed to participate. The demographic characteristics and surgical characteristics of the remaining 47 patients (47%) were similar to the 53 patients included in the study. The functional outcome of patients who underwent reimplantation was not included in the final functional outcome. The surgical follow-up of these cases was described in the clinical

evaluation section. The Medical Ethical Committee of the Amsterdam University Medical Centers, Amsterdam, declared that this study is not subject to the Dutch Medical Research with Human Subjects Law.

### Data Collection

After written informed consent was obtained, patients completed the Dutch Language Version of the Patient-Rated Wrist Evaluation (PRWE) questionnaire.<sup>30</sup> Since the questionnaire does not discriminate between left and right, patients had to complete the PRWE twice (once for the left hand and once for the right hand) in case of a bilateral surgery. The PRWE questionnaire measures the following scales: “pain” and “function” of the operated wrist. The total score is the sum of pain and function scores, with 0 points indicating no pain and able to perform activities and 100 points indicating the worst imaginable pain and not able to perform activities.<sup>30</sup>

Patient satisfaction with the Aptis DRUJ implant was determined on a scale of 1 to 5, with 1 indicating highly unsatisfied and 5 indicating highly satisfied. The following additional three questions were asked to analyze patient satisfaction: (1) whether patients would recommend the procedure to other patients (yes/no), (2) if they would undergo the procedure again when in the same circumstances (yes/no), and (3) if they could resume their previous hobby and/or work (yes/no). Patients’ medical files were reviewed to extract the following data: age, gender, hand dominance, type of Aptis DRUJ implant, operated wrist, number of previous surgeries, preoperative delay, type of previous surgeries, indications, complications, revision surgery, pre- and postoperative active wrist range of motion, pre- and postoperative pain score in the visual analog scale (VAS), pre- and postoperative grip strength, X-rays, and computed tomography (CT) scans. All complications that could be attributed to the Aptis DRUJ arthroplasty were reported and graded by the Clavien–Dindo classification.<sup>31</sup>

Postoperative X-rays were reviewed at follow-up clinic visits for heterotopic ossifications, bony configuration, periprosthetic radiolucency or fractures, position of the implant, and signs of implant loosening or migration.

### Surgical Technique and Postoperative Regime

The surgeries were performed by three dedicated senior surgeons (SDS, AB, JHC) in three institutions with a level V experience according to Nakamura.<sup>32</sup> The second generation of the Aptis DRUJ implant (Aptis Medical, Louisville, KY, United States) was placed in 59 cases.

The procedural steps of surgery were the same in all three medical centers. The DRUJ was approached through the fifth extensor compartment followed by opening the dorsal DRUJ capsule longitudinally and closing the fifth extensor

compartment to cover the implant. This is a modification of the original surgical technique, as described in detail by Scheker et al, who used a retinaculum flap to cover the implant.<sup>12</sup> The postoperative regime consisted of 7 days of short arm casting and self-rehabilitation in most cases. The patients were allowed to start with active mobilization of the wrist in all directions. Gradual weight bearing and lifting up to 15 kg was allowed at 3 months postoperatively as described in the Aptis manual.

### DRUJ Arthroplasty

The sequence of the implant placement (►Table 1) differed in 31 cases (66%). In 11 cases, an ulnar head implant (Herbert, KLS Martin Medizin, Tuttlingen, Germany) was removed, and in 1 case a Schuurman DRUJ implant. In five cases, an Aptis DRUJ implant was placed in the wrist that already had a Universal 2 implant (Integra LifeSciences, Plainsboro, NJ, United States) in situ. The peg of the radial component was shortened as needed to avoid potential collision with the stem of the total wrist implant. In one case, a total wrist arthroplasty (TWA) was performed in a wrist with an Aptis DRUJ implant in situ. In two cases, TWA and Aptis DRUJ arthroplasty were performed in a wrist without previous implants in which a wrist arthrodesis was converted to TWA. In six cases, the Aptis DRUJ implant was placed after a Sauvé-Kapandji procedure. In two cases, the Aptis DRUJ implant was performed in a wrist that already had a (partial) wrist fusion. In three cases, a reimplantation was performed.

### Statistics

Descriptive analyses were used to describe the study cohort in terms of survival ratio, patient satisfaction, pain, and complication rates and surgical revision rates. Proportions (%) were used for the categorical outcome of the cohort. Differences in pre- and postoperative active range of motion, grip strength, pain scores in the VAS, and PRWE scores were tested using the paired Wilcoxon signed-rank test for data that were not normally distributed. The Kolmogorov-Smirnov test was used to test for normality. Spearman's correla-

**Table 1** Sequence of Aptis DRUJ implant placement

Sequence implant placement	n
Conversion of the ulnar head implant to the Aptis DRUJ implant	11
Conversion of the Schuurman DRUJ implant to the Aptis DRUJ implant	1
Aptis DRUJ arthroplasty after Universal 2 TWA	5
Universal 2 TWA after Aptis DRUJ arthroplasty	1
Simultaneous Remotion TWA and Aptis DRUJ arthroplasty	2
Conversion Sauvé-Kapandji to Aptis DRUJ implant	6
Aptis DRUJ implant after (partial) wrist fusion	2
Reimplantation	3

Abbreviations: DRUJ, distal radioulnar joint; TWA, total wrist arthroplasty.

**Table 2** Demographic characteristics and follow-up time

Age (y), median (IQR)	56 (48–63)
Men	20
Woman	33
Dominant wrist operated (n)	28
Type of Aptis DRUJ implant	Second generation
Previous surgeries (n)	2.0 (range: 0–7)
Time between trauma and Aptis DRUJ arthroplasty (mo), mean (SD)	59.5 (85.8)
Follow-up time (mo), mean (SD)	51.3 (29.7)

Abbreviations: IQR, interquartile range; DRUJ, distal radioulnar joint; SD, standard deviation.

tions were calculated on ordinal data to study the associations between satisfaction, pain, complications, and PRWE scales (pain, function, and total). A *p*-value of less than 0.05 was considered statistically significant.

## Results

### Demographics and Follow-up

Demographic characteristics and follow-up time are shown in ►Table 2. The median age of the patients at surgery was 56 years. The cohort consisted of 20 men (38%) and 33 women (62%). About half of the patients were operated on their dominant wrist. Twenty-one patients (40%) were operated on in their right wrist, 26 patients (49%) were operated on in their left wrist, and 3 patients underwent bilateral surgery. Fifty-three patients underwent previous wrist surgery (range of 0–7 surgeries and mean of 1.9 surgeries in the wrist). The types of previous surgeries are shown in ►Table 3. The indications are shown in ►Table 4, but the main

**Table 3** Type of surgeries before an Aptis DRUJ arthroplasty

Previous surgeries	n
Ulnar head implant	11
Total wrist arthroplasty	5
Schuurman DRUJ implant	1
Aptis DRUJ implant	3
(Partial) wrist fusion	2
ORIF/external fixator	10
Sauvé-Kapandji procedure	6
Darrach procedure	4
Proximal row carpectomy	3
Bowers procedure	1
Ulnar shortening osteotomy	4
Pisiformectomy	1
Capsuloplasty DRUJ	1

Abbreviations: DRUJ, distal radioulnar joint; ORIF, open reduction and internal fixation.

**Table 4** Indications for Aptis DRUJ arthroplasty

Indications	n
Destroyed DRUJ and ulnar instability	37
Isolated DRUJ osteoarthritis without previous wrist surgery	11
Isolated DRUJ osteoarthritis after previous surgery	5
Rheumatoid arthritis	1
Nonunion after a Sauvé-Kapandji procedure	1
Dislocation of the Schuurman DRUJ implant	1
Dislocation of the Aptis DRUJ implant	3

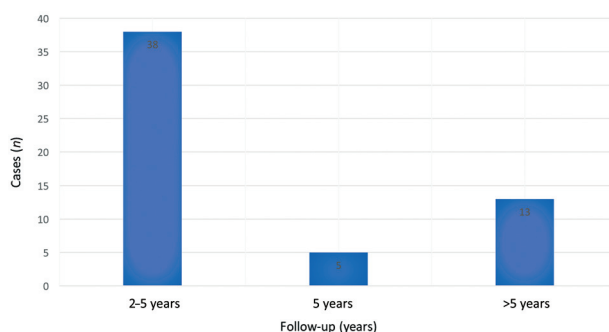
Abbreviations: DRUJ, distal radioulnar joint arthroplasty.

indication was posttraumatic destroyed DRUJs with ulnar instability ( $n=37$ , 63%) and isolated DRUJ osteoarthritis without previous wrist surgery ( $n=11$ , 19%). Ten patients (19%) underwent a combined surgery: TWA and Aptis DRUJ arthroplasty ( $n=8$ , 15%) and (partial) wrist fusion and Aptis DRUJ arthroplasty ( $n=2$ , 4%). The mean time between trauma and Aptis DRUJ arthroplasty was 59.5 months (range: 6–411 months). Patients were evaluated in January 2023 at a (mean) follow-up of 51 months (range: 24–132 months). In 13 cases, the follow-up was longer than 5 years (**►Fig. 1**).

### Clinical Evaluation

An example of postoperative wrist motion is illustrated in **►Fig. 2**. Ulnar deviation and supination increased statistically significantly ( $p<0.05$ ; **►Table 5**). The mean ulnar deviation improved from 19.2 degrees (SD: 11.5) to 31.5 degrees (SD: 13.0;  $t=-3.860/p=0.002$ ) and the mean supination improved from 47.5 degrees (SD: 32.7) to 67.8 degrees (SD: 18.8;  $t=-4.025/p=0.000$ ).

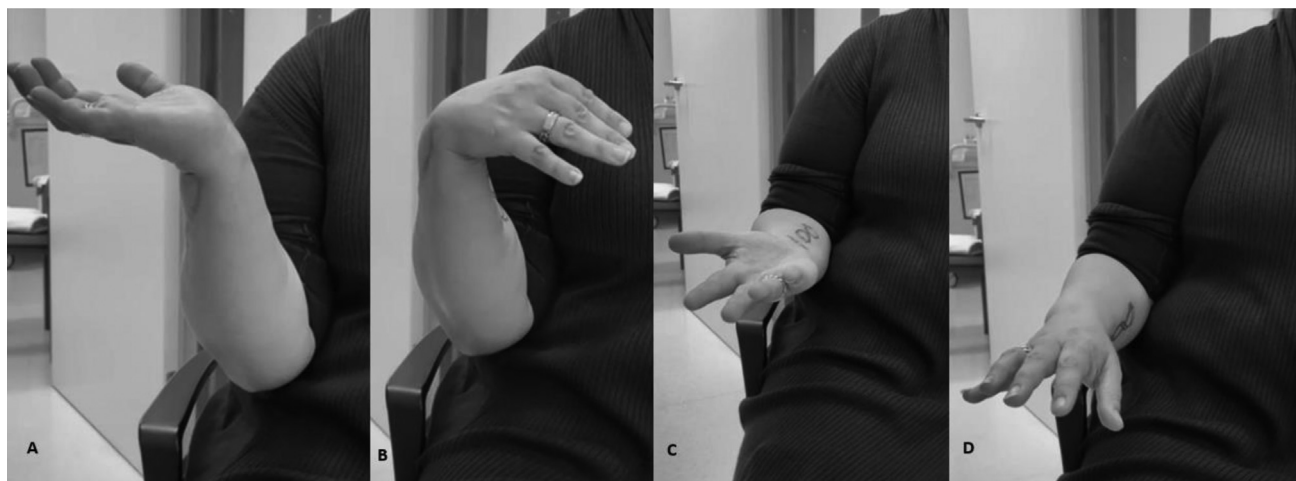
The VAS pain scores at rest and during activity were found to decrease statistically significantly. The mean VAS at rest improved from 6.4 points (SD: 3.1) to 2.2 points (SD: 2.8;  $t=5.667/p=0.000$ ) and during activity improved from 8.0 points (SD: 2.5) to 4.0 points (SD: 3.3;  $t=6.218/p=0.000$ ). In

**Fig. 1** Follow-up in years after Aptis distal radioulnar joint (DRUJ) implantation.

17 cases (28.8%), the postoperative VAS pain score during activity remained considerable ( $>6$  points), despite adequate wrist motion.

The mean postoperative grip strength was around 21 kg. Postoperative PRWE scores were available in 46 cases (82%). The median PRWE scale “total score” was 31 points, 19 points for “function,” and 19 points for “pain,” which indicate insufficient benefits from pain and function (e.g., mostly lifting heavy objects).

In two cases, the patient satisfaction score was missing. Fifty-four cases (96.4%) responded. In 39 cases (72.2%), the patients were (very) satisfied with the procedure (**►Table 6**), whereas the patients were unsatisfied in 4 cases and very unsatisfied in 3 cases. In 11 cases of the above-mentioned 39 cases, the patients were very satisfied with the Aptis DRUJ arthroplasty as a primary surgical treatment for isolated DRUJ osteoarthritis. In seven cases, the patients were unsatisfied probably as a result of considerable pain and major complications. In three cases, the patients were satisfied with the Aptis DRUJ arthroplasty, despite considerable pain. In one case, the patient was very unsatisfied despite a pain score of 1 point in the VAS at rest and 2 points during activities. As expected, a significant negative correlation was found between patient satisfaction and pain score in the VAS at rest ( $r=-0.460/p=0.001$ ) and pain score in the VAS during activity ( $r=-0.434/p=0.001$ ).

**Fig. 2** (A–D) Clinical example of postoperative wrist motion.

**Table 5** Comparison of the preoperative and postoperative values and follow-up PRWE

Outcome	Preoperative Mean $\pm$ SD	Postoperative Mean $\pm$ SD	<i>p</i> -value	<i>t</i> -value
Extension (degrees), <i>n</i> = 26	41.9 $\pm$ 19.9	48.7 $\pm$ 16.6	0.161	-1.446
Flexion (degrees), <i>n</i> = 26	39.6 $\pm$ 17.4	46.0 $\pm$ 17.0	0.130	-1.565
Radial deviation (degrees), <i>n</i> = 13	14.6 $\pm$ 9.2	16.2 $\pm$ 6.5	0.536	-.636
Ulnar deviation (degrees), <i>n</i> = 13	19.2 $\pm$ 11.5	31.5 $\pm$ 13.0	0.002 <sup>a</sup>	-3.860
Supination (degrees), <i>n</i> = 36	47.5 $\pm$ 32.7	67.8 $\pm$ 18.5	0.000 <sup>a</sup>	-4.025
Pronation (degrees), <i>n</i> = 36	61.7 $\pm$ 28.7	75.2 $\pm$ 15.5	0.007	-2.861
VAS rest ( <i>n</i> = 24)	6.4 $\pm$ 3.1	2.2 $\pm$ 2.8	0.000 <sup>a</sup>	5.667
VAS activity ( <i>n</i> = 24)	8.0 $\pm$ 2.5	4.0 $\pm$ 3.3	0.000 <sup>a</sup>	6.218
Grip strength (kg) Operated wrist ( <i>n</i> = 23)	-	21.3		
		Postoperative Median (IQR)		
PRWE total ( <i>n</i> = 46)	-	31 (13.5-56.1)		
PRWE pain ( <i>n</i> = 46)	-	19 (5.3-31.5)		
PRWE function ( <i>n</i> = 46)	-	19 (4.5-30.3)		

Abbreviations: DRUJ, distal radioulnar joint; IQR, interquartile range; PRWE, Patient-Rated Wrist Evaluation; ROM, range of motion; VAS, visual analog scale.

<sup>a</sup>Statistically significant.

A significant negative correlation was found between patient satisfaction and PRWE pain scale ( $r = -0.505/p = 0.000$ ), PRWE function scale ( $r = -0.432/p = 0.003$ ), and PRWE total scale ( $r = -0.455/p = 0.002$ ).

After primary surgery, the functional outcome and patient satisfaction with the implant were good and no complications were seen. These patients preferred an Aptis DRUJ implant to an ulnar head implant due to a better lifting capacity. This is in line with the results described by Amundsen et al.<sup>22</sup>

In seven cases, the data about recommending the procedure were missing. In 46 cases (90%), the patients would

**Table 6** Follow-up patient satisfaction, resume hobby, and return to previous work rate

Patient satisfaction	<i>n</i>
Very satisfied	17
Satisfied	22
Neutral	8
Unsatisfied	4
Very unsatisfied	3
Not reported	2
Resume previous hobby	24
Return to previous work rate	10
Would recommend procedure	46; 1 patient was not sure about this
Would choose the Aptis DRUJ arthroplasty again	47

Abbreviation: DRUJ, distal radioulnar joint.

recommend the procedure to other patients, but 1 patient was not sure about this. In six cases, data regarding undergoing the procedure again were missing. In 47 cases (89%), patients would undergo the procedure again under the same circumstances.

After an Aptis DRUJ arthroplasty, 24 patients (45%) were able to resume their hobby and 11 patients (20%) were able to return to their previous work.

### Complications

The incidence of complications was high (64.4%). Only in 32 cases (54%) were there no complications. Interestingly, in the isolated DRUJ osteoarthritis cohort without previous surgery, no complications were seen. In 27 cases (46%), 38 complications were seen and revision surgery was often (40.7%) needed (► **Table 7**). Major complications requiring revision surgery occurred in seven cases: dislocations of the radial component (*n* = 5), extreme heterotopic ossifications (*n* = 1), and a periprosthetic fracture (*n* = 1). Three reimplantations were performed, two implants were removed, resection of heterotopic ossifications was done, and a volar locking plate fixation was performed (*n* = 1). Unfortunately, the implant was explanted in two cases due to recurrent dislocation. In 17 cases, revision surgery was needed due to minor complications such as extensor carpi ulnaris tenosynovectomy (*n* = 2), shortening a protruding screw (*n* = 1), first extensor compartment release (*n* = 1), repair of the extensor tendon of the fourth digit (*n* = 1), extensor tendon indicis proprius to extensor tendon pollicis longus transposition (*n* = 1), excision of ganglion extensor tendon of the fourth digit (*n* = 1), adhesiolysis extensor digiti (*n* = 1), tenolysis flexor pollicis longus (*n* = 1), excision of heterotopic

**Table 7** Complications attributed Aptis DRUJ arthroplasty and additional revision surgery

Complications	N (%)	Clavien–Dindo classification
<b>Major requiring surgery</b>	7 (11.9)	
Excision of severe heterotopic ossification	1 (1.7)	Grade IIIa
Explantation	2 (3.4)	Grade IIIa
Revision of the Aptis DRUJ implant	3 (5.1)	Grade IIIa
Periprosthetic fracture of the distal radius requiring volar plate fixation	1 (1.7)	Grade IIIa
<b>Minor requiring surgery</b>	17 (28.8)	
Extensor carpi ulnaris tenosynovectomy	2 (3.4)	Grade IIIa
Shortening the protruding screw	1 (1.7)	Grade IIIa
Release of the first extensor compartment	1 (1.7)	Grade IIIa
Repair of the extensor tendon of the fourth digit	1 (1.7)	Grade IIIa
Extensor indices proprius extensor pollicis longus transposition	1 (1.7)	Grade IIIa
Excision of the ganglion extensor tendon of the fourth digit	1 (1.7)	Grade IIIa
Adhesiolysis extensor digits	1 (1.7)	Grade IIIa
Tenolysis flexor of the pollicis longus	1 (1.7)	Grade IIIa
Excision of heterotopic ossification	4 (6.8)	Grade IIIa
Neurectomy of the dorsal cutaneous branch of the ulnar nerve	1 (1.7)	Grade IIIa
Release of the interosseous membrane	1 (1.7)	Grade IIIa
Neurectomy of the PIN and AIN	2 (3.4)	Grade IIIa
<b>Minor</b>	14 (16.9%)	
Low-grade infection (Rx AB)	2 (3.4)	Grade II
Hematoma	3 (5.1)	Grade II
Periprosthetic fracture of the distal radius	1 (1.7)	Grade II
Superficial infection (Rx AB)	1 (1.7)	Grade II
Extensor carpi ulnaris tendinitis	7 (11.9)	Grade II

Abbreviations: (Rx AB), treatment antibiotics; AIN, anterior interosseus nerve; DRUJ, distal radioulnar joint; ECU, extensor carpi ulnaris; EDC, extensor digitorum communis; EPL, extensor pollicis longus; PIN, posterior interosseus nerve.

ossification ( $n=4$ ), neurectomy of the dorsal cutaneous branch of the ulnar nerve ( $n=1$ ), release of the interosseous membrane ( $n=1$ ), neurectomy of the posterior interosseous nerve, and anterior interosseous nerve ( $n=2$ ). The most common complications (24%) were periprosthetic-related extensor tendons or extensor compartment issues.

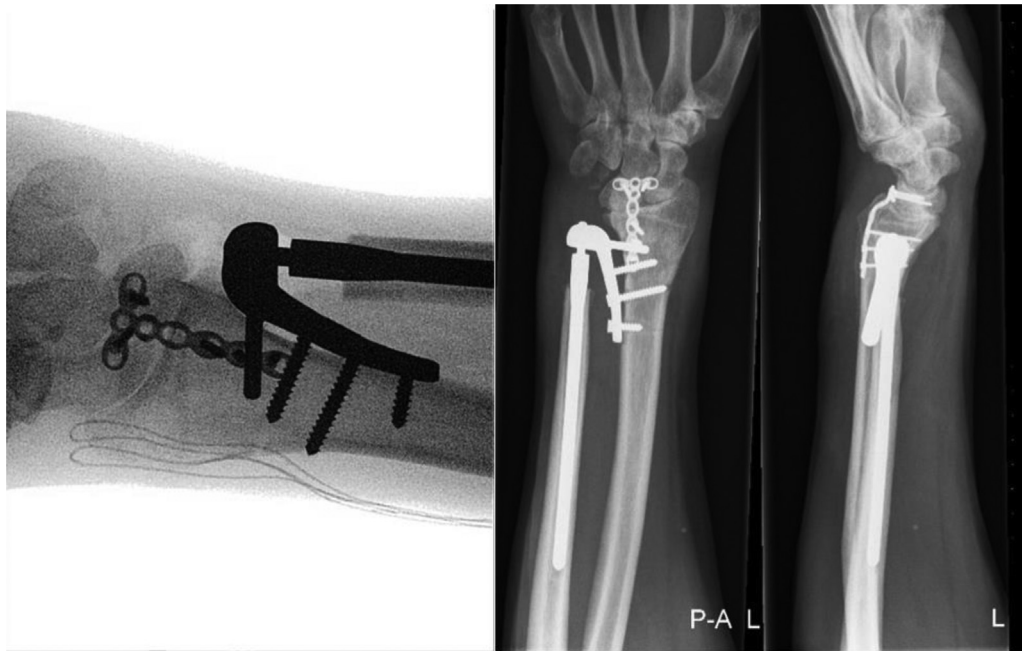
Three reimplantations were performed due to severe wrist pain and dislocation of the radial component after adequate placement preoperatively (► Fig. 3) at 4, 10, and 73 months. Two of these patients had considerable wrist pain after 3 months due to recurrent dislocation of the radial component (► Fig. 4) for which the implants were explanted and the pain was reduced. One of these patients most likely had an allergic reaction to the cobalt chromium alloy of the implant. This was determined by placing a small piece of cobalt chromium subcutaneously just proximal of the elbow, resulting in pain and an allergic reaction of the skin. One patient is awaiting a one-bone forearm procedure and the other patient is awaiting a patient-specific implant.

The third reimplantation was successful regarding reduction of pain.

Besides dislocations of the implants, heterotopic ossifications at the distal side of the ulnar side of the implant were seen. In five cases, removal of the heterotopic ossifications was needed due to a painful forearm rotation. In one case (► Fig. 5), extreme heterotopic ossifications occurred and resulted in pain and limited forearm rotation. At 5 months of follow-up, the heterotopic ossifications recurred, but the forearm rotation was reasonable.

In two cases, a periprosthetic fracture of the radius occurred and was adequately treated with a volar locking plate fixation in one and short arm casting in the other, resulting in complete union.

In eight cases, the above-mentioned extensor tendon and extensor compartment problems were adequately treated with shortening a screw tip, a first extensor compartment release, extensor tendon repair, tendon transfer from extensor indicis proprius (EIP) to extensor pollicis longus (EPL),



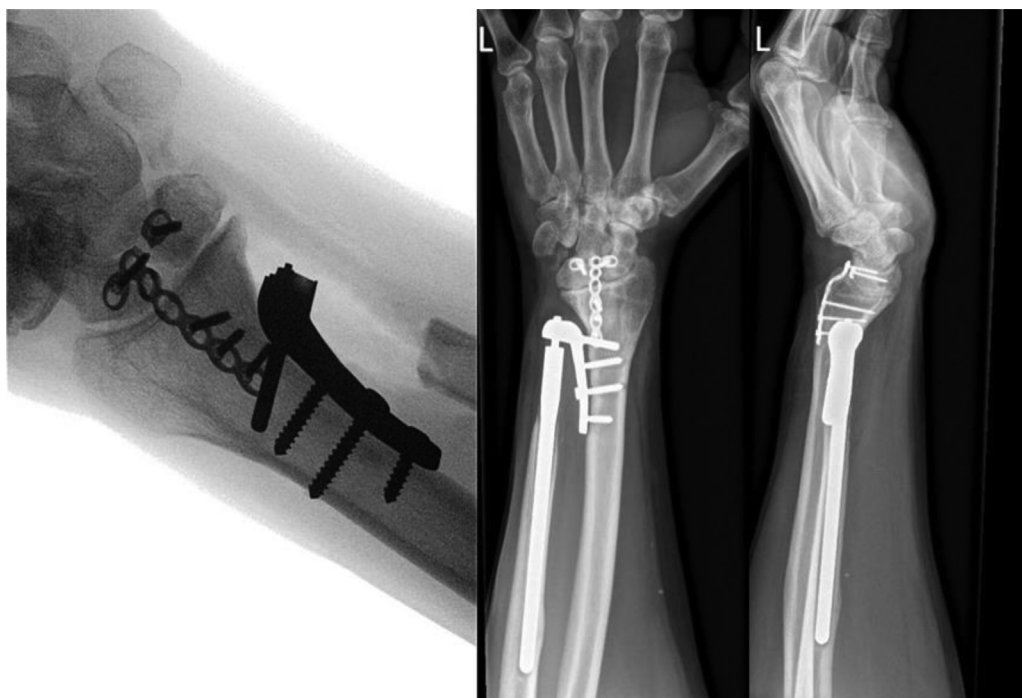
**Fig. 3** Anteroposterior and lateral X-rays of dislocation of the radial component 4 months after adequate placement of the Aptis distal radioulnar joint (DRUJ) implant, most likely as a result of poor bone stock in a patient with rheumatoid arthritis. Note the radioscapulohumeral nonunion.

excision of an extensor tendon ganglion, and adhesiolysis. In one case, tenolysis of the flexor pollicis longus was performed successfully.

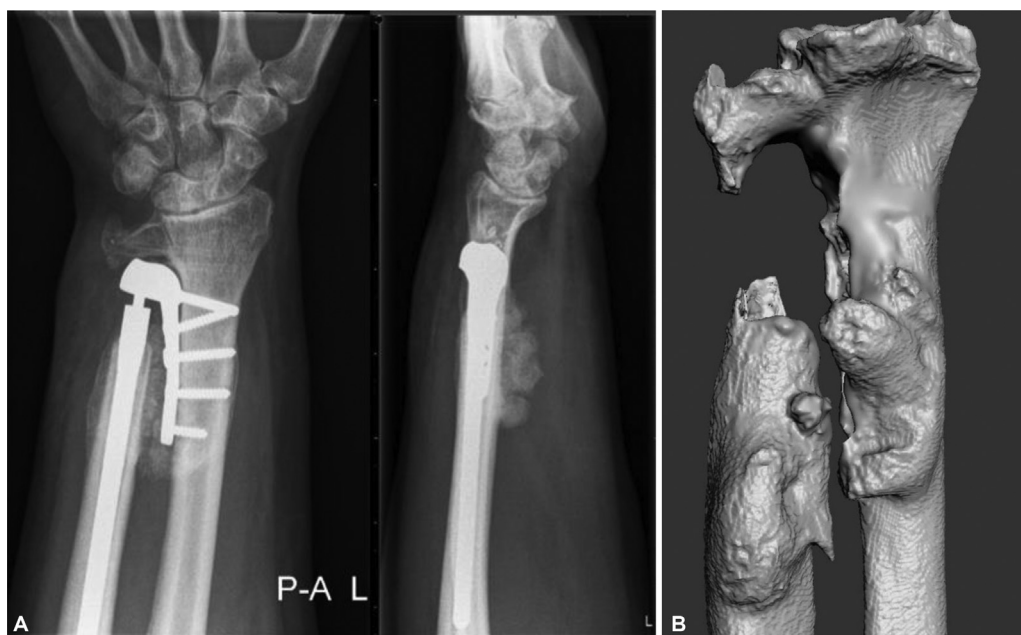Due to a painful or limited rotation, in two cases, a posterior interosseus nerve (PIN) and anterior interosseus nerve (AIN) neurectomy was performed and in one case a

release of the interosseus membrane was done. These revision procedures were unsuccessful. In three cases, a hematoma was successfully evacuated in the hand clinic.

In seven cases, the procedure was temporarily complicated by an extensor carpi ulnaris tendinitis, which was treated successfully with conservative management. In one case a



**Fig. 4** Anteroposterior and lateral X-rays of dislocation of the radial component 3 months after adequate reimplantation in a patient with rheumatoid arthritis. Note the breakage of the T-plate fixation (same case as in ►Fig. 3).



**Fig. 5** (A) Anteroposterior and lateral X-rays 5 months after Aptis distal radioulnar joint (DRUJ) implantation. Note the distal fusion left in situ and the heterotopic ossifications around the implant. (B) Three-dimensional computed tomography (CT) reconstruction of the radius and the ulna. Note the remodeling of the radius and the heterotopic ossifications.

superficial infection was seen and was adequately treated with antibiotics.

A significant negative correlation was found between patient satisfaction and complications ( $r=0.695/p=0.000$ ). A nonsignificant positive correlation was found between patient satisfaction and complication types ( $r=0.011/p=0.937$ ).

### Radiological Evaluation

In four cases, radiolucency around the screws in the radius was seen on plain films, and in three cases protruding screws (► **Table 8**). As this was an asymptomatic finding in six (10.2%) of these seven cases, no treatment was required. Heterotopic ossifications around the implant on the ulnar side were seen in eight cases. In one case, a dorsal tilt of the radial component was also seen with most likely an extensor carpi ulnaris tendinitis as a clinical consequence.

### Discussion

This multicenter study reported 59 cases with the second-generation Aptis DRUJ implant for treatment of a destroyed DRUJ and gross DRUJ instability as well as isolated DRUJ osteoarthritis. This study has shown not only improvement in wrist and forearm motion and the VAS pain but also a high

incidence of complications, surgical revision, reasonable patient satisfaction, and reasonable PRWE.

Our implant survival ratio (92%) and follow-up time are comparable with those of Warlop et al<sup>13</sup> and Kakar et al.<sup>16</sup> However, our follow-up time is only roughly half the time of Bellevue et al<sup>28</sup> and Lambrecht et al.<sup>2</sup> This may be an explanation for our high survival percentage. In this study, the survival of the Aptis DRUJ implant was up to 11 years after primary surgery without complications.

Our results regarding wrist and forearm motion, VAS pain score, grip strength, and survival ratio are comparable with those of Scheker et al,<sup>12</sup> Bizimungu and Dodds,<sup>17</sup> Bellevue et al,<sup>28</sup> Lambrecht et al,<sup>2</sup> Warlop et al,<sup>13</sup> and Brannan et al.<sup>23</sup>

Compared with other studies, our complication rate and surgical revision rate are relatively high and quite disappointing compared with previously conducted studies.<sup>13,22–25,27,28</sup> Only Lans et al<sup>26</sup> reported a higher surgical revision rate of 50% due to pisotriquetral arthritis, most likely as a result of altered pisotriquetral joint dynamics. Lans et al<sup>26</sup> also reported that accurate placement of the radial component in the severely destroyed wrist is a tedious procedure and suggested placing the radial component as distal as possible for proper fitting along the ulnar side of the radius. However, five patients in this study with a distal position developed pisotriquetral arthritis and required excision of the pisiform and/or triquetrum.

Bellevue et al<sup>28</sup> reported 52 Aptis DRUJ arthroplasties, performed in an 8-year period, and found a complication rate of 29% requiring revision surgery. The most common complications reported in this study were periprosthetic fractures and infection. Warlop et al<sup>13</sup> analyzed 41 patients with 42 implants and found a complication rate of 24% requiring revision surgery and a 92% survival ratio. Interestingly, despite a high complication rate and reasonable patient

**Table 8** Follow-up radiological evaluation

Radiological evaluation	n
Dorsal tilt radial component	1
Dislocation radial component	3
Periprosthetic radiolucency	4
Heterotopic ossifications	8



satisfaction, around 90% of patients would recommend the procedure to others or would undergo the procedure again when in the same circumstances.

Of note, the functional outcome and patient satisfaction rate in patients with the indication isolated DRUJ osteoarthritis were better than those in patients with a destroyed DRUJ and gross distal radioulnar instability, which is in line with the findings by Amundsen et al.<sup>22</sup> Amundsen et al.<sup>22</sup> also reported that the lifting capacity was better after placement of a (semi-) constrained implant in comparison with an ulnar head replacement. Replacement of the DRUJ addresses the ulnar instability without relying on the soft-tissue envelope or the geometry of the sigmoid notch and avoids postoperative ulnar instability, which is a common complication after an ulnar head replacement. No complications had occurred in our cohort with isolated DRUJ osteoarthritis without previous wrist surgery.

However, many complications occurred in complex ulnar pathology cases. The most common complications and causes for revision surgery in this study were periprosthetic-related extensor tendon and extensor compartment problems. These rather disappointing complication rates can be explained by the extensive operative history, malpositioning of the radial component of the implant, and altered position of the forearm rotation axis. A protruding screw or prominence of the radial component could lead to the attrition of extensor tendons and compartments. A possible explanation for the prominence of the radial component is that it may be inevitable to place the radial component volar and purely ulnar-ward on a deformed distal radius due to a considerable volar angulation (malunion). The implant most likely has to compensate for the altered forearm kinematics and geometry. Deformation or remodeling of the radius could lead to deviation of the radius toward the ulna and this could affect the proximal to distal translation of the radius along the ulna. This risk may be reduced by performing a corrective osteotomy of the radius prior to an Aptis DRUJ arthroplasty. The extensor tendon and compartment-related problems should be avoidable after secure patient selection and placement of the implant, for example, by using a preoperative custom-designed drilling/saw guide to allow optimal surgical placement.

In two cases, removal and reimplantation were required most likely due to poor bone stock of the radius and rheumatoid arthritis.

Due to our study design, preoperative patient satisfaction, indications for surgery, and expectations of surgery could not be reported. Correlations were found between satisfaction, pain, function, and complication. This suggests that pain and limited function is an important reason to choose surgery.

This study has several limitations. First, the retrospective design and the fact that pre- and postoperative examination was not standardized and data in active range of motion and grip strength are missing are important limitations. In addition, patient satisfaction and PRWE scores were recorded retrospectively, which may cause recall bias among respondents. Second, due to the heterogeneous and relatively small

study group, statistical analysis was limited to mostly descriptive statistics. Finally, we had a large variation in follow-up length, making a survival analysis difficult.

In conclusion, the Aptis DRUJ arthroplasty is a viable option that can provide adequate wrist and forearm function after secure patient selection and surgical placement of the implant in the wrist with a good bone stock of the radius. The complication rate was found to be high, yet patient satisfaction was reasonable. In the case of secondary surgery, additional surgery seems to be needed. Patients should be informed about this before they give their consent. For primary surgery, the implant seems to be successful without complications. Different complications have been described, but further analysis is warranted to find the causes of complications and to objectify the performance of the Aptis DRUJ implant.

#### Ethical Approval

The Medical Ethical Committee of the Amsterdam University Medical Centers, Amsterdam, declared that this study is not subject to the Dutch Medical Research with Human Subjects Law.

#### Informed Consent

Written informed consent was obtained from a legally authorized representative(s) for anonymized patient information to be published in this article.

#### Author Contributions

All the authors were actively involved in the planning and enactment of the study, and writing of the manuscript.

#### Funding

None.

#### Conflict of Interest

None declared.

#### Acknowledgments

This paper is dedicated to the late Dr. Simon Dante Strackee, an amazing hand surgeon, teacher and great inspirer. Thank you for teaching me! Forever “Scheker” Shirley.

#### References

- 1 Gates DH, Walters LS, Cowley J, Wilken JM, Resnik L. Range of motion requirements for upper-limb activities of daily living. *Am J Occup Ther* 2016;70(01):p1, p10
- 2 Lambrecht D, Vanhove W, Hollevoet N. Clinical and radiological results of distal radioulnar joint arthroplasty with the Aptis prosthesis. *J Hand Surg Eur Vol* 2022;47(04):379–386
- 3 Kachoei AR, Chase SM, Jupiter JB. Outcome assessment after Aptis distal radioulnar joint (DRUJ) implant arthroplasty. *Arch Bone Jt Surg* 2014;2(03):180–184
- 4 Martínez Villén G, García Martínez B, Aso Vizán A. Total distal radioulnar joint prosthesis as salvage surgery in multioperated patients. *Chir Main* 2014;33(06):390–395
- 5 Willis AA, Berger RA, Cooney WP III. Arthroplasty of the distal radioulnar joint using a new ulnar head endoprosthesis: preliminary report. *J Hand Surg Am* 2007;32(02):177–189

- 6 Herbert TJ, van Schoonhoven J. Ulnar head replacement. *Tech Hand Up Extrem Surg* 2007;11(01):98–108
- 7 Sauerbier M, Hahn ME, Fujita M, Neale PG, Berglund LJ, Berger RA. Analysis of dynamic distal radioulnar convergence after ulnar head resection and endoprosthesis implantation. *J Hand Surg Am* 2002;27(03):425–434
- 8 Darrach W. Partial excision of lower shaft of ulna for deformity following Colles's fracture. 1913. *Clin Orthop Relat Res* 1992;(275):3–4
- 9 Bell MJ, Hill RJ, McMurtry RY. Ulnar impingement syndrome. *J Bone Joint Surg Br* 1985;67(01):126–129
- 10 Watson HK, Ryu JY, Burgess RC. Matched distal ulnar resection. *J Hand Surg Am* 1986;11(06):812–817
- 11 Swanson AB. Implant arthroplasty for disabilities of the distal radioulnar joint. Use of a silicone rubber capping implant following resection of the ulnar head. *Orthop Clin North Am* 1973;4(02):373–382
- 12 Scheker LR, Babb BA, Killion PE. Distal ulnar prosthetic replacement. *Orthop Clin North Am* 2001;32(02):365–376, x
- 13 Warlop J, Nuffel MV, Smet L, Degreef I. Midterm functional outcomes of the linked semiconstrained distal radioulnar joint prosthesis. *J Wrist Surg* 2021;11(04):335–343
- 14 Moulton LS, Giddins GEB. Distal radio-ulnar implant arthroplasty: a systematic review. *J Hand Surg Eur Vol* 2017;42(08):827–838
- 15 Reissner L, Böttger K, Klein HJ, Calcagni M, Giesen T. Midterm results of semiconstrained distal radioulnar joint arthroplasty and analysis of complications. *J Wrist Surg* 2016;5(04):290–296
- 16 Kakar S, Fox T, Wagner E, Berger R. Linked distal radioulnar joint arthroplasty: an analysis of the APTIS prosthesis. *J Hand Surg Eur Vol* 2014;39(07):739–744
- 17 Bizimungu RS, Dodds SD. Objective outcomes following semiconstrained total distal radioulnar joint arthroplasty. *J Wrist Surg* 2013;2(04):319–323
- 18 Savvidou C, Murphy E, Mailhot E, Jacob S, Scheker LR. Semiconstrained distal radioulnar joint prosthesis. *J Wrist Surg* 2013;2(01):41–48
- 19 Laurentin-Pérez LA, Goodwin AN, Babb BA, Scheker LR. A study of functional outcomes following implantation of a total distal radioulnar joint prosthesis. *J Hand Surg Eur Vol* 2008;33(01):18–28
- 20 Zimmerman RM, Jupiter JB. Outcomes of a self-constrained distal radioulnar joint arthroplasty: a case series of six patients. *Hand (N Y)* 2011;6(04):460–465
- 21 Scheker LR. Implant arthroplasty for the distal radioulnar joint. *J Hand Surg Am* 2008;33(09):1639–1644
- 22 Amundsen A, Rizzo M, Berger RA, Houdek MT, Frihagen F, Moran SL. Twenty-year experience with primary distal radioulnar joint arthroplasty from a single institution. *J Hand Surg Am* 2023;48(01):53–67
- 23 Brannan PS, Ward WA, Gaston RG, Chadderdon RC, Woodside JC, Connell B. Two-year clinical and radiographic evaluation of Scheker prosthesis (Aptis) distal radioulnar joint arthroplasty. *J Hand Surg Am* 2022;47(03):290.e1–290.e11
- 24 Pääkkönen M. Complications of Scheker semiconstrained distal radioulnar joint arthroplasty in a low-volume unit. *Hand Surg Rehabil* 2022;41(04):441–444
- 25 Fuchs N, Meier LA, Giesen T, Calcagni M, Reissner L. Long-term results after semiconstrained distal radioulnar joint arthroplasty: a focus on complications. *Hand Surg Rehabil* 2020;39(03):186–192
- 26 Lans J, Chen SH, Jupiter JB, Scheker LR. Distal radioulnar joint replacement in the scarred wrist. *J Wrist Surg* 2019;8(01):55–60
- 27 DeGeorge BR Jr, Berger RA, Shin AY. Constrained implant arthroplasty for distal radioulnar joint arthrosis: evaluation and management of soft tissue complications. *J Hand Surg Am* 2019;44(07):614.e1–614.e9
- 28 Bellevue KD, Thayer MK, Pouliot M, Huang JI, Hanel DP. Complications of semi constrained distal radioulnar joint arthroplasty. *J Hand Surg Am* 2018;43(06):566.e1–566.e9
- 29 Oonk JGM, Dobbe JGG, Strijkers GJ, Van Rijn SK, Streekstra GJ. Kinematic analysis of forearm rotation using four-dimensional computed tomography. *J Hand Surg Eur Vol* 2022;12:17531934221142520
- 30 MacDermid JC, Tottenham V. Responsiveness of the disability of the arm, shoulder, and hand (DASH) and patient-rated wrist/hand evaluation (PRWHE) in evaluating change after hand therapy. *J Hand Ther* 2004;17(01):18–23
- 31 Clavien PA, Barkun J, de Oliveira ML, et al. The Clavien-Dindo classification of surgical complications: five-year experience. *Ann Surg* 2009;250(02):187–196
- 32 Nakamura T. Surgeons' level of expertise. *J Wrist Surg* 2020;9(03):185–185