



# An Account of a Giant Adolescent Vulvar Lipoma

Garima Vats<sup>1</sup> Aureen DCunha<sup>2</sup> Sandeep B. Rai<sup>2</sup> U. Raghuraj<sup>3</sup>

<sup>1</sup>K. S. Hegde Medical Academy, Mangaluru, Karnataka, India

<sup>2</sup>Department of Pediatric Surgery, K. S. Hegde Medical Academy, Mangaluru, Karnataka, India

<sup>3</sup>Department of Radiodiagnosis, K. S. Hegde Medical Academy, Mangaluru, Karnataka, India

Address for correspondence Aureen DCunha, MS, MCh, Department of Pediatric Surgery, K. S. Hegde Medical Academy, Mangaluru 575018, Karnataka, India (e-mail: aureen\_d@yahoo.com).

J Health Allied Sci<sup>NU</sup> 2024;14:436–439.

## Abstract

### Keywords

- ▶ lipoma
- ▶ vulva
- ▶ labia majora
- ▶ vulvar lipoma
- ▶ benign tumor

Though they are commonly known as “universal tumors,” lipomas are rarely found in the vulva. In this report, we discuss the case of a 15-year-old girl who presented with an enormous (26.5 × 21.5 × 6.5 cm) left labial swelling that had been progressively enlarging for a year and had led to extensive distortion of the vulvar anatomy. Following imaging, surgical excision with vulvar reconstruction was performed focusing on esthesis and function. Pathological examination confirmed the clinical and radiological diagnosis of a lipoma. The patient is doing clinically well at 1 year of follow-up with significant improvement in her academic performance and self-esteem.

## Case Report

Lipomas though the most common benign soft tissue tumors of mesenchymal origin, are rarely found in the vulva.<sup>1–4</sup> They are commonest in the fourth to sixth decade of life<sup>2</sup> and more often noted in the right labia majora.<sup>3</sup> Owing to the rarity of their occurrence and delay in seeking medical care due to associated social stigma in this part of the world, they often pose a diagnostic and therapeutic dilemma to the surgeon. We here discuss the case of an adolescent female who presented with an enormous (26.5 × 21.5 × 6.5 cm) vulvar lipoma and had a satisfying clinical and esthetic surgical outcome.

A 15-year-old girl presented to the pediatric surgical outpatient department after claiming to have recently noticed a left-sided vulvar mass that had grown in size over the last 1 year. She complained of a dragging type of pain and discomfort while walking due to the giant hanging mass. She was not sexually active, and she had normal menstrual cycles. On careful enquiry, her mother disclosed that her left labia majora was larger than the right since birth. The patient later revealed that the reason she did not seek medical attention earlier was that she was embarrassed to discuss the issue with her family.

On inspection, a soft to firm, nontender, pedunculated swelling of size 26 × 20 cm involving the left inguinolabial region was noted with stretched skin and sparse hair distribution over it (▶**Fig. 1**). There was a cough impulse present over the inguinal component; however, it was in continuity with the rest of the swelling and was not reducible. The posteroinferior aspect had some skin discoloration and thickening. The vulvar anatomy was markedly distorted owing to the size, the labia minora could not be separately demarcated, and the clitoris was completely hidden.

A magnetic resonance imaging (MRI) was done to characterize the lesion, delineate the anatomy, and rule out differentials including a soft tissue sarcoma and an omentocoele. The MRI showed a large predominant fat signal intensity lesion which confirmed the clinical suspicion of a lipoma (▶**Fig. 2**). The patient was advised to allow growth of her pubic hair to guide surgical reconstruction of the labia minora and majora. Six weeks later, she underwent surgical excision (▶**Fig. 3**) with labial reconstruction (▶**Fig. 4**). The histopathology report was consistent with that of a lipoma. The perioperative period was uneventful, and she is doing well at 1 year of follow-up with significant improvement in her academic performance and self-esteem.

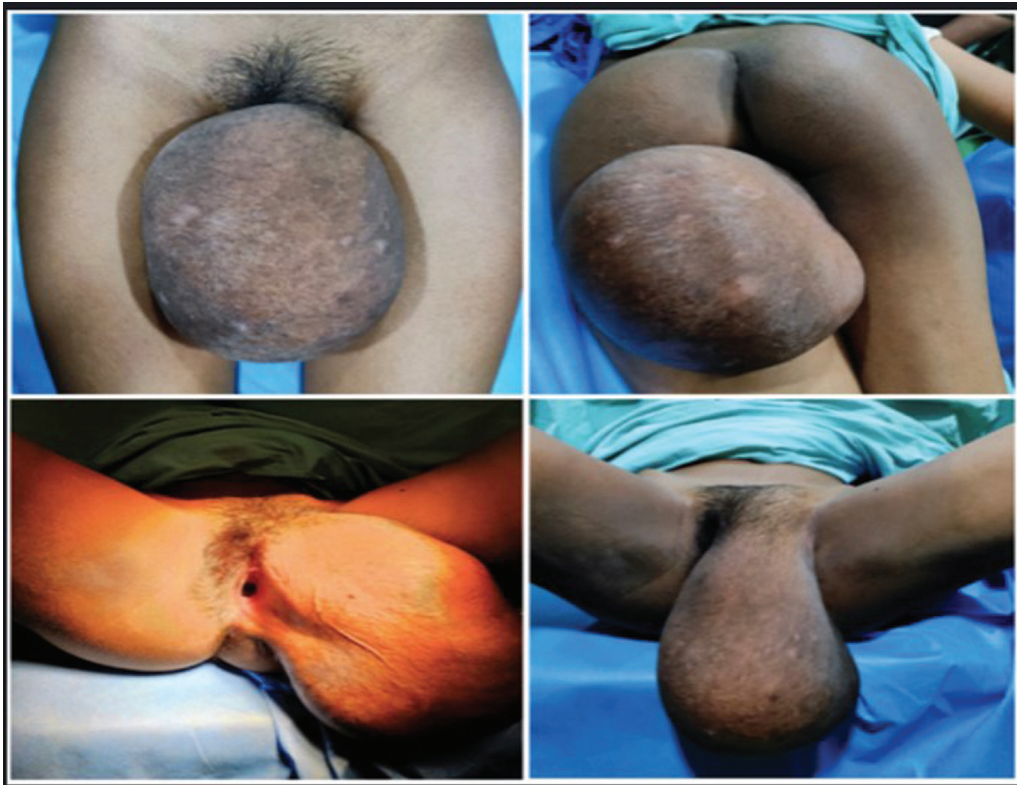article published online  
August 28, 2023

DOI <https://doi.org/10.1055/s-0043-1772822>.  
ISSN 2582-4287.

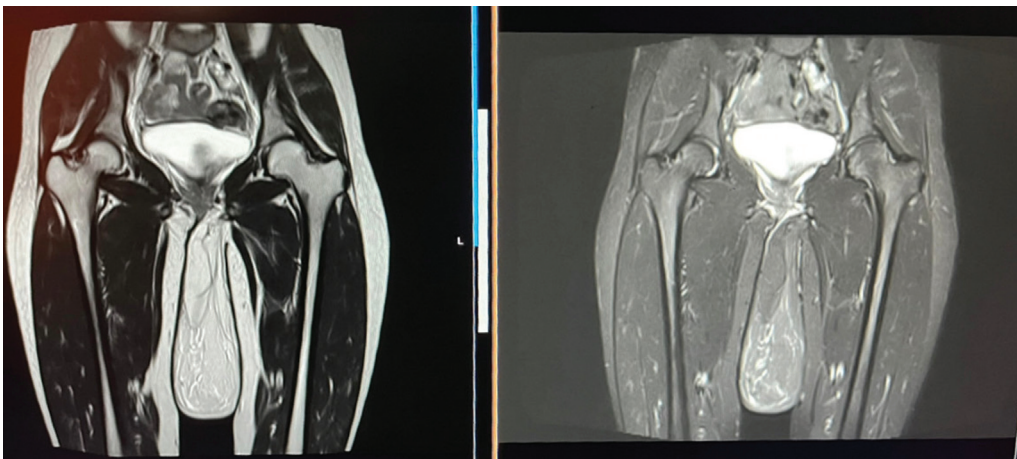
© 2023. The Author(s).

This is an open access article published by Thieme under the terms of the Creative Commons Attribution License, permitting unrestricted use, distribution, and reproduction so long as the original work is properly cited. (<https://creativecommons.org/licenses/by/4.0/>)

Thieme Medical and Scientific Publishers Pvt. Ltd., A-12, 2nd Floor, Sector 2, Noida-201301 UP, India



**Fig. 1** Clinical photographs showing the swelling.

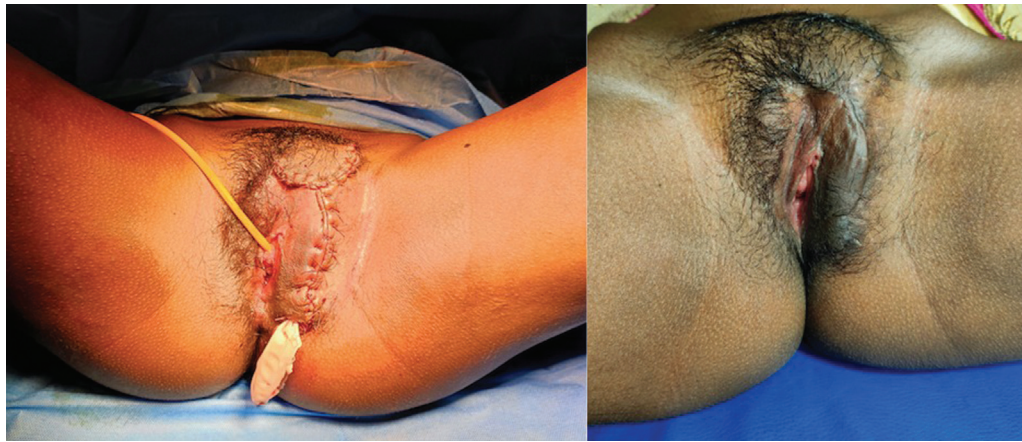

**Fig. 2** T2 (fat enhancing) and T2 turbo inversion recovery magnitude (fat suppressed) coronal views of the lesion on MRI.

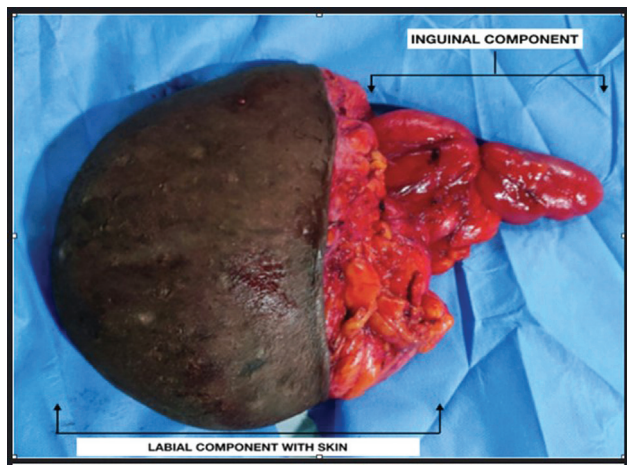
## Discussion

Though more common in the fourth to sixth decade,<sup>2,5</sup> vulvar lipomas can occur in any age group ranging from newborns<sup>3</sup> to the elderly.<sup>6</sup> The etiology however depends on the age of presentation. Those seen in the newborn period and pediatric population are congenital, whereas those presenting in adulthood are usually acquired due to tissue trauma from chronic irritation.<sup>2,5</sup> Our patient had a combination of these factors, the increase in size probably being due to repeated minor trauma from the size being so large.

Vulvar lipomas are known to grow to enormous sizes with pedunculation owing to the combined effect of gravity and delay in seeking medical attention. Patients hailing from socially conservative backgrounds often have inhibitions in seeking medical care for problems concerning the genitalia. Many a times they report to the hospital only when they face significant interference with activities of daily living. The previously largest reported vulvar lipomas in literature had a maximum diameter of 20<sup>7</sup> and 23 cm,<sup>8</sup> respectively. This patient's lipoma was 26.5 cm in its greatest dimension which makes it the largest documented vulvar lipoma among



**Fig. 3** Postoperative images of the vulva immediately and 1 month after the surgery.



**Fig. 4** Excised lipomatous lesion.

both adults and children. Only nine case reports have been published regarding presentation of a vulvar lipoma in the pediatric age group till date, all with sizes much smaller than that in the present case (► **Table 1**).

Currently, there is no literature to suggest why the right labia is more common than the left. We postulate that this has to do with canal of Nuck abnormalities being more common on the right side.<sup>14,15</sup> Further studies however will be required to confirm whether there is actually a relation between the two.

The role of imaging lies in ruling out other differentials while delineating the extent and revealing a possible malignancy (in which case a fine needle aspiration/biopsy would be needed to confirm the diagnosis). The common differentials to be considered include Bartholin's cysts, cysts of the canal of Nuck, inguinal hernias, and rarely liposarcomas.<sup>2-4</sup>

**Table 1** Other pediatric vulvar lipomas found in the literature

Author	Number of cases	Age at diagnosis (y)	Side of the lesion	Maximum dimensions (cm)	Duration of symptoms
Dewhurst (1977) <sup>9</sup>	1	Not specified	Right	Not specified	Not specified
Tsoutsoplides (1980) <sup>10</sup>	1	Infancy	Right	Not specified	Since birth
Fukamizu et al (1982) <sup>11</sup>	1	Infancy	Right	5.5	Since birth
Van Glabeke et al (1999) <sup>12</sup>	1	Infancy	Clitoral prepuce	Not specified	Since birth
Oh et al (2009) <sup>3</sup>	7	7	Right	Not specified	Since birth
		10	Right	Not specified	
		8	Right	Not specified	
		7	Right	Not specified	
		11	Right	Not specified	
		9	Right	4	
		10	Left	7	
Numajiri et al (2011) <sup>13</sup>	2	4	Right	2	Since birth
		7	Right	3.2	
Jóźwik et al, 2014 <sup>2</sup>	1	19	Right	16	4 y
Lee and Chung 2008 <sup>5</sup>	1	17	Right	8.2	1 y
O'Brien et al (2018) <sup>7</sup>	1	14	Left	20	Not specified
Garima et al, 2023 (current case)	1	15	Left	26	1 y



Computed tomography scans and MRI have been used with greater frequency in the recent past for better characterization of the lesions and identifying the proximity of surrounding structures.<sup>1-3,5,7</sup> Ultimately, histopathology confirms the diagnosis and rules out malignancy. When large, a detailed multisectional examination is crucial.

Universally, surgical excision is considered to be the ideal modality of treatment<sup>1,3</sup>; however, reconstruction of the vulva needs to be given consideration, especially in the pediatric and adolescent age group where there is a significant psychological impact on the patient. Utilizing the pubic hair growth pattern post puberty comes in handy when planning the surgical incision. We found that allowing growth of pubic hair before surgery helped delineate the boundaries of the labia majora and minora. Hair provides the additional advantage of masking the scar and enhancing cosmesis. The patient is doing clinically well at 1 year of follow-up with significant improvement in her confidence and self-esteem.

## Conclusion

The vulva is a rare location for lipomas more so in the pediatric population. When social stigma is a concern, there is delay in seeking medical care leading to progression of growth thereby making management challenging. Even with a delayed presentation, a complete surgical excision with a cosmetically acceptable outcome can be achieved.

### Implications and Contributions

Given the importance of esthesia and functionality in the world today, we present the case of the largest vulvar lipoma documented in the literature, summarizing the presentation, workup, recommended management, and proposed etiology of the condition.

### Patient Consent

Informed written patient consent was taken as personal details and clinical photographs have been included.

### Conflict of Interest

None declared.

## References

- Li S, Haag T, McWhorter J, Ge L, Carlan SJ. Unilateral giant vulvar lipoma with fat necrosis not visualized on magnetic resonance imaging (MRI). *Am J Case Rep* 2019;20:1760-1764
- Jóźwik M, Kołodziejczak M, Klonowska-Dziatkiewicz E, Jóźwik M. Giant vulvar lipoma in an adolescent girl: a case study and literature review. *J Pediatr Adolesc Gynecol* 2014;27(05):e117-e119
- Oh JT, Choi SH, Ahn SG, Kim MJ, Yang WI, Han SJ. Vulvar lipomas in children: an analysis of 7 cases. *J Pediatr Surg* 2009;44(10):1920-1923
- Kehagias DT, Smyrniotis VE, Karvounis EE, Gouliamos AD, Creatas G. Large lipoma of the vulva. *Eur J Obstet Gynecol Reprod Biol* 1999;84(01):5-6
- Lee JH, Chung SM. Large vulvar lipoma in an adolescent: a case report. *J Korean Med Sci* 2008;23(04):744-746
- Sukgen G. A case report: the third-largest case in the literature of a vulvar lipoma. *Gynecol Minim Invasive Ther* 2020;9(04):234-236
- O'Brien C, Hoover K, Arbuckle J. Giant vulvar lipoma in adolescent. *J Pediatr Adolesc Gynecol* 2018;31(02):211
- Szanecki W, Golonka A, Pajak J, et al. Two unusual cases: vulvar lipoma - description of the largest case in literature. *Developing myoma with the longest pedicle. Eur J Gynaecol Oncol* 2017;38(02):286-289
- Dewhurst CJ. Tumors of the genital tract in childhood and adolescence. *Clin Obstet Gynecol* 1977;20(03):595-606
- Tsoutsoplides GC. Surgical management of extensive congenital hemangiofibrolipoma of the vulva in an infant. *Am J Obstet Gynecol* 1980;136(02):260-261
- Fukamizu H, Matsumoto K, Inoue K, Moriguchi T. Large vulvar lipoma. *Arch Dermatol* 1982;118(06):447
- Van Glabeke E, Audry G, Hervet F, Josset P, Gruner M. Lipoma of the preputium clitoridis in neonate: an exceptional abnormality different from ambiguous genitalia. *Pediatr Surg Int* 1999;15(02):147-148
- Numajiri T, Nishino K, Sowa Y, Konishi K. Congenital vulvar lipoma within an accessory labioscrotal fold. *Pediatr Dermatol* 2011;28(04):424-428
- Chawla S. Inguinal hernia in females. *Med J Armed Forces India* 2001;57(04):306-308
- Chan D, Kwon JK, Lagomarsino EM, Veltkamp JG, Yang MS, Pfeifer CM. Canal of Nuck hernias. *Acta Radiol Open* 2019;8(12):2058460119889867