



# Hypereosinophilia Syndrome: Myriad Presentation—A Case Report

Mansi Patel<sup>1</sup> Divit Shah<sup>1</sup> Sujal Patel<sup>1</sup> Sourya Acharya<sup>1</sup> Sunil Kumar<sup>1</sup> Samarth Shukla<sup>2</sup>

<sup>1</sup>Department of Medicine, Jawaharlal Nehru Medical College, Datta Meghe Institute of Higher Education and Research (Deemed to be university), Maharashtra, India

<sup>2</sup>Department of Pathology, Jawaharlal Nehru Medical College, Datta Meghe Institute of Higher Education and Research (Deemed to be university), Maharashtra, India

Address for correspondence Sunil Kumar, MD, PhD, Department of Medicine, Jawaharlal Nehru Medical College, Jawaharlal Nehru Medical College, Datta Meghe Institute of Higher Education and Research (Deemed to be university), Wardha 442001, Maharashtra, India (e-mail: sunilkumarmed@gmail.com).

J Health Allied Sci<sup>NU</sup> 2024;14:431–435.

## Abstract

Hypereosinophilic syndrome is a myeloproliferative disorder that is distinguished with the presence of eosinophilia, which is an absolute eosinophil level of more than 1500/ $\mu$ L for no less than 6 months, no recognized cause for eosinophilia, and clear organ involvement characteristics. But, in some cases where patients require therapy to decrease eosinophil counts due to severe symptoms, a lower time period of hypereosinophilic is also admissible. In this case series, we have included three cases in which first case presented with the features of diarrhea, nausea, and decreased appetite who underwent colonoscopy and was diagnosed as a case of eosinophilic colitis. The second patient was a female came with abdominal pain and burning micturition, who was having eosinophilia on blood count examination and was diagnosed as a case of eosinophilic cystitis. Third case was young female who was diagnosed as eosinophilic endocarditis on two-dimensional echocardiography having dyspnea and rash and high eosinophil count on blood smear. All the three patients were started on steroids, who recovered well with medication and were discharged for follow-up after 7 days with complete blood count.

## Keywords

- ▶ hypereosinophilia
- ▶ gastroenteritis
- ▶ cystitis
- ▶ endocarditis

## Introduction

A rare and diverse group of conditions known as hypereosinophilic syndromes (HES) is defined as chronic and marked blood eosinophilia ( $> 1.5 \times 10^9/L$  for more than six consecutive months) along with evidence of eosinophil-induced organ damage after other causes of hypereosinophilia (HE), such as allergies, parasitic diseases, and malignant disorders, have been ruled out.<sup>1</sup> Young to middle-aged patients with a variety of indications that can appear simultaneously or separately are most susceptible to HES. The onset could be abrupt and severe, leading to issues with the heart, gastrointestinal system, nervous system, or thrombosis.<sup>1</sup> Eosinophilic gastroenteritis is characterized by the triad of peripheral eosinophilia, alterations in gastrointestinal function (such as dyspepsia, obstruc-

tion, diarrhea, and ascites), and exclusion of other illnesses with peripheral eosinophilia (such as parasite infections and drug-induced causes).<sup>2</sup>

The rare and poorly understood clinicopathologic condition known as eosinophilic cystitis can also manifest in the postpartum period. It is characterized by a significant local eosinophilic infiltration in all the three layers of bladder wall. Urinary frequency (67%), dysuria (62%), gross/microscopic hematuria (68%), suprapubic discomfort (49%), and urine retention (10%) are the most typical presenting symptoms, according to Neeman et al.<sup>3</sup>

HE is a systemic disease that can show itself in several ways. Eosinophilic endocarditis, a rare consequence of HE, results in endomyocardial eosinophil infiltration and

article published online  
August 24, 2023

DOI <https://doi.org/10.1055/s-0043-1772743>.  
ISSN 2582-4287.

© 2023. The Author(s).

This is an open access article published by Thieme under the terms of the Creative Commons Attribution License, permitting unrestricted use, distribution, and reproduction so long as the original work is properly cited. (<https://creativecommons.org/licenses/by/4.0/>)

Thieme Medical and Scientific Publishers Pvt. Ltd., A-12, 2nd Floor, Sector 2, Noida-201301 UP, India

degranulation, causing fibrosis and constrictive ventricular filling. Left or biventricular involvement occurs more commonly.

Eosinophils can harm target organs in a variety of ways, with the skin, heart, lungs, gastrointestinal tract, genitourinary tract, and central and peripheral nervous systems accounting for more than 50% of cases.<sup>4,5</sup> Other frequent side effects include hepato and/or splenomegaly, eosinophilic gastroenteritis, and coagulation issues.<sup>5</sup>

Three young people who presented with eosinophilic gastritis, cystitis, and endocarditis are emphasized in this case series.

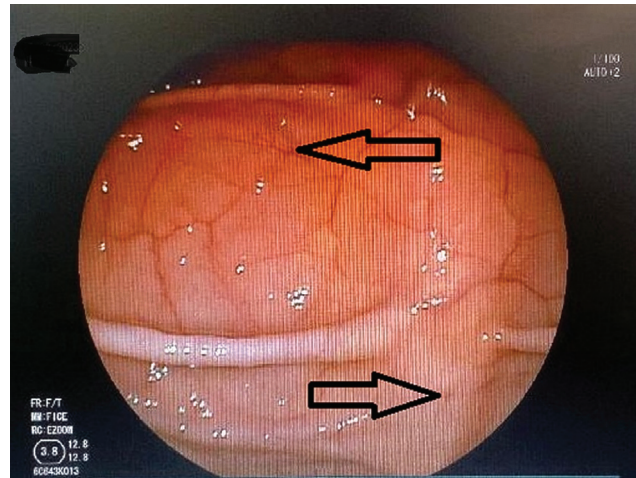
## Case 1

We present a case of a 36-year-old male who came to our outpatient department with complaints more than 20 episodes of diarrhea per day for 2 months that was at times mixed with blood. The patient also had complaints of pain in the lower abdomen for 3 weeks with decreased appetite and nausea. He was initially taken to a private practitioner and was given medication for his symptoms that provided no significant relief, so he was referred to our hospital.

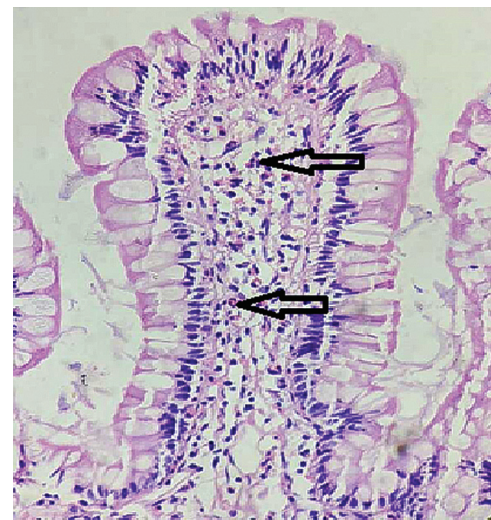The patient was dehydrated at arrival, as evidenced by his low blood pressure of 90/60 mm Hg and a heart rate of 140 beats per minute. His body temperature was normal. Clinical examination showed only mild lower abdominal tenderness. Blood counts were sent that revealed total leucocyte count of  $43.0 \times 10^3$  cells/mm<sup>3</sup> with markedly raised level of eosinophils (absolute eosinophil count—2,236 /mm<sup>3</sup>). Other serum chemistries including liver and kidney function showed no abnormality. Tests for viral hepatitis, human immunodeficiency virus (HIV), and autoimmune conditions showed negative results. Stool microscopy confirmed the presence of blood but did not show any presence of ova, cysts, or any sign of parasitic infestation. Blood culture showed no growth of pathological organisms. Chest radiography and ultrasound of abdomen were found to be normal. There were no serious food or medication allergies in the patient's past. He also had no recent drug history and was not on any medications prior to developing present complaints.

A colonoscopy was planned after a gastroenterologist referral that revealed multiple erosions with scattered ulcers involving entire colon, rectum, and extending up to terminal ileum as shown in ► **Fig. 1**. Biopsy from ileum and colon was taken and sent for histopathological examination that revealed inflammatory infiltrates predominantly eosinophils along with lymphocytic infiltrates; section also shows unremarkable submucosal glands suggestive of eosinophilic enteritis. As diagnosis was confirmed, so bone marrow examination was not done.

Patient was started on oral prednisolone as per his weight suspecting eosinophilic gastroenteritis. After 2 days, patient had dramatic relief in symptoms including complete relief in diarrhea and improvement in his appetite. Biopsy results as shown in ► **Fig. 2** confirmed the diagnosis and discharge of the patient was done on oral prednisolone, with the dosage gradually tapered. After 2 weeks of corticosteroid therapy,



**Fig. 1** Colonoscopy showing multiple erosions.

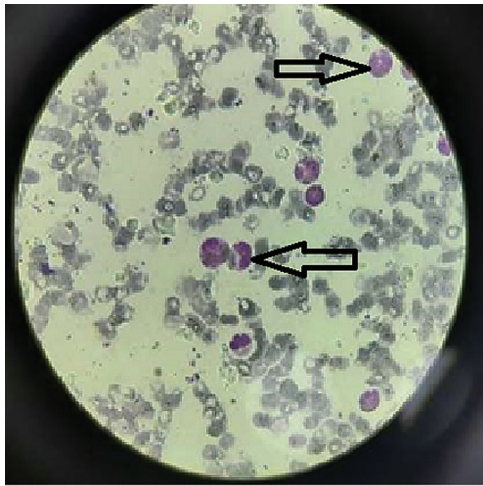

**Fig. 2** Sections stained with hematoxylin and eosin stain (high power view 40x) showing unremarkable villi, deeper tissue showing fibrocollagenous stroma with extensive acute on chronic inflammatory infiltrates predominantly eosinophils along with lymphocytic infiltrates, and section also showing unremarkable submucosal glands, suggestive of Eosinophilic enteritis (empty arrow).

the patient had no symptoms and repeat complete blood count showed a normal white blood cell count with a normal eosinophil level. Patient was followed up after a period of 1 month and was doing well.

## Case 2

A 41-year-old female patient presented to medicine outpatient department with a history of abdominal pain for the last 7 days; pain was diffuse and dull aching and more around the umbilicus and she had two to three episodes of vomiting for the last 2 days, which was containing food particles and nonbilious and not containing blood. Patient also had a history of fever that was subsided from past 3 days, which was low grade in nature and not associated with chills or rigor. Patient did not have any history of asthma,



**Fig. 3** Peripheral smear of the patient showed eosinophilia (empty arrow).

tuberculosis, diabetes mellitus, or systemic hypertension or any other co morbidities. Patient denied of having any allergies to drugs and other substances. Patient did not have any prior history of hospitalization. General condition at presentation was stable, febrile on touch with temperature of 99°F, pulse of 92 beats per minute, blood pressure of 100/70 mm Hg, respiratory rate of 20/min, and abdominal examination showed suprapubic tenderness and guarding with no rigidity or organomegaly. Respiratory system examination and cardiac examination were within normal limits. Ultrasound of abdomen was done which showed normal study.

Blood counts were sent that revealed total leucocyte count of  $32.4 \times 10^3$  cells/mm<sup>3</sup> with markedly raised level of eosinophils (absolute eosinophil count—6,500 /mm<sup>3</sup>) that is shown in ►Fig. 3.

Peripheral smear examination was suggestive of absolute eosinophil count of 6,500. Other biochemical and microbiological reports were normal. Patient was advised for bone marrow but she denied to give consent for the same. Also, viral markers were sent for ruling out hepatitis or HIV that came negative. Urine routine microscopy was done that was suggestive of plenty of epithelial cells, no pus cells, or ova or any parasites. We could not take biopsy from cystitis as patient was postpartum and breastfeeding. Patient was started with antibiotics, steroid and supportive treatment. Patient improved drastically by clinical profile and laboratory parameters. Patient was discharged with eosinophil count of 4 and she was doing well on follow-up after 1 month with 5 mg of prednisolone.

### Case 3

A 25-year-old tribal woman appeared with a widespread rash and 1 week of increasing dyspnea on exertion. Her palms and soles were spared as the rash, which started on her neck, moved down her body. In addition, she experienced dyspnea symptoms with effort without any prior restrictions. She ruled out any recent travel or medical encounters.

The patient denied having any chest pain or a cough that was productive. She had been on olanzapine for a year for schizophrenia and bipolar disorder, according to her medical history, but no regular follow-up care was reported, so she kept taking olanzapine once daily.

The patient was afebrile, with a blood pressure reading of 100/60 mm Hg, a pulse rate of 114, an oxygen saturation of 94% on room air, and a respiratory rate of 26 breaths per minute at the time of presentation. Her pulmonary examination was normal, and her cardiovascular assessment revealed nothing unusual than tachycardia. She did not have lower extremity edema or jugular venous distention. Lymphadenopathy was not present. During her physical examination, a generalized, maculopapular rash that spared her palms and soles were also noticeable. As indicated in ►Fig. 4, laboratory tests revealed an eosinophil count of 4,500/L and a total blood count significant for white blood cells of  $34.2 \times 10^3$ /L. Troponins I was normal.

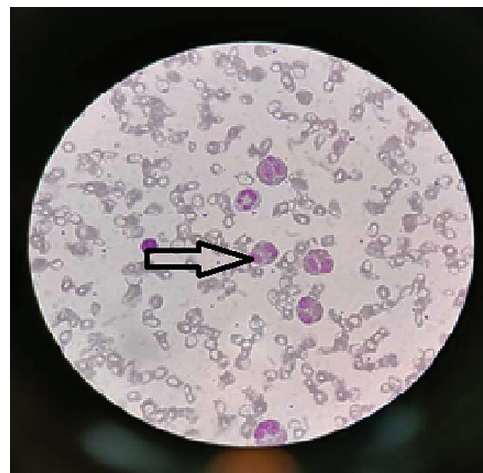
For influenza A, our patient tested negative. The HIV was negative by voluntary counseling and testing center. Panel for hepatitis was negative. It was negative for antinuclear antibodies. Bone marrow examination was normal.

T-wave inversions and nonspecific ST-segment alterations were visible on the electrocardiogram. As seen in ►Fig. 5, transthoracic echocardiography revealed no left ventricular involvement and a dilated right ventricle with a significant ( $2.9 \times 2.8$  cm) echo density fixed to the right apex, consistent with Loeffler endocarditis. Transthoracic echocardiography additionally revealed a flattened septum and mild tricuspid regurgitation.

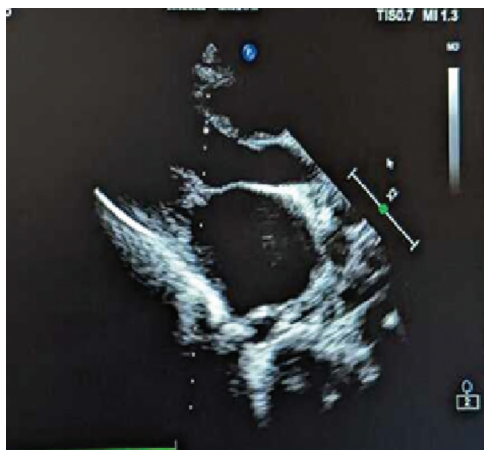Methylprednisolone was administered intravenously to this patient. Her dyspnea, rash, and eosinophilia all subsided.

The etiology was endocarditis caused by olanzapine-induced HE, according to our workup, which was described above. Our patient has been taking olanzapine for the past year without routine follow-up. Olanzapine-induced HE is an uncommon and poorly understood condition.

High-dose steroids helped help our patient's symptoms, and she was released with prednisone taper instructions and



**Fig. 4** Peripheral smear of the patient showed eosinophilia (empty arrow).



**Fig. 5** Transthoracic echocardiography demonstrating a dilated right ventricle.

appointments for follow-up care with our outpatient cardiology clinic for serial echocardiography and hematology for additional workup. Additionally, our case study emphasizes the significance of early disease detection. Patient was doing well both clinically and biochemically (eosinophil count was 3) after 1 month of follow-up.

Laboaratory parameter as complete blood counts of all the threes cases has been highlighted in ► **Table 1**:

## Discussion

HES are characterized on the basis of (1) HE, more than 1,500 cells/mm<sup>3</sup> on two independent occasions separated by at least one month; (2) eosinophil-caused organ damage; and (3) exclusion of other organ damage causes.<sup>1</sup>

HES is rare, with a frequency range of 0.36 to 6.3 per 1,00,000.<sup>3</sup> HES are often diagnosed between the ages of 20 and 50; however, cases in the senior population, like those of our patient, have also been documented.<sup>4</sup> HES frequently have an impact on the skin, lungs, heart, spleen, and nervous system.<sup>5</sup> In the case of our patient, the patient reported having a temperature and experiencing stomach pain, and an examination of the urine revealed many pus cells, which was indicative of cystitis.

One of the standard HES criteria is eosinophilia, but this does not always indicate how much an organ has been affected. Eosinophilic degranulation, as opposed to eosinophilia, indicates obvious organ involvement and necessitates quick medical care. Studies both in vivo and in vitro have shown that after being secreted, these cationic proteins exert a variety of proinflammatory and cytotoxic effects.<sup>3</sup> Despite the fact that eosinophilic degranulation is typically thought to be a hallmark of eosinophil activation, there have been no reports that show it to occur in eosinophilic colitis (EC). It may be required to conduct more study on the pathophysiology of EC and the role of eosinophilic degranulation, especially in patients who may have HES as an underlying condition.<sup>2</sup> Eosinophilic degranulation in our patient was regarded to be a symptom of organ damage.

We looked through the literature to find patients with EC who may have had HES. Most of the individuals with either definite or probable HES were men. This is consistent with the observation that the male-to-female ratio for EC was 9:1 for HES. However, in our case series one patient was male and two patients were female, which may be chance. The typical systemic HES symptoms of fatigue, coughing, dyspnea, rash, and fever were not present in any of individuals.<sup>6,7</sup> Instead, dysuria and abdominal pain, both signs of cystitis and gastrointestinal eosinophilic illness were the presenting symptoms. Just 4.5% of instances were considered to involve an EC-related issue.<sup>8</sup> The patient's strange symptoms included ascites, granulomatous peritonitis involving the pylorus, and hepatic nodules. The prognosis for EC is reportedly better than that of HES. One case study included 83 adult EC patients, and 32 (or 39%) of them required no treatment.<sup>9</sup> According to a different analysis, 91 (77%) of 118 EC patients received treatment and recovered, with only 15 (13%) of them relapsing.<sup>10</sup>

We started treatment with prednisolone 30 mg/day. In a previous study of 188 individuals with HES, the maximum daily dose of prednisolone was 40 mg. Lessening the symptoms and maintaining low eosinophil counts were the goals of the treatment. Prednisolone 10 mg/day was the median maintenance dose in the same trial. Despite the fact that the symptoms returned once after stopping prednisolone, they improved when prednisolone was reintroduced at a lower dose together with an antiallergic drug. Mepolizumab, hydroxyurea, or

**Table 1** Complete blood counts of all the three case

Investigation	Case 1	Case 2	Case 3
Hemoglobin	10 g/dL	11 g/dL	10.8 g/dL
White blood cells	43.0 × 10 <sup>3</sup> /μL	32.4 × 10 <sup>3</sup> /μL	34.2 × 10 <sup>3</sup> /μL
Platelets	2.0 × 10 <sup>4</sup> /μL	2.75 × 10 <sup>4</sup> /μL	3.0 × 10 <sup>4</sup> /μL
Eosinophils	2236 /μL	6500 /μL	4500 /μL
Neutrophils	30.0 × 10 <sup>3</sup> /μL	20 × 10 <sup>3</sup> /μL	22 × 10 <sup>3</sup> /μL
Lymphocytes	15.8 × 10 <sup>3</sup> /μL	13 × 10 <sup>3</sup> /μL	12 × 10 <sup>3</sup> /μL
Monocytes	4.3 × 10 <sup>3</sup> /μL	0.2 × 10 <sup>3</sup> /μL	1.8 × 10 <sup>3</sup> /μL
Basophils	0.3 × 10 <sup>3</sup> /μL	0.0 × 10 <sup>3</sup> /μL	0.1 × 10 <sup>3</sup> /μL
Absolute eosinophil ratio	1933 cells/cumm	6360 cells/cumm	2450 cells/cumm

pegylated interferon is suitable choices for patients who do not respond to the necessary dose of steroids.<sup>10</sup>

## Conclusion

In the differential diagnosis of multisystem disorders, HES is infrequently used. Before idiopathic HES, a thorough and methodical workup is necessary to rule out hypereosinophilia. Most of the time, symptoms appear gradually, and eosinophilia may only be discovered by chance in a tiny percentage of patients. Due to the quick development of cardiovascular, genitourinary, and gastrointestinal problems, the initial signs are severe. The major therapy for HES continues to be steroids.

### Conflict of Interest

None declared.

## References

- 1 Klion A. Hypereosinophilic syndrome: current approach to diagnosis and treatment. *Annu Rev Med* 2009;60:293–306
- 2 Straumann A. Idiopathic eosinophilic gastrointestinal diseases in adults. *Best Pract Res Clin Gastroenterol* 2008;22(03):481–496
- 3 Neeman A, Shoenfeld Y, Eldar M, Delpre G, Leisser A, Pinkhas J. [Eosinophilic gastroenteritis]. *Harefuah* 1978;95(3-4):108
- 4 Shehwaro N, Langlois AL, Gueutin V, Izzedine H. Renal involvement in idiopathic hypereosinophilic syndrome. *Clin Kidney J* 2013;6(03):272–276
- 5 Kumar S, Diwan SK, Chillawar S, Shabarwal S, Goyal S, Jain S. Wegener's granulomatosis with peripheral eosinophilia in a young adult patient. *J Med* 2013;14(02):204–206
- 6 Khoury P, Makiya M, Klion AD. Clinical and biological markers in hypereosinophilic syndromes. *Front Med (Lausanne)* 2017;4:240
- 7 Duloher MM, Patel RR, Schneider F, Ryu JH. Lung involvement in hypereosinophilic syndromes. *Respir Med* 2011;105(01):114–121
- 8 Valent P, Klion AD, Horny HP, et al. Contemporary consensus proposal on criteria and classification of eosinophilic disorders and related syndromes. *J Allergy Clin Immunol* 2012;130(03):607–612.e9
- 9 Cheung CC, Constantine M, Ahmadi A, Shiao C, Chen LYC. Eosinophilic myocarditis. *Am J Med Sci* 2017;354(05):486–492
- 10 Crane MM, Chang CM, Kobayashi MG, Weller PF. Incidence of myeloproliferative hypereosinophilic syndrome in the United States and an estimate of all hypereosinophilic syndrome incidence. *J Allergy Clin Immunol* 2010;126(01):179–181