

MYCOSIS FUNGOIDES : A CASE REPORT

RAMESH CHANDRA, P. K. AGARWAL AND (MRS.) PADAM K. AGARWAL

SUMMARY

Twenty years follow-up of a case of Mycosis fungoides is being presented here where diagnosis could be established only after 13 years after the initial onset of symptoms. It is a rare condition affecting the skin which eludes diagnosis in its early stages.

The name Mycosis fungoides was coined by Alibert (1806) to indicate a somewhat mushroom like appearance of this cutaneous tumour. Symmers (1932) has termed it as a clinically and pathologically non-existent disorder. Willis (1960) has dismissed it as merely a manifestation of Hodgkin's disease or lymphosarcoma. Edelson (1974) considers that tumour cells are derived from T lymphocytes.

The disease may occur at any age but in great majority of cases its clinical onset is be-

tween 40-60 year. Males are more often involved than females in a ratio of 2 : 1.

The clinical manifestations of Mycosis fungoides have been divided into three stages:—

STAGE I : Erythema, Psoriasiform, Eczematoid stage.

STAGE II : Erythematous patch, plaque and nodular stage.

STAGE III : Tumours and ulcerations.

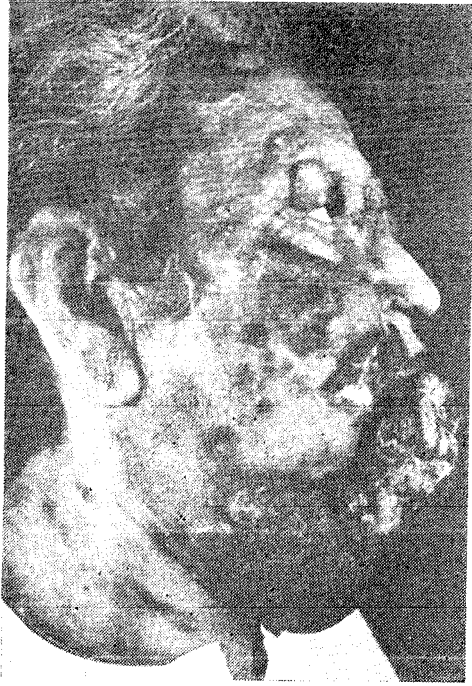The Sezary syndrome (Sezary, 1949) is a variant of Mycosis fungoides. The characteristic feature of this syndrome is the presence of Lutzner cells in blood, skin or rarely in bone marrow.



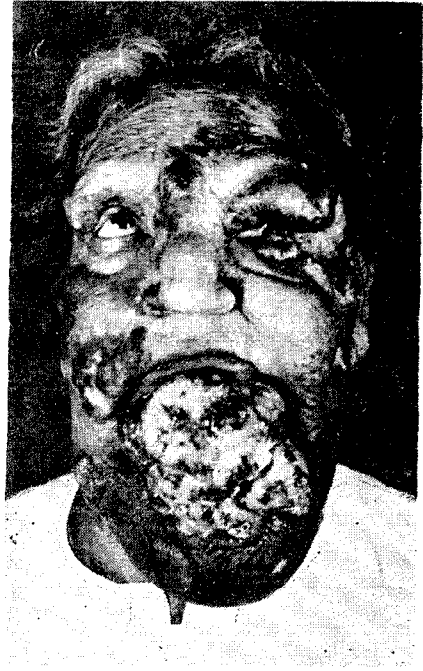
Fig. 1. Photograph showing the patient before the onset of the disease process.

Case Report

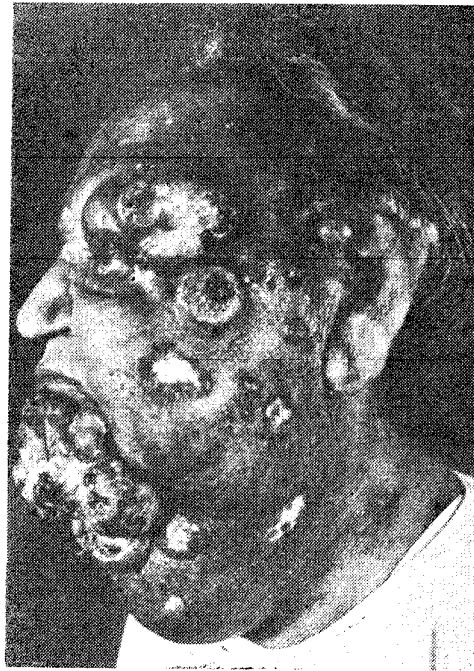A, 51 years old male doctor came for consultation to the plastic surgery department on 20-8-80 because he could no longer bear the agony of disfigurement. (Fig 2-a, b, c). He had a proliferative fungating mass of 4 months duration, over the chin and face having a size of $12 \times 7 \times 6$ cm. A double chin effect was quite evident. The left upper eyelid was extensively involved and there was chemosis of the palpebral conjunctiva. Non-involved areas of the body and face showed dark patches of pigmentation. Other similar but smaller facial lesions also developed in succession. Some of them showed evidence of healing in the central area by scarring and depigmentation while others were reshaping themselves. Discharge from the ulcers was muco-purulent and there was scanty slough on its surface. The biopsy



(a)



(b)

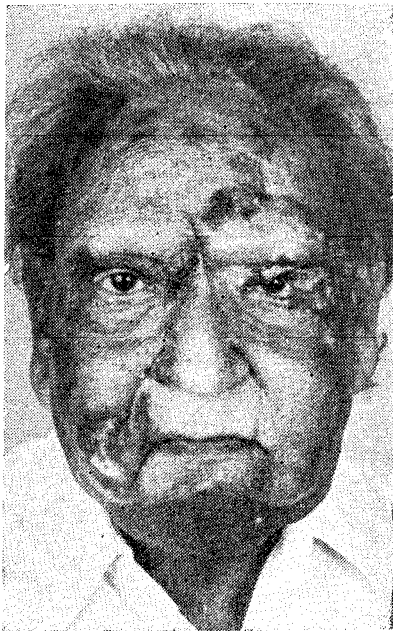

(c)

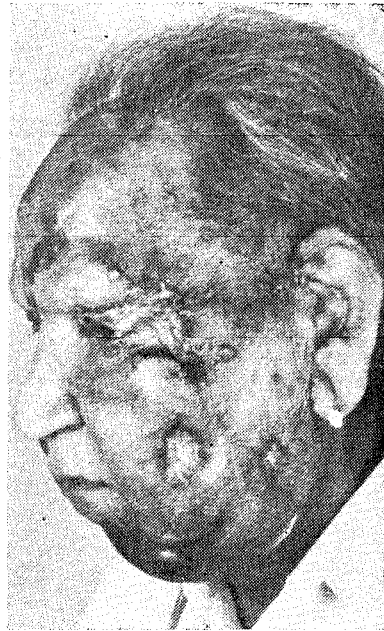Fig. 2. a, b, c. Showing the appearance of the patient before surgery.



(a)



(b)



(c)

Fig. 3. a, b, c. Showing the appearance of the patient after surgery.

was done in July 1980 and submitted for histopathological examination. He was labelled as having Mycosis Fungoides, (Fig. 3, 4). The regional lymph glands were not enlarged.

History of Past Illness

The patient had suffered from herpes zoster in 1960, when he was around 24 years old. He had no trouble before this whatsoever (Fig. 1). After this he had been having non-specific dermatitis, which responded to symptomatic treatment. In 1966, the dermatitis became more established and required treatment more often. A skin biopsy in 1971 was done and he was labelled as having Pityriasis rubra pilaris. Symptomatic treatment for allergic dermatitis and occasional skin infections continued. But he was not relieved.

Hence biopsy was repeated again in 1973. A definite diagnosis could not be established on histopathological examination. Skin, however, showed heavy infiltration by lymphocytes, histiocytes, plasma cells and a few foreign body giant cells. Biopsy had to be repeated again in March, 1980. Even this time a definite diagnosis could not be established. The picture was almost similar to the previous one. In April 1980, he noticed a crop of

sebaceous cysts developing over his facial skin. A month later (May, 1980) he also noticed the development of nodules in the skin which increased in size and assumed a flat hemispherical appearance. This time a bigger piece was excised for cosmetic reasons and for establishing a diagnosis. The histopathological report was that of Mycosis fungoides.

Investigations

Blood Examination revealed Eosinophilia (38%) only. The urine examination did not reveal any abnormality. W.R. and V. D. R. L. tests were negative. Radiological examination of the facial bones, skull bones and chest were normal.

Operation

The chin lesion was excised on 25-8-80, under General anaesthesia and the defect was repaired by a Bipedicle flap from the submental region (Fig 5-a, b, c). Other lesions were locally excised. A further operation had to be undertaken on 16-9-80 for excision of fresh lesions on the right side of the face. Further surgery was undertaken on the ophthalmic side for correction of the upper eyelid deformity on the left side. The L. P. S muscle was

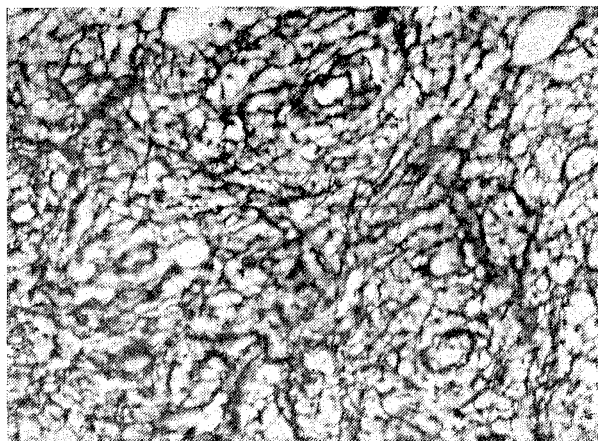


Fig. 4. Photomicrograph showing the characteristic appearance of the Mycosis fungoides (Reticulin pattern) with Verhoeff's stain, $\times 400$

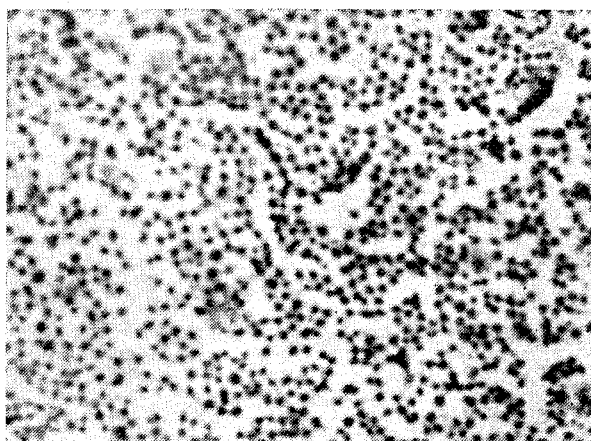


Fig. 5. Microphotograph of the skin biopsy showing that there is diffuse infiltration by small rounded cells having scanty amount of cytoplasm and darkly stained nuclei. (H:E $\times 400$).

identified. Normal conjunctiva of upper lid was retained. Rest of the mass and the tarsal plate was removed. The skin of the lid was replaced by a graft. Lower lid did not require any reconstruction. At a later stage the tarsal plate of both lids was reconstructed by silicon bands. Patient could resume his duties in October 1981 (Fig. 6).



Fig. 6. Showing the post-operative result.

Discussion

The aetiology of Mycosis fungoides is unknown but it is generally accepted that it is due to some abnormality of T-cells. Whether or not it is malignant from onset is not clear. (Allen, 1954; Cawley et al., 1951; Lever, 1961; Rouschkolb, 1961; Edelson, 1974 and Samman, 1986).

In early stages mycosis fungoides presents as psoriasis, parapsoriasis, eczema, seborrheic dermatitis, or neodermitis. Hence at this stage histology may not be very helpful in establishment of the diagnosis (Fromer, 1975). In the case presented here all the three stages of disease were seen. Multiple biopsies were done in 1971, 1973, March, 1980, April, 1980 and July, 1980. The diagnosis was established only after the last biopsy (Fig. 4 & 5). For early diagnosis, mycosis fungoides should be ruled out in a case of nonspecific inflammatory dermatitis which does not respond to appropriate treatment and in these cases repeated biopsy from different sites should be done (Fromer, 1975) to arrive at a conclusion.

Conclusion and Result

The result of a successful surgical treatment using a bipediced submental flap in a case of mycosis fungoides with proliferative growth affecting the chin and the rest of the face has been presented.

REFERENCES

1. ALIBERT, J. L. M. : Description des maladies de la peau observees a l'hopital Saint Louis, et exposition des meilleurs methodes & uivies pour leur traitement. Paris, Barrois, 1806.
2. ALLEN, A. C. : The Skin : A clinicopathologic Treatise, St. Louis, C. V. Mosby Co., 1954., p. 1010.
3. CAWLEY, E. P.; CURTIS, A. C. AND LEACH, J. E. K. : Is mycosis fungoides reticuloendothelial neoplastic entity? Arch. Dermatol 1951 ; 64 : 255.
4. EDELSON, R. L.; KIRKPATRICK, C. H.; SHEVACH, E. M.; SCHEIN, P. H.; SMITH, R. W.; GREEN, I. AND LUTZER, M. : Preferential cutaneous infiltration by neoplastic thymus-derived lymphocytes. Ann. Intern. Med., 1974., 80, 685.
5. EPSTEIN, E. H. JR.; LEVIN, D. L.; CROFT, J. D. JR. AND LUTZER, M. A. : Mycosis fungoides. Survival prognostic features, response to therapy, and autopsy findings. Medicine 1972, 51, 61.
6. FROMER, J. L. : Lymphoma cutis, Multiple Myeloma, Leukemia cutis, and Mycosis Fungoides : Dermatology ; Vol. 2, W. B. Saunders Company, Philadelphia, London, Toronto, 1975 p. 1427, & 1432.
7. LEVER, W. F. : Histopathology of the skin. 4th ed. Philadelphia, J. B. Lippincott Co., 1967, pp. 8, 48, 736-749, 794.
8. RAUSCHKOLB, R. R. : Mycosis fungoides discussion and clinical experience at Cleveland Metropolitan General Hospital. Archives of Dermatology and Syphilology 1961; 83 : 217.

9. SAMMAN, P. D. : Reticuloses, Text Book of Dermatology : 3rd edition, Vol. II ; C. B. S. Publishers and Distributors, New Delhi, 1986, p. 1542-1548.
10. SEZARY, A. : Une nouvelle reticulose cutanee ; la reticulose maligne leucemique a histio-monocytes monstrueux et a forme d'erythrodermie oedemateuse et pigmentee. Ann. Dermatol. Syphilology, 1949 : 9 : 5.
11. SYMMERS, D. : Mycosis fungoides as a clinical and pathologic non existant. Archives of Pathology, 1932 ; 25 : 1.
12. VIDAL, E. AND BROCO, L. : Etude sur le mycosis fungoide, France Med., 1885 (2) 946, 957, 969, 983, 993, 1005, 1018, 1885.
13. WILLIS, R. A. : Pathology of Tumours, 3rd. Ed : 1960, London; Butterworth, p. 764.

The Authors

PROF. RAMESH CHANDRA, M.S., M.S., F.R.C.S., *Professor & Head*, Postgraduate Department of Plastic Surgery, K.G.'s Medical College, Lucknow.

PROF. P. K. AGARWAL, M.S., Ph.D., *Professor of Ophthalmology*, K.G.'s Medical College, Lucknow.

PROF. (MRS.) PADAM K. AGARWAL, M.D., M.I.A.C., *Professor of Pathology*, K.G.'s Medical College, Lucknow.

Request for Reprints

DR. RAMESH CHANDRA, A-15, Nirala Nagar, Lucknow.