

## EXTENDED MEDIAL GASTROCNEMIUS MYOCUTANEOUS FLAP (A CASE REPORT)

ILA SAHA, P. SINHA AND A. K. BANERJEE

### SUMMARY

*The extended gastrocnemius myocutaneous flap is a good technique for reconstruction of skin and soft tissue loss of the lower third leg defects. We have obtained satisfactory result in our case by using this flap.*

The coverage of lower third leg defects remains a difficult problem. McCraw's (1977) classic Gastrocnemius musculocutaneous flap cannot cover the defects on the distal portion of the lower leg as it cannot reach distally beyond a point which is 5 cm above the medial malleolus and 7 cm above the lateral malleolus.

Many modifications have been done by different authors. These include, detachment of one muscle head from femoral origin to allow distal advancement of the unit by 4-5 cm (Dibbel & Edstrom (1980). Linton (1982) reconstructed large skin and Achilles tendon defect at the back of lower leg by detaching both the muscle origin of gastrocnemius from the femoral condylar region and advanced the whole muscle and skin unit to the site of the defect. Salibian & Menick (1982) obtained satisfactory result in treating skin and soft tissue defect at the lower third of the leg with bipedicle gastrocnemius musculocutaneous flap.

The modification presented by Cheng et al. (1984) of Beijing, China, is a true innovation to make the flap wider by 2 cm and longer by 3 cm. He has incorporated median sural artery with the flap which arises directly from the popliteal artery or from the sural artery or from one of its branches and courses with the sural nerve deep under the fascia of the gastrocnemius, in between the two heads of the muscle. It supplies a substantial por-

tion of the skin on the posterior surface. His idea is based on Manchots monograph (1989) who described the median sural artery as the most constant vessel.

We have obtained good result in an old case of compound fracture with non-union of both bones of the left leg with skin and soft tissue loss, using Cheng et al.'s modification.

### Case Report

A 22 year old man, was knocked down and run over by a minibus over the left lower leg on 6th March, 1985. He sustained a compound fracture of both bones of his left leg with full thickness skin and soft tissue loss over the antero-medial aspect at the junction of the middle and lower 3rd of the leg. Initial treatment was carried out at the department of Orthopaedic Surgery. Debridement of the wound, reduction of fractured fragments and external fixation by Steinman's pin and plaster casing was applied. Two weeks later it was noticed that the soft tissue over the fracture site had sloughed out (Fig. 1). Local dressings and systemic antibiotics were continued. X-ray on 29-5-1985 showed osteomyelitis with sequestrum formation and non-union at the fractured site (Fig. 2).

Three months after initial injury i.e., 14-6-1985, reconstructive surgery by vascularised myocutaneous flap was planned to provide good blood supply to the area, for control of infection and bony union. After reshaping

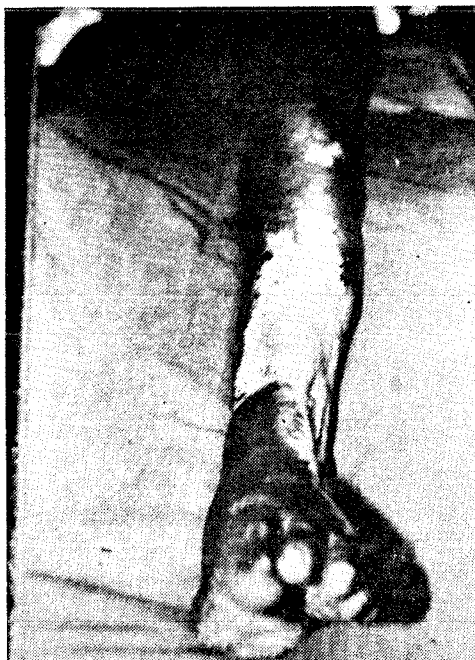

Fig. 1. Pre-operative appearance of soft tissue loss at the fracture site of lower third leg (Lt.).

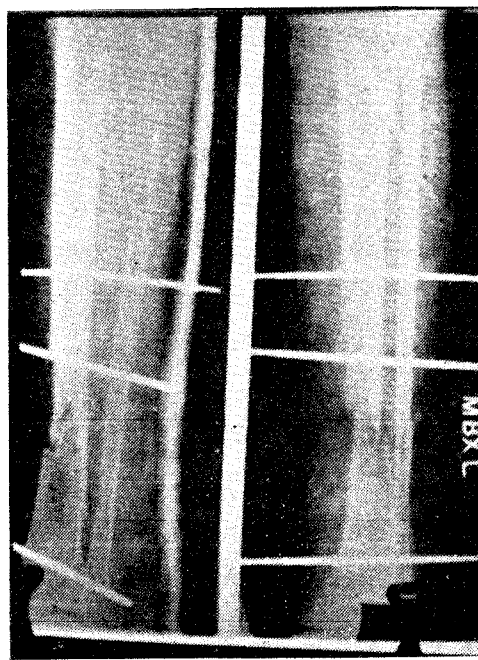


Fig. 2. Pre-operative radiograph showing non-union and osteomyelitis at the fracture site.

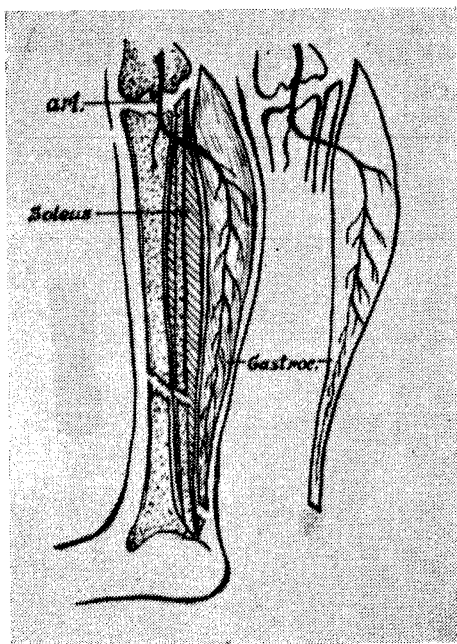


Fig. 3. Sketch of the island gastrocnemius myocutaneous flap based on neurovascular bundle.

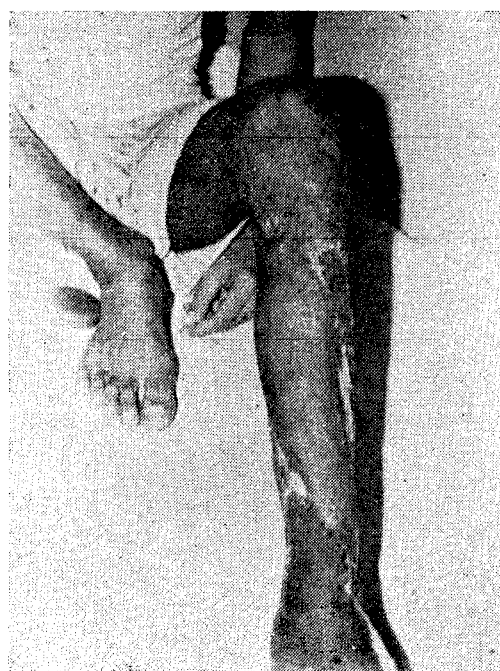

Fig. 4. Post-operative photograph—six weeks after surgery.

the wound on the anteromedial aspect of lower third leg, the skin and soft tissue defect measured  $11 \times 9$  cm. The sequestrum was removed, the osteomyelitic cavity was saucerized. The gastrocnemius myocutaneous flap was outlined at the back of the left leg. The widest part of the flap was 11 cm and its length was 23 cm. At the back of left leg, the incision was made 3 cm above the knee joint in the midline. It was brought down and curved  $2\frac{1}{2}$  cm lateral to the midline and was then extended distally to a point  $1\frac{1}{2}$  cm above the medial malleolus.

The anterior incision was made at the anterior margin of tibia. The actual dissection started at the medial border of tibia to separate the medial head of gastrocnemius muscle. The dissection was continued above upto the femoral condyle and below upto the Achilles tendon. In the posterior part of the leg, care was taken to save the median sural artery. The sural nerve and lesser saphenous vein lie in between the two heads of gastrocnemius. The medial head of the gastrocnemius muscle was separated from the femoral condyle taking care to save its blood supply. Then the dissection continued distally and the medial aspect of the Achilles tendon was divided and taken with the flap. Now the flap was an island flap based on neurovascular bundle only (Fig. 3). The knee was flexed. The island flap thus developed was advanced distally along its longitudinal axis and was transposed anteriorly and inferiorly for complete coverage of the wound making sure that there was no tension on the vascular pedicle. Then the knee was ex-

tended again gradually to see if there was any tension on the vascular pedicle and circulation to the skin was affected or not. The defect over the donor area was covered by free skin grafts and dressing applied. Then the knee was immobilised in  $30^\circ$  of flexion by a strong posterior plaster cast.

The external immobilisation was removed 3 weeks after the operation. The myocutaneous flap healed primarily, without any loss. Clinically the leg was found stable by 6 weeks (Fig. 4) and the x-ray after 10 weeks showed bony union. He was allowed weight bearing after 12 weeks. He has been followed up for more than a year and is now leading a normal life with adequate strength in his left leg.

### Discussion

Compound fractures of the lower third of leg pose a difficult problem as far as management is concerned because of poor circulation in the area. Extended gastrocnemius myocutaneous flap is an ideal choice for the purpose as it can provide wide coverage and good vascularity. Moreover the advantage of this method is that it can be widened both longitudinally and transversely and can be brought down to a lower level i.e. within 2 cm of the malleolus. By incorporating the median sural artery the viability of the widened flap is assured.

Cheng et al., (1984), reported partial flap necrosis at the margin in both their cases but there was no flap necrosis in our case. It is good, safe and easy method to tackle the age old problem of lower third leg defect.

### Acknowledgement

The authors thank The Director, I. P. G. M. E. & R., Calcutta for his kind permission to publish this case report and Dr. Sukumar Saha for his valuable advise in preparation of the manuscript.

### REFERENCES

1. CHENG, H. H., RONG, G. W., YIN, T. C., WANG, H. Y. AND JIAO, Y. C. : Coverage of wounds in distal lower leg by advancement of an enlarged medial gastrocnemius skin flap. *Plast. Reconstr. Surg.* 1984, 73: 4, 671-675.

2. DIBBELL, D. G. AND EDSTROM, L. E. : Gastrocnemius myocutaneous flap. Clin. Plastic Surgery, 1980; 7 : 45.
3. LINTON, P. G. : The combined medial & lateral gastrocnemius musculocutaneous V-Y island advancement flap. Plast. Reconstr. Surg., 1982; 70 : 4, 490-493.
4. McCRAW, J. B.; DIBBEL, D. G. AND CARRAWAY, J. H. : Clinical definition of independent myocutaneous vascular territories. Plast. Reconstr. Surg., 1977; 60 : 341.
5. SALBIAN, A. H. AND MENICK, F. J. : Bipedicle gastrocnemius musculocutaneous flap for defects of distal one-third of leg. Plast. Reconstr. Surg., 1982; 70 : 7.

#### **The Authors**

DR. ILA SAHA, M.S., M.Ch., *Reader*, Department of Plastic Surgery.

DR. P. SINHA, M.S., M.Ch., *R.M.O.*, Department of Plastic Surgery.

DR. A. K. BANERJEE, M.S., *Professor*, Department of Orthopaedic Surgery.

Institute of Postgraduate Medical Education & Research, Calcutta (India).

#### **Request for Reprints**

DR. ILA SAHA, M.S., M.Ch. 262, G.T. Road, P.O. Uttarpara, Dist. Hooghly 712 258, West Bengal (India).