



Pediatric Renovascular Hypertension: A Pediatric Interventional Radiologist's Perspective

Kanav Goyal¹ Taruna Yadav¹ Pawan Kumar Garg¹ Pushpinder Khara¹ Sarbesh Tiwari¹
Rengarajan Rajagopal¹

¹Department of Diagnostic and Interventional Radiology, All India Institute of Medical Sciences, Jodhpur, Rajasthan, India

Address for correspondence Rengarajan Rajagopal, MD, DM, Department of Diagnostic and Interventional Radiology, All India Institute of Medical Sciences, Jodhpur 342005, Rajasthan, India (e-mail: heraghava@gmail.com).

Indian J Radiol Imaging 2023;33:508–513.

Abstract

Renovascular hypertension (RVH) contributes close to one-fourth of the secondary etiologies of hypertension in children and a delay in diagnosis can result in adverse clinical outcomes. RVH in children is clinically silent with elevations in blood pressure measurements sometimes as its sole manifestation. Only a high index of suspicion by the clinician can prompt its detection. Despite the availability of other imaging modalities like ultrasound, computed tomography, and magnetic resonance imaging, digital subtraction angiography is still considered the gold standard to make a diagnosis of RVH. Angioplasty is considered the treatment of choice in appropriately selected patients. In this article, we shall focus on the various imaging findings, and management of RVH in children, which requires a multidisciplinary approach with a special focus on the role of interventional radiology.

Keywords

- ▶ renovascular hypertension
- ▶ renal artery stenosis
- ▶ digital subtraction angiography
- ▶ balloon angioplasty

Introduction

Pediatric hypertension is considered a strong predictor for the development of hypertension in adults and if left untreated can predispose to various cardiovascular complications.¹ Despite guidelines from various societies, there is inconsistent effort to regularly measure blood pressures (BP) in children and most cases of pediatric hypertension are diagnosed incidentally.² By definition, the presence of systolic BP more than 95th percentile for that age, sex, and height is considered as pediatric hypertension.³ Up to 10% of these cases are attributed to renovascular hypertension (RVH) that is due to any lesion reducing blood flow to part or one or both kidneys, with resulting alterations in the renin-angiotensin system.⁴ It is important to identify children with RVH, as many diseases causing RVH can be treated by endovascular, or surgical interventions, in addition to optimal medical management. Early identification and proper management can significantly improve the child's long-term outcome.³

Etiology

The most common etiology of RVH in developed countries is fibromuscular dysplasia (FMD) (▶ **Figs. 1A–B** and **2**), while in Asian and African countries, Takayasu arteritis (TA) (▶ **Fig. 3**) is more common.⁵ Other uncommon causes of renal artery stenosis (RAS) in children can be either syndromic (neurofibromatosis-1 [NF-1], tuberous sclerosis, William's syndrome, Marfan's syndrome) or nonsyndromic (hypercoagulable states) (▶ **Fig. 4A** and **B**) (▶ **Table 1**). Most of the syndromic causes of RVH have bilateral RAS with concomitant involvement of other visceral arteries. Previous studies have shown that 24 to 78% of patients with RVH may have bilateral RAS.^{5,6} Focal stenosis of renal arteries was seen more commonly than diffuse or multifocal involvement. Stenotic lesions have been reported throughout the renovascular tree in the main renal arteries in 25% of patients, in second-order branches in 50% of patients, in 12.5% of patients in more distal "parenchymal"

article published online
August 21, 2023

DOI <https://doi.org/10.1055/s-0043-1772496>.
ISSN 0971-3026.

© 2023. Indian Radiological Association. All rights reserved.

This is an open access article published by Thieme under the terms of the Creative Commons Attribution-NonDerivative-NonCommercial-License, permitting copying and reproduction so long as the original work is given appropriate credit. Contents may not be used for commercial purposes, or adapted, remixed, transformed or built upon. (<https://creativecommons.org/licenses/by-nc-nd/4.0/>)

Thieme Medical and Scientific Publishers Pvt. Ltd., A-12, 2nd Floor, Sector 2, Noida-201301 UP, India

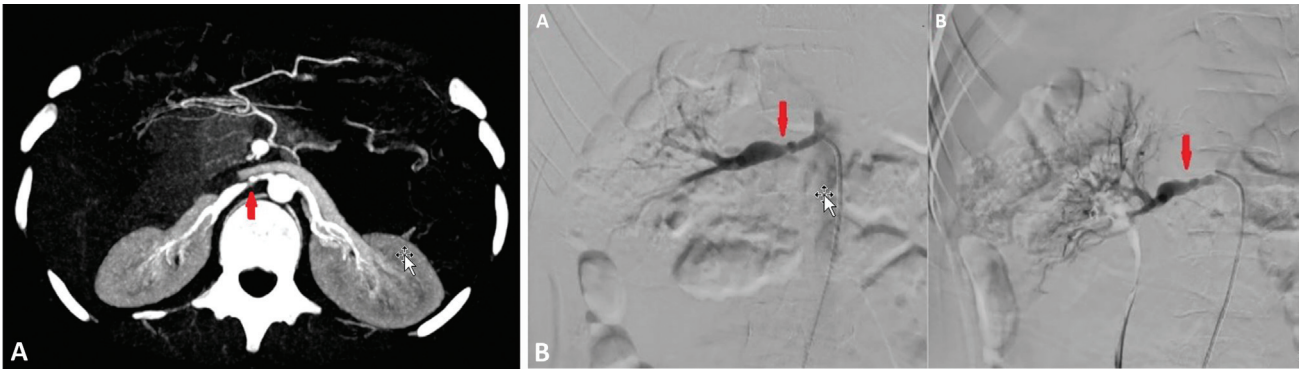


Fig. 1 (A) Maximum intensity projection image of computed tomography angiography in an adolescent boy presenting with hypertension, demonstrating stenosis of proximal segment of right renal artery (red arrow) with poststenotic dilatation due to fibromuscular dysplasia. (B) Fibromuscular dysplasia: a. Renal angiogram showing beaded appearance of proximal right renal artery (red arrow in a). b. Postpercutaneous angioplasty image showing reduction in stenosis (red arrow in b).

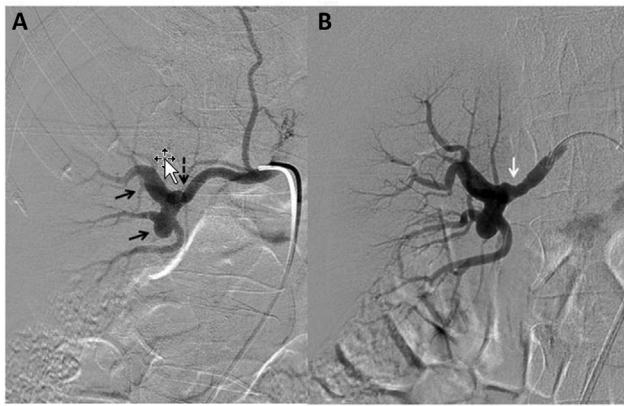


Fig. 2 Right renal angiograms in an adolescent female with hypertension demonstrating aneurysmal dilatation of the hilum of right renal artery also involving the hilar branches (black arrows). (A) A discrete concentric lesion is seen causing significant stenosis; pressure gradient proximal and distal to the stenosis was 60 mm Hg (black dashed arrow). (B) Postangioplasty reduction in stenosis (due to the discrete lesion—white arrow).

branches, and in accessory renal arteries, respectively (► Fig. 5).^{6,7} In middle aortic syndrome (MAS), a syndromic cause of RVH, segmental narrowing of the abdominal, or distal descending thoracic aorta is seen, which usually involves the renal arteries in 60% of patients and other visceral branches, like intestinal, iliac, carotid, cerebral, and brachial arteries.^{3,5,6,8,9} MAS can be either congenital or acquired. In the congenital form, there is faulty development of the abdominal aorta around day 25, due to improper fusion of the two embryonic dorsal aortas to form a single vessel.³ The acquired forms of MAS are associated with inflammatory conditions of the aorta such as TA and NF-1.^{6,7}

Imaging in Pediatric Renovascular Hypertension

No single screening imaging modality can accurately diagnose all children with RAS. All noninvasive imaging modalities have been used for diagnosing RAS in children, with digital subtraction angiography being considered the gold standard for diagnosis. ► Table 2 provides a summary of all the imaging modalities available for the evaluation of RVH.^{10–14}

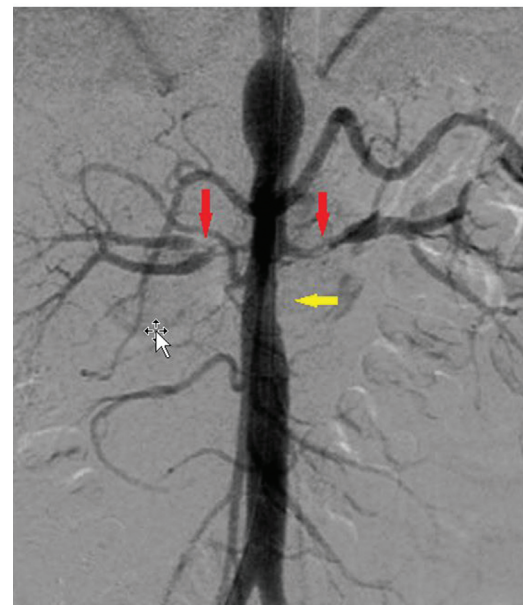


Fig. 3 Abdominal aortic angiogram in an adolescent girl who presented with neck pain and unequal upper limb pulses, showing significant bilateral renal artery stenosis (red arrows) and coexistent aortic stenosis (yellow arrow) due to Takayasu arteritis.

Management

Various treatment options for RVH include medical management, endovascular management, and surgery. The primary goal of all treatment modalities is to control hypertension, preserve renal function, and restore renal perfusion.¹⁵ The primary treatment modality is decided by a multidisciplinary approach including pediatric nephrologists, pediatric radiologists and interventional radiologists, and pediatric surgeons.

Medical Management

Initial management of children with raised BP is done with antihypertensives. The choice of the antihypertensives is based on the etiology. Angiotensin-converting enzyme inhibitors or angiotensin receptor blockers are preferably avoided in children with bilateral RAS.¹⁶ In addition, 24-hour

Table 1 Causes of renovascular hypertension in children

Causes of renovascular hypertension in children (Involvement of main renal arteries or segmental renal arteries or concurrent abdominal aortic involvement in the form of middle aortic syndrome)
<ul style="list-style-type: none"> • Vasculitis—Takayasu arteritis, polyarteritis nodosa, Kawasaki disease • Fibromuscular dysplasia • Neurofibromatosis • William syndrome • Congenital webs (►Fig. 6) • Transplant renal artery stenosis (►Fig. 7)

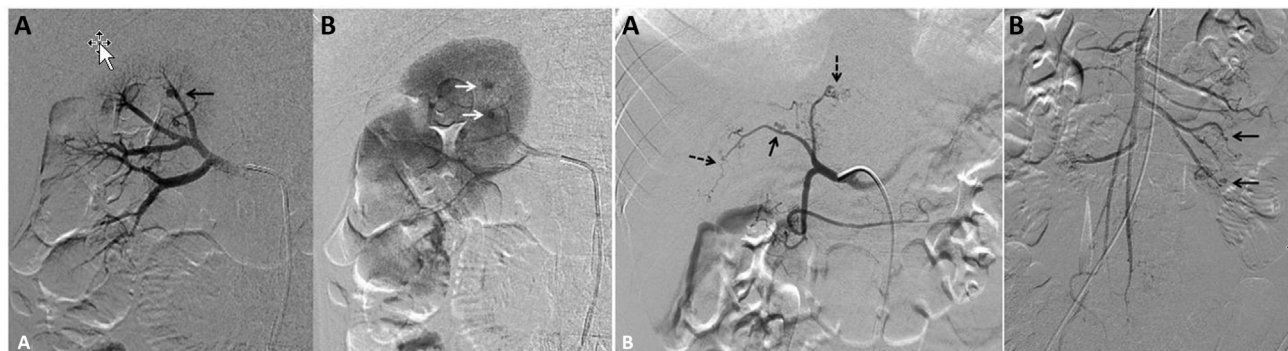


Fig. 4 (A) Right renal angiograms (a—early arterial and b—parenchymal phase) in a 10-year-old boy who presented with hypertension and hematuria, showing multiple microaneurysms (black arrow) within segmental and subsegmental renal artery branches suggestive of Polyarteritis Nodosa. Persistent contrast pooling in the microaneurysms in the parenchymal phase (white arrows in b), helping to differentiate from end-on vessels. (B) Angiogram of the common hepatic artery in the child as in (a) demonstrating segments of beading and stenosis in right, left hepatic arteries, and segments of beading and stenosis (black arrows). b. Superior mesenteric artery angiogram demonstrating multiple microaneurysms in distal branches (black arrows).

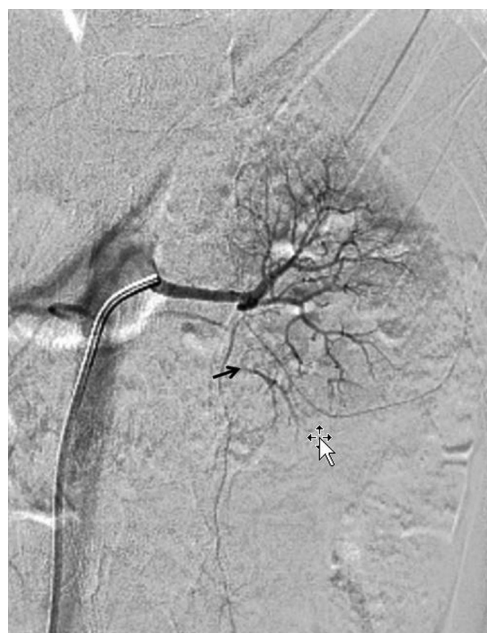

Fig. 5 Accessory renal artery occlusion in a 15-year-old girl with elevated blood pressures above 95th centile: Angiogram showing occlusion of proximal and mid segments of the accessory renal artery to left lower pole with distal filling through collaterals (black arrow).

ambulatory BP monitoring is helpful to provide information about BP control.

Continuation of medical therapy is done in children, who are still being evaluated for RAS or those unfit to undergo procedures like angioplasty or surgical intervention; however, these children often require multiple antihypertensives of different classes for optimal BP control.^{5,6} Almost one in every two children who undergoes an interventional or surgical procedure requires medical treatment in the post-operative period.¹⁷ Careful monitoring of the child's adherence and evaluation for side effects of drugs is also essential. In children with MAS and RAS, previous studies have shown that delay in intervention till puberty has a better outcome.¹⁸

Angioplasty

Arterial stenosis in children with RVH is due to local intimal hyperplasia. Percutaneous balloon angioplasty is the most used technique for RAS in children, especially in children with lesions involving smaller lengths of renal arteries (►Figs. 6 and 7). It is usually performed under general anesthesia using femoral or brachial artery access.¹¹ The balloon diameter used for angioplasty varies with age and vessel size. Renal artery diameter, proximal to the stenosed segment, is used to guide the sizing of the angioplasty

Table 2 Imaging features in renovascular hypertension in children²⁸

Modality	Diagnostic findings	Sensitivity and specificity (values mostly from adult studies)
Ultrasound	Parvus-et-tardus waveform PSV > 180 or 200 cm/s AT > 80 milliseconds Renal artery aorta ratio > 3 Difference in RI > 0.05 Difference in kidney length \geq 1 cm	73–85% and 71–92%
CEUS	Identification of perfusion defects useful for documenting postangioplasty increased perfusion	Not routinely used for diagnosis
MRA	Narrowing in main or the accessory renal artery Presence of collateral vessels For evaluation of aorta and other nonvascular causes of hypertension	64–93% and 72–97% in various studies
CTA	Similar to MRA	64–94% and 62–97%
Renal scintigraphy (^{99m} Tc-DMSA or ^{99m} Tc-MAG3)	Increase in time to peak activity in renogram curve Delayed washout	52–93% and 63–92%
Renal vein renin sampling	Renin ratio of > 1.5 between main renal veins Ratio of < 1.3 between the contralateral renal vein and IVC	56 and 94% (usually performed in bilateral cases)
Angiography	Direct visualization of a stenosed segment of the renal artery and its branches	Considered as gold standard for diagnosis of RAS

Abbreviations: ^{99m}Tc-DMSA, ^{99m} technetium-dimercaptosuccinic acid; ^{99m}Tc-MAG3, ^{99m}Tc-mercaptoacetyl triglycine; AT, acceleration time; CEUS, contrast-enhanced ultrasound; CTA, computed tomography angiography; IVC, inferior vena cava; PSV, peak systemic velocity; MRA, magnetic resonance angiography; RAAS, renin angiotensin-aldosterone system; RAR, renal artery to aortic flow velocity ratio; RI, resistive index.

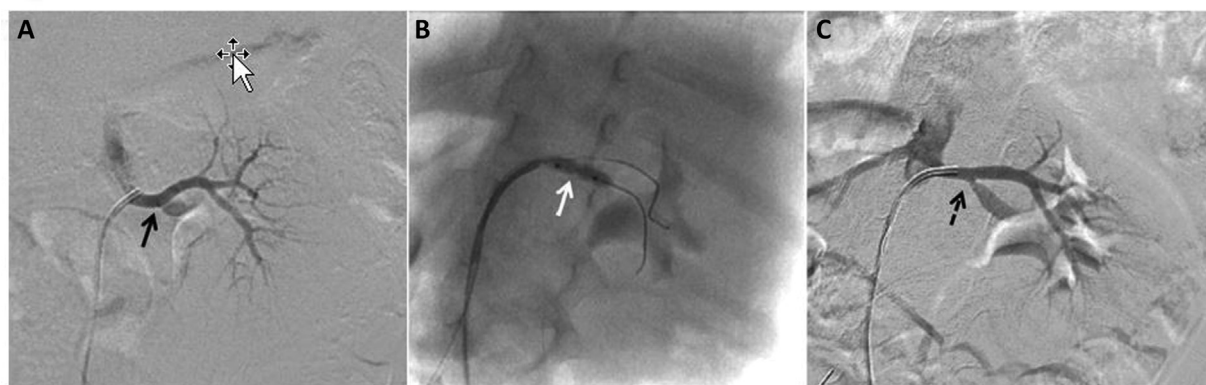


Fig. 6 Left renal angiograms in an 8-month-old female infant presenting with heavy breathing and blood pressure over 95th centile for age. (A) Significant discrete stenosis of left lower polar artery due to congenital fibrous band with the slow differential antegrade flow. (B) Balloon angioplasty of the stenotic segment. (C) Postangioplasty angiogram showing reduction in stenosis and good antegrade flow.

balloon, as poststenotic segment is often dilated. In unilateral disease, however, the normal contralateral artery diameter can also be used to guide the balloon size.¹⁶ The use of high-pressure balloons and drug-eluting balloons to supplement conventional angioplasty is uncommon in children.¹⁹ Children, who have an inadequate response to angioplasty, are more prone to develop worsening hypertension within a few months of the procedure.¹⁶ These children might require secondary procedures for control of their BP. Children may also show delayed clinical response after angioplasty. This is thought to be related to spasm resulting in a false impression of residual stenosis on postplasty angio-

grams or due to an increase in luminal diameter over time during healing by retraction of fibrous bands.^{20,21} Restenosis following angioplasty is seen in as high as 41% of cases and requires repeat angioplasty.^{6,20} Time to restenosis has been shown in different studies to range from as low as 2 weeks to 60 months.²² In the long term, the success for angioplasty for FMD in children is less than that reported for adults, while the ostial stenosis secondary to NF-1 has better treatment outcomes.^{11,23} Other reasons for a lower response in children may be higher rates of multiple stenoses, especially those with MAS who present with widespread disease, including bilateral RAS and intrarenal involvement. In such cases, in

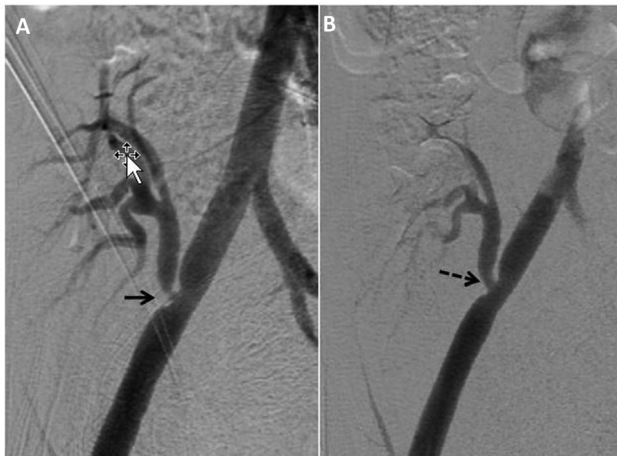


Fig. 7 A 10-year-old male child patient postrenal transplantation presenting with hypertension and altered renal function test. (A) Abdominal aortic angiogram showing the transplant renal artery (end to side anastomosis with right external iliac artery) with significant anastomotic site stenosis (black arrow). (B) Postangioplasty reduction in stenosis (black dashed arrow).

the presence of significant intrarenal disease, successful treatment of main artery stenoses might still fail to improve the BP.³

Cutting balloon angioplasty is used for high-grade lesions and lesions resistant to treatment with conventional and high-pressure angioplasty.^{3,23,24} It is now recommended to limit the use of cutting balloons, only for the incisional phase with balloon diameter limited to no more than normal vessel diameter after which further dilatation should be done with a conventional balloon.²⁴ This recommendation was made, as many studies showed complications like dissections and aneurysms developing after the use of cutting balloons in children. Additionally, imaging modalities like intravascular ultrasound can be used that can guide the safe placement of the balloon at the desired location.²⁴

Stenting

The use of stents is generally not preferred in children, as they can act as sites of stenosis when the child grows. Even in cases refractory to conventional balloon angioplasty, repeat angioplasty is more suitable as compared with stenting. Various published studies have shown that the rate of restenosis after stenting is significantly higher (close to 35%) as compared with only angioplasty which has a restenosis rate of approximately 17%.^{22,25} Currently, there are only a few indications for stenting in children, which include very severe or recurrent lesions, and managing iatrogenic dissections, which show significant elastic recoil or restenosis after angioplasty.^{13,23,25}

Ethanol Embolization

Ethanol embolization can be used when segmental arterial stenosis is detected as the cause of RVH (lesions that are not amenable to angioplasty or open surgery).³ Super selective embolization of segmental artery is done with ethanol

causing coagulative necrosis and subtended parenchymal infarction.¹¹

Aortic Interventions

Aortic angioplasty with or without stenting is required in patients with combined MAS with associated RAS. These patients often have hypertension that is refractory to medical management, despite multiple classes of antihypertensives being used.³ Various studies have shown that there is a significant drop in systolic BP in these patients, when compared with patients with isolated RAS with angioplasty; however, long-term outcomes are variable.^{8,26}

Complications of Endovascular Management

Various studies have reported complications ranging between 0 and 43%, following endovascular procedures for RVH in children.^{6,23} Procedural complications include arterial spasm, dissection or aneurysm formation, delayed pseudoaneurysm formation, and iatrogenic perforation. Focal renal ischemia or infarction can develop secondary to embolic phenomenon distal to angioplasty site or due to thrombosis of segmental vessels, after prolonged guidewire placement. Local site dissection can be expected at the site of balloon dilatation due to vascular remodeling. Such dissections are seen more frequently with cutting balloon angioplasty than conventional angioplasty, and may not be hemodynamically significant.⁵ Procedure-related mortality has previously been rarely reported. If an inadvertent arterial rupture occurs, balloon reinflation or covered stent placement may be attempted, failing which urgent surgical consultation should be obtained.^{13,23} Postprocedural complications include accelerated or worsening hypertension that increase the risk of stroke in children⁵ therefore, preprocedural assessment of head and neck vessels should always be performed.²³

Surgery

Surgery is usually reserved for children with complicated RAS (i.e., long stenotic lesions [>10 mm], multiple segment stenosis of large vessels, or bilateral RAS), due to technical challenges in small children.^{17,23,24} There is a paucity of surgical data in the pediatric population. Most of the surgeries are performed, when children attain adult-sized vasculature. Bridging this gap with endovascular treatment can lead to secondary fibrotic changes, necessitating alterations in the typical surgical approach from primary renal arterial reimplantation to aortorenal bypass.²⁷ Due to the established safety and success of endovascular interventions, most institutions prefer endovascular treatment for RAS.

Conclusion

RVH is an important cause of secondary hypertension in children. Lack of prospective studies due to the heterogeneity of the population being affected is an important challenge in formulation of uniform guidelines for management. A multidisciplinary approach including pediatric radiologists and interventional radiologists, pediatric nephrologists, and

pediatric surgeons is vital for optimal clinical outcome. Endovascular therapy with angioplasty is generally preferred in appropriately selected children with good clinical outcomes.

Funding
None.

Conflict of Interest
None declared.

References

- Bao W, Threefoot SA, Srinivasan SR, Berenson GS. Essential hypertension predicted by tracking of elevated blood pressure from childhood to adulthood: the Bogalusa Heart Study. *Am J Hypertens* 1995;8(07):657–665
- Tullus K. To screen or not to screen: for high blood pressure. *Pediatr Nephrol* 2018;33(01):81–82
- Patel PA, Cahill AM. Renovascular hypertension in children. *CVIR Endovasc* 2021;4(01):10
- Falkner B, Daniels SR. Summary of the fourth report on the diagnosis, evaluation, and treatment of high blood pressure in children and adolescents. *Hypertension* 2004;44(04):387–388
- Tullus K, Brennan E, Hamilton G, et al. Renovascular hypertension in children. *Lancet* 2008;371(9622):1453–1463
- Lobeck IN, Alhajjat AM, Dupree P, et al. The management of pediatric renovascular hypertension: a single center experience and review of the literature. *J Pediatr Surg* 2018;53(09):1825–1831
- Srinivasan A, Krishnamurthy G, Fontalvo-Herazo L, et al. Spectrum of renal findings in pediatric fibromuscular dysplasia and neurofibromatosis type 1. *Pediatr Radiol* 2011;41(03):308–316
- Rumman RK, Nickel C, Matsuda-Abedini M, et al. Disease beyond the arch: a systematic review of middle aortic syndrome in childhood. *Am J Hypertens* 2015;28(07):833–846
- Trautmann A, Roebuck DJ, McLaren CA, Brennan E, Marks SD, Tullus K. Non-invasive imaging cannot replace formal angiography in the diagnosis of renovascular hypertension. *Pediatr Nephrol* 2017;32(03):495–502
- Dillman JR, Smith EA, Coley BD. Ultrasound imaging of renin-mediated hypertension. *Pediatr Radiol* 2017;47(09):1116–1124
- Villegas L, Cahill AM, Meyers K. Pediatric renovascular hypertension: manifestations and management. *Indian Pediatr* 2020;57(05):443–451
- Krishna A, Kumar O, Singh MK. Renovascular hypertension: a review article. *Clin Queries Nephrol* 2013;2:38–43
- McLaren CA, Roebuck DJ. Interventional radiology for renovascular hypertension in children. *Tech Vasc Interv Radiol* 2003;6(04):150–157
- Goonasekera CD, Shah V, Wade AM, Dillon MJ. The usefulness of renal vein renin studies in hypertensive children: a 25-year experience. *Pediatr Nephrol* 2002;17(11):943–949
- Piercy KT, Hundley JC, Stafford JM, et al. Renovascular disease in children and adolescents. *J Vasc Surg* 2005;41(06):973–982
- Meyers KE, Cahill AM, Sethna C. Interventions for pediatric renovascular hypertension. *Curr Hypertens Rep* 2014;16(04):422
- Louis R, Levy-Erez D, Cahill AM, Meyers KE. Imaging studies in pediatric fibromuscular dysplasia (FMD): a single-center experience. *Pediatr Nephrol* 2018;33(09):1593–1599
- Lacombe M. Surgical treatment of renovascular hypertension in children. *Eur J Vasc Endovasc Surg* 2011;41(06):770–777
- Agrawal H, Moodie D, Qureshi AM, et al. Interventions in children with renovascular hypertension: a 27-year retrospective single-center experience. *Congenit Heart Dis* 2018;13(03):349–356
- Bayrak AH, Numan F, Cantaşdemir M, Baş A. Percutaneous balloon angioplasty of renovascular hypertension in pediatric cases. *Acta Chir Belg* 2008;108(06):708–714
- Gardiner GA Jr, Freedman AM, Shlansky-Goldberg R. Percutaneous transluminal angioplasty: delayed response in neurofibromatosis. *Radiology* 1988;169(01):79–80
- Kari JA, Roebuck DJ, McLaren CA, et al. Angioplasty for renovascular hypertension in 78 children. *Arch Dis Child* 2015;100(05):474–478
- Srinivasan A, Krishnamurthy G, Fontalvo-Herazo L, et al. Angioplasty for renal artery stenosis in pediatric patients: an 11-year retrospective experience. *J Vasc Interv Radiol* 2010;21(11):1672–1680
- Towbin RB, Pelchovitz DJ, Cahill AM, et al. Cutting balloon angioplasty in children with resistant renal artery stenosis. *J Vasc Interv Radiol* 2007;18(05):663–669
- Shroff R, Roebuck DJ, Gordon I, et al. Angioplasty for renovascular hypertension in children: 20-year experience. *Pediatrics* 2006;118(01):268–275
- König K, Gellermann J, Querfeld U, Schneider MB. Treatment of severe renal artery stenosis by percutaneous transluminal renal angioplasty and stent implantation: review of the pediatric experience: apropos of two cases. *Pediatr Nephrol* 2006;21(05):663–671
- Eliason JL, Coleman DM, Criado E, et al. Remedial operations for failed endovascular therapy of 32 renal artery stenoses in 24 children. *Pediatr Nephrol* 2016;31(05):809–817
- Tullus K, Roebuck DJ, McLaren CA, Marks SD. Imaging in the evaluation of renovascular disease. *Pediatr Nephrol* 2010;25(06):1049–1056