



Tooth as a Bone Graft Material: A Narrative Review

Vishnu Teja Obulareddy¹ Amit Porwal^{2,3} Toufiq Noor⁴ Francesco Catalano⁵ Giuseppe Minervini⁶
Cesare D'Amico⁵ Maura Mancini⁵ Francesca Gorassini^{5,6} Luca Fiorillo^{3,5,6} Gabriele Cervino⁵

¹S.V. Dental Clinic and Implant Centre, Hyderabad, Telangana, India

²Department of Prosthetic Dental Science, College of Dentistry, Jazan University, Jazan, Saudi Arabia

³Department of Prosthodontics, Dr. D.Y. Patil Dental College and Hospital, Dr. D.Y. Patil Vidyapeeth, Pune, Maharashtra, India

⁴Aswein Institute of Health and Management Studies, Kolkata, West Bengal, India

Address for correspondence Luca Fiorillo, DDS, MSc, PhD, Department of Biomedical Sciences, Dentistry and Morphological and Functional Imaging, University of Messina, Via Consolare Valeria, 1 98100, Messina, Italy (e-mail: lfiorillo@unime.it).

⁵Department of Biomedical Sciences, Dentistry and Morphological and Functional Imaging, University of Messina, Messina, Italy

⁶Multidisciplinary Department of Medical-Surgical and Dental Specialties, University of Campania "Luigi Vanvitelli," Napoli, Italy

Eur J Gen Dent 2023;12:72–81.

Abstract

To treat osseous defects, a range of bone grafts and their replacements have been accessible, but appropriate reconstruction by any bony defect persists as a therapeutic hurdle. Based on peer-reviewed literature, the current narrative review analyzes significant outcomes in patients treated with bone grafts and bone graft substitutes for surgical therapy of osseous defects. Despite autograft, xenograft, and alloplastic bone graft substitutes being employed in several periodontic procedures, they all have their restrictions. Autogenous tooth bone graft is functional in clinics due to different available forms, which can be availed for other clinical challenges. Moreover, genetic uniformity fosters efficient bone regeneration by allowing osteoinduction and osteoconduction and reducing foreign body reactions.

Keywords

- ▶ alloplastic
- ▶ bone graft
- ▶ oral surgery
- ▶ regenerative surgery
- ▶ tooth

Introduction

In dentistry, bone graft materials are commonly utilized to promote bone development. Among various such materials, an autologous bone graft, or autograft, which involves the transport of bone from a donor site to another location in the same patient, is accepted globally for its osteoregenerative properties. However, autogenous bone grafts have significant disadvantages, including limited availability, donor site morbidity, and a high resorption rate. Alternative grafts like allograft, xenograft, and alloplastic bone grafts are introduced to overcome these limitations. Despite recent progress, some limitations have been reported, such as pathogen transmission and rejection by the recipient's body in the case of allografts and xenografts use and the

absence of osteoinductive properties and poor mechanical features of alloplastic bone grafts.¹ Whether autograft, xenograft, or alloplastic is used to fill bone deformities. Each has its own set of drawbacks. Additional procedures were required, as well as functional and esthetic issues at the donor site, different degrees of graft resorption, and the small amount of graft recovered, necessitating the search for an alternative. Numerous substitutes are being tried to address the relevant flaws. These substitutes should have properties of an ideal bone graft, including stabilization of the blood clot, provision of a biomechanical scaffold for cell migration, proliferation, and differentiation, containing functional proteins and peptides, having appropriate resorption, and remodeling while new bone is formed. Dentin is one such material that may be attempted as a bone graft material.

DOI <https://doi.org/10.1055/s-0043-1771533>.
ISSN 2320-4753.

© 2023. The Author(s).

This is an open access article published by Thieme under the terms of the Creative Commons Attribution License, permitting unrestricted use, distribution, and reproduction so long as the original work is properly cited. (<https://creativecommons.org/licenses/by/4.0/>)
Thieme Medical and Scientific Publishers Pvt. Ltd., A-12, 2nd Floor, Sector 2, Noida-201301 UP, India

Other than the fact that dentin and bone have similar biochemical properties (80% hydroxyapatite crystals and 20% type I collagen), it also contains growth factors found in bone, such as insulin-like growth factor II (IGF-II), transforming growth factor (TGF- β), and bone morphogenic protein (BMP).²

As dentin includes several proteins found in bone, such as osteopontin, bone sialoproteins, dentin sialoproteins, osteonin, and osteocalcin, it has been used as a bone graft. Autogenous and allogeneous demineralised dentin matrix (DDM) are the two main kinds of DDM.³ Extracted adult human third molars were crushed in liquid nitrogen, washed in sodium chloride, 1M (NaCl), demineralised in an acidic solution such as acetic acid or hydrochloric acid (pH=2), rinsed in cold distilled water, and lyophilized to make the graft suitable to use.⁴ Dentin has osteoinductive properties, similar to bone, so multiple investigations have shown that dentin-derived bone substitution stimulates osteoinduction. Yeomans and Urist initially demonstrated the regenerative feature of autogenous DDM. BMP, which is found in DDM and bone, is a crucial stimulant with osteoinductive effects, according to Urist.⁵

There are two types of autogenous dental bone transplant materials: block and powder. The block type of graft material possesses osteoinduction potential due to blood wettability and osteoconduction potential due to space maintenance and creeping substitution. Osteoinduction, the process by which osteogenesis is induced, and osteoconduction, which is the ability of bone-forming cells in the grafting area to move across a scaffold and slowly replace it with new bone over time, are observed along with different particle sizes, porosity, blood wettability, and creeping substitution abilities to determine the powder type. Both types can be employed for extraction socket preservation, cosmetic alveolar bone replacement, perforated sinus membrane restoration, and early implant stabilization augmentation. Thus, autogenous tooth bone graft is functional in clinics due to the different available forms for clinical situations. Furthermore, it promotes excellent bone regeneration by allowing for osteoinduction and osteoconduction, reducing foreign body reactions owing to genetic homogeneity.⁶

Autogenous tooth bone graft material finds a lot of clinical applications. Because it is autogenous, the possibility of an immunological reaction is eliminated. It may be employed for guided tissue regeneration, tooth socket preservation, ridge augmentation, sinus bone graft and grafts in tumor resections, cyst enucleation, etc.⁶ After tooth extraction, Kim et al placed autogenous tooth bone powder and a block in the socket. After 3.5 months, they determined that the socket had healed well and was suitable for implant insertion.⁷

Objectives

This review aimed to describe the application of tooth as a bone grafting material based on the most recent literature, lightening its clinical evaluation and the process of manufacturing tooth graft material.

Search Strategy

Electronic research using several databases found articles on the tooth as a bone grafting material. All articles with data on autogenous grafts published in English were included in the review process. Only research published in the last 7 years was evaluated for this study to provide an updated overview of this area. The following keywords, combined with the Boolean term “AND,” were used: “Autogenous Teeth Graft,” “Bone Graft,” “Tooth osteoplatation,” and “Autogenous fresh demineralised tooth.”

Study Selection and Data Collection Process

Two masked independent reviewers assessed eligibility; one of the review's authors gathered data from the included studies, while another confirmed it. Discussions between the two authors handled disagreements between reviewers, and if no agreement could be achieved, a third author made the final judgment. The author's name and year of publication, the form used, and the type of surgery were tabulated for all studies (►Table 1). The flowchart used for this study is depicted in ►Fig. 1.

Methodological Quality Appraisal

No formal assessment of the methodological quality of all included studies was undertaken following review guidelines.

Teeth Structure and Composition versus Alveolar Bone

Alveolar bone and tooth share the exact origin derived from neural crest cells. Despite that, they are dramatically different in their morphologies and physical functions. The crown, which is covered in enamel and ordinarily visible in the mouth, and the root, which is buried in the jaw and supports the tooth in its bone socket, are the two anatomical elements of the tooth. The root makes up approximately two-thirds of the tooth. The tooth has three hard tissue components: the enamel, the dentin, and the cementum. Dental enamel, the human body's hardest tissue, comprises 96% of high crystalline apatite with a complex crystalline lattice organization, 3% water, and less than 1% of the organic matrix in weight volume. The underlying layer enamel, called dentin, contains microscopic tubules that traverse its entire thickness with nanocrystalline reinforced composite, 70% of low crystalline carbonated apatite, and approximately 20% of organic contents—Dentin's variable water content changes by around 20-fold from superficial to deep dentin. Cementum, a layer of connective tissue that binds the roots firmly to the jawbone, has approximately 45% low crystalline carbonated apatite ratio and approximately 50% organic content.^{20,21} The comparable chemical composition of bone and teeth inspired the notion of using the autogenous tooth as a bone substitute in bone grafting procedures. The biological entity (i.e., cells), regardless, alveolar bone comprises 65% low crystalline carbonated apatite and 25% organic component. Fibrillar type I collagen (COL-I), with dozens of other noncollagenous macromolecules, the primary organic part of teeth, accounts for over 90% of its total organic content (i.e., phosphophoryn, dentine sialoprotein, osteonectin, osteopontin, osteocalcin,

Table 1 Characteristics of included studies

Author	Form used	Type of surgery
Kim 2015 ⁸	Powder	An autogenous fresh demineralized tooth graft was prepared at the chairside for alveolar bone grafting during dental implant surgery
Joshi et al, 2016 ⁹	Powder	Autogenous tooth grafts and β -tricalcium phosphate (β -TCP) alloplast were utilized for alveolar ridge preservation
Kim et al, 2016 ¹⁰	Block	For maxillary sinus augmentation with simultaneous implant placement, an autogenous fresh demineralized tooth block (auto-FDT block) containing platelet-rich plasma was used
Pang et al, 2017 ¹¹	Powder	In post-extraction alveolar bone augmentation, autogenous tooth graft material was compared with organic bovine bone (Bio-Oss)
Pohl et al, 2017 ¹²	Powder	Chemically unaltered tooth material is used in lateral alveolar ridge augmentation or for the filling of jaw deformities
Lip et al, 2018 ¹³	Powder	In guided bone regeneration (GBR) for rapid implantation in periodontal postextraction sites, autogenous demineralized dentin matrix against Bio-Oss granules was compared
Parvini et al, 2018 ¹⁴	Block	For lateral alveolar ridge augmentation, autogenous tooth roots were compared with autogenous bone blocks
Schwarz et al, 2018 ¹⁵	Block	Compare the efficacy and safety of autogenous tooth roots and autogenous bone blocks for lateral alveolar ridge augmentation and two-stage implant insertion
Del Canto-Diaz et al, 2019 ¹⁶	Powder	Socket preservation with autologous dental material
Wu et al, 2019 ¹⁷	Powder	The effectiveness of autogenous tooth bone grafts against xenogenic bone grafts in immediate implant placement with a bone deficiency was compared
Shejali et al, 2020 ¹⁸	Block	Autogenous tooth roots were used as a block bone transplant to restore the vertical and horizontal dimensions at periodontally hopeless extraction sites
Kuperschlag et al, 2020 ¹⁹	Powder	Following extraction of impacted third molars, an autogenous dentin graft is used to correct osseous defects distal to the mandibular 2nd molars

and dentin matrix protein-1) that account for the remaining 10%. These macromolecules act as linkages between collagen fibrils, securing the collagenous network.

Furthermore, a small amount of type III collagen, abundantly described in connective tissues, is localized in the intertubular dentin dentinal tubule matrix. From the structural point of view, dentin's density, roughness, porosity, and homogeneity are similar to human mandibular cortical bone.²² Dentinal tubules have numerous branches and ramifications, providing a dense canalicular anastomosing system near the osteocyte lacuna in bone.²⁰ This network of channels spreads radially from the pulp outward to the dentin enamel junction and cementum. The density and diameter of tubules are lowest near the dentin enamel junction and rise as they get closer to the pulp. Dentin is a strong and elastic mineralized tissue constituting tooth mass and supports the enamel, compensating for its brittleness from a mechanical standpoint. Dentin has an elastic modulus of 18 GPa close to the cortical bone (14 GPa) but higher to the trabecular bone (1.3 GPa).²³ The dental pulp is a soft tissue that runs from the central chamber to the root apex of the tooth. The pulp is a connective tissue comprising pulp cells, collagen fibers, nerves, and blood vessels from a structural standpoint. Among pulp cells, dental pulp stem cells (DSPCs) share the same phenotype as bone marrow-derived mesenchymal stem cells and are responsible for tissue repair and self-renewal along with the prepositioned inflammatory process.²⁴

Teeth Procurement

Bone graft material from autologous tooth processing is a system that treats patients with extracted teeth safely as minimal immune response is induced. Until now, and to our knowledge, no specific criteria have been defined for tooth type for such an application. Deciduous and adult teeth were successfully used, impacted and unimpacted third molar.¹⁶ However, the teeth chosen for the host's safety were restorations, caries-free, and endodontic treatment. For a practitioner, autogenous tooth presents an exciting alternative to the autologous bone as they provide chairside ease of preparation. A Korean team (2009) developed a technique for creating bone transplant materials from autogenous teeth following demineralisation, freezing, drying, and sterilisation (►Fig. 2). Therefore, the graft material can be stored at room temperature for up to 5 years for a patient, probably requiring subsequent procedures.⁷ Korea Tooth Bank claims that it can deliver tooth-based materials on demand.^{7,22} Compared with allografts, autografts have the most rapid and extensive osseointegration.²⁵ Allografts can trigger an immunological reaction in the recipient since they are not genetically matched; nevertheless, fresh allografts induce higher immunologic responses than fresh-frozen or freeze-dried allografts.²⁶ Thus, the Tooth Bank may also provide allogeneic tooth bone graft material, which is available in various forms and sizes. The mouth cavity, which is warm and wet, forms a complex structure termed biofilm or plaque. To avoid microbial contamination that could impair

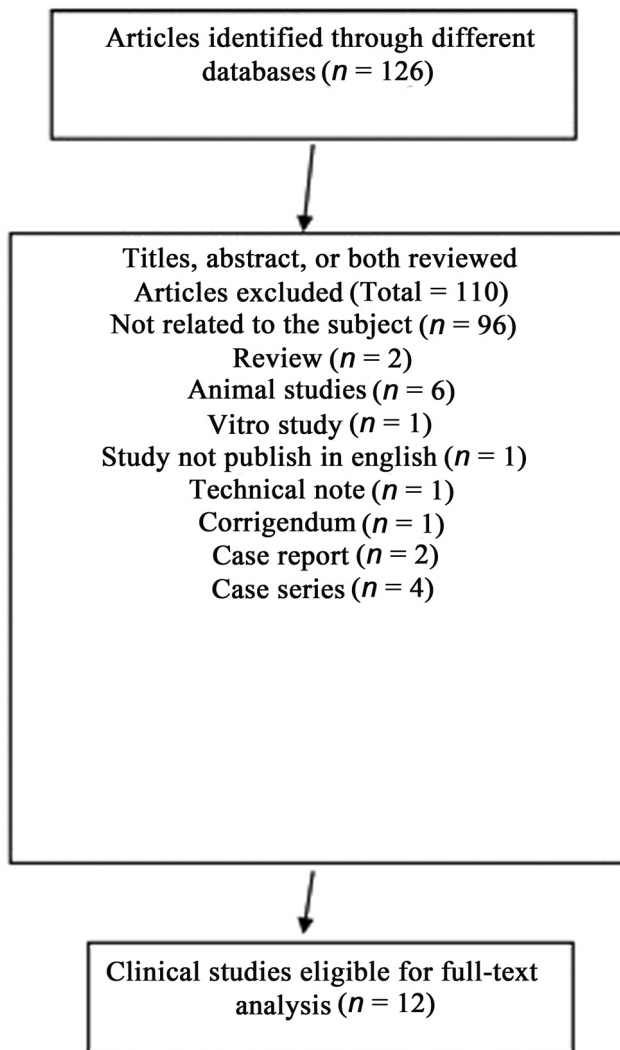


Fig. 1 Flow-chart for manuscript inclusion.

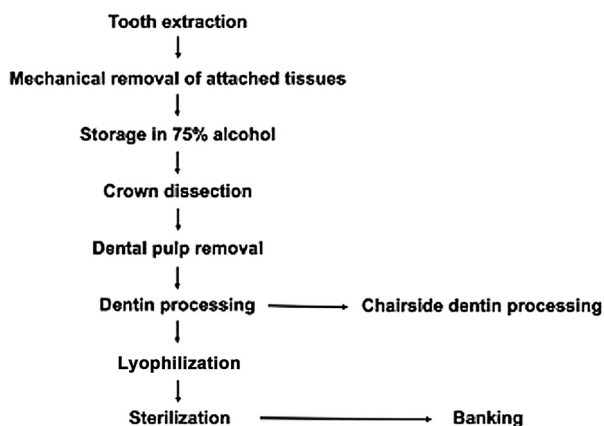


Fig. 2 Flow-chart for manuscript inclusion.

osteogenesis and induce bone resorption, tooth-based material must be sterile, without microbial or microbial-product contaminants. Several procedures of decontamination upstream or downstream dental processing have been described. Therefore, following extraction, teeth are immersed in 4% hydrogen oxide,

75% basic ethyl alcohol, or chlorhexidine solution. Ethylene oxide was used downstream of dental processing and lyophilisation. Ethylene oxide sterilisation has the advantage of being an industry standard, second only to gamma irradiation. Although there is evidence that ethylene oxide can kill viruses in allografts, harmful residues may remain after treatment.²⁷

Manufacturing of Tooth Graft Materials

Following the excision of associated soft tissues, an anatomical tooth crown section is currently dissected as the chemical composition of enamel. Indeed, in contrast to the low-crystalline apatite from dentin and cementum, enamel's high-crystalline apatite is difficult for osteoclasts to break down, resulting in delayed resorption and poor osteoconductivity.²⁸ In terms of elastic and flexible qualities, enamel behaves more like metal (elastic modulus > 100 GPa).²³ The enamel-based material was considered suitable for maintaining volume rather than osseointegration. Although the dental pulp contains DSPCs with regenerative features close to bone marrow-derived mesenchymal stem cells, most protocols recommend removing this soft tissue before tooth processing. Tooth graft materials from dentin and cementum parts are divided into a block- and/or granule-based materials (BBM and GBM).⁶

Block-Based Materials

The clinical application of block-based material (BBM) represents approximately 9% of the clinical application. Made from dentin, the most voluminous structural component, BBM osteoinductive properties are attributed to their blood wettability, while their osteoconductive properties are mainly attributed to the space-maintaining abilities.⁶ BBM has superior handling properties following hydration in 0.9% NaCl solution for 30 minutes. Operators can slice it with a surgical knife and firmly fixed without other tools. In dentistry, BBM with root forms is appropriate for the preservation and reconstruction of extraction sockets and extensive bone defect reconstruction. In orthopaedic applications, few preclinical studies showed osseointegration of the root on types graft in the femur and tibia bone defects.^{29–31} Graft revascularisation is required for graft-bone ankylosis. The blood vessels in non-vascularized grafts slowly penetrate the graft from the recipient's bone, prolonging healing time.³⁰ Following implantation, the revascularization of cancellous bone grafts occurs faster than cortical bone grafts, as the large pores between trabeculae allow the capillary and vascular tissue invasion, thereby promoting osteogenesis. Thus, creating artificial macropores increases the surface area and supports vascular invasion and bone formation.³¹

Granule-Based Material

With approximately 75% of the clinical application, GBM can be obtained from the crown and/or root grinding.³² Clinicians can make a chairside bone graft with a particle size ranging from 300 to 1200 mm that is disinfected and can be used in 8 minutes using a commercial tooth grinding device (i.e., tooth transformer or dentin grinder).³³ The resulting particle volume is roughly two to three times the tooth's original volume. (i.e., a tooth weighing 0.25 g produces at least 1 cm³ of particulate).³⁴

Clinicians prepare the desired particle size depending on the intended use. Small particles (less than 300 μm) enable rapid bone resorption and remodeling, while larger particles (more than 1200 μm) are thought to protect against rapid bone resorption. Many studies have shown that bovine bone particles with a diameter of 300 μm have superior bone formation¹¹, while bigger particles with 1000 μm have inferior bone growth.¹¹ The degree of porosity and its disposition directly influences the biological behavior of bone graft materials.³⁷ GBM comprises a porous network with a total porosity of 55%.¹¹ The appropriate granule absorption rate is also essential for improved bone repair. The crystallinity of apatite in bone is minimal, with nanometer-scale particle sizes. Biodegradation in the human body will become impossible when crystallinity and particle size grow, lowering osteoconductivity. Because of its degradation rate, small particles seem suitable for bone regeneration.¹

Demineralised Dentin Matrix

The technique for transforming teeth into acceptable grafting material is the most critical phase in the entire surgery. Studies claimed that removing any highly crystalline inorganic substances and exposing osteogenic components and collagen matrix are required for a successful tooth-based graft in the bone defect.³⁵ To achieve that, partially demineralised or DDM have been processed using environmentally-friendly aqueous-based methods. As for demineralised bone matrix³⁶, and in contrast to previously described tooth-based material, demineralised dentin does not contain viable cells. Demineralized dentin is a composite of collagen, noncollagenous proteins, and growth factors, a variable percent of residual calcium phosphate mineral. The resulting dentin-derived collagen is the most highly insoluble matrix due to its cross-linking, which could be remodeled following enzymatical actions. The mineral part of BBM or GBM is extracted with acidic treatment (0.5–0.6 N hydrochloric acids, 2% nitric acid, 10% citric acid, or 10% ethylenediaminetetraacetic acid). The demineralisation rate depends on the material's size and the incubation time. Koga et al reported that 70% dentin demineralisation takes approximately 20 minutes, while complete demineralization takes around 180 minutes for 1000 μm particles.¹ As described above, several critical parameters for improving the efficiency of bone graft materials are the overall structure, including geometry and size of particles, pore shape and size, and the pore interconnection pathway. Thus, the biological and clinical justification for DDM relies on the structural changes, such as the exposure of organic matrix, mainly type I collagen, to osteogenic cells such as mesenchymal stem cells and osteoblasts, allowing their attachment and their differentiation.³⁷ As demineralized time rises, the surface structure of the matrix displayed the exposure of dentinal tubules and intertubular and peritubular fiber bundles loss, providing a rough surface required for cell attachment.⁶ Pobloth et al demonstrated that the channel-like pores of a scaffold provided a guiding structure for extracellular matrix alignment and progenitor cell recruitment

and vascularization.³⁸ Despite an increase in dentinal tubules at the surface, their size remains too small for the cell and capillary ingrowth. To increase the porosity, demineralized dentin-BBM was perforated, creating pores (with 0.5 to 1 mm in diameter, 30 uniformly distributed holes). New bone ingrowth was seen in most perforated demineralised dentin block parts, including the outer edge, the inner pulp cavity space, and the perforated macropores.^{6,31} The reduction in the mineral content and the increase in tubular size are thought to favor the bioavailability of osteogenic growth factors such as TGF- α , BMP-4, BMP-2, and BMP-7 that are entangled within the composite matrix.³⁹ Ground DDM results in variable particle size, geometry, and surface area. As a result, some debate about the appropriate particle size and size range for DDM preparations shows that larger particles (500–1000 μm) have higher osteoinductive characteristics than fine particles less than 250 μm . These letters are thought to be phagocytosed by giant cells and digested by enzymes.⁴⁰ We cannot exclude the potential role of the mechanical properties of completely demineralized dentin. Indeed, the loss of mineral content compromises its mechanical qualities, making it unsuitable for usage in stress-bearing sections of the bone.⁴⁰ Additionally, to the structural changes, the chemical composition of demineralized dentin plays an essential role in improving the efficiency of the graft materials. Physicochemical characterization of partially demineralised dentin GBM or BBM contains 5 to 10% or 10 to 30% mineral, amorphous calcium phosphate, β -tricalcium phosphate (β -TCP), one and octacalcium phosphate phases.^{6,23} The residual calcium phosphate showed excellent bioactivity. Calcium and phosphorous ions are released, causing the apatite to reprecipitate on the surfaces, increasing the osseointegration of the dentin graft material.¹³

Deproteinised Dentin Matrix

Deproteinisation aims to abolish all protein content, preventing the host's immune and inflammatory response by maintaining surface morphology and mechanical integrity of the remaining tooth structure. Thermal and/or chemical treatments are commonly used procedures for this proposal. Heated deproteinisation broke down the hydrogen bond of a polypeptide chain. Thermogravimetric analysis-differential thermal analysis of heated tooth showed that the decomposition of organic matrix ranged from 300 to 550°C.⁴¹ After annealing at temperatures above 1000°C, the tooth became bioceramic-like.⁴⁴ The heated-deproteinization technique is simple and quick, but the low-temperature thermal treatment (500°C) could not eliminate the protein content.⁴¹ To achieve complete deproteinisation, a dual thermal and chemical deproteinisation procedure was proposed. The chemical deproteinisation by sodium hydroxide and hydrogen peroxide alters pH and results in protein precipitation. The two-step deproteinisation took longer and increased the discoloration of the teeth particles.⁴¹ Heat/sodium hydroxide dual treatment showed a higher deproteinisation rate than heat/hydrogen peroxide dual treatment. At the same

time, both dual treatments revealed a wider dentinal tubule (diameter 1–2 µm) than in untreated dentin; heat/sodium hydroxide treatment results in a rough dentin surface. Thermal and heat/hydrogen peroxide dual treatments kept the smooth dentin surface.⁴¹ The elemental analysis of deproteinised GBM revealed that the Ca:P ratio ranges from 1.5 to 1.8, similar to the Ca:P ratio of cortical and cancellous bone. But the calcium and phosphate drop to 10 to 20% in weight volume, suggesting a decrease in the bioactive ability of GBM to bond to the bone directly.⁴¹

In Vitro Evaluation

The initial step in screening tooth-derived material biocompatibility was to conduct cytotoxicity tests using cell culture-based methodologies.⁴² Although almost all studies did not relate a cytotoxic effect of tooth-derived material in culture, Tabatabaei Mirakabad observed a dose-dependent cytotoxic effect. Therefore, a concentration of 20 mg/mL of GBM was not cytotoxic regarding human dental pulp stromal cells, while 40 mg/mL decreased the cell viability significantly after 48h of culture.⁴³

Bone biomaterials should provide a platform to support osteogenic cells' adhesion and function conditioned by their intrinsic features, such as structural, mechanical, and physicochemical features. As described above, dentin's demineralisation deeply affects dentin's structural and physicochemical characteristics. The partially DDM showed a higher bone regenerative activity than the demineralized or demineralized dentin matrix.¹ Demineralization allows the enlargement of dentinal tubules, but the resulting pores' size remains too small for cell infiltration and ingrowth. In contrast, loosening the collagen network following demineralisation provides surface microroughness or microtexture for cell adhesion and proliferation. The demineralisation process aids proteins and growth factors released from the organic matrix. The reduction in the mineral content and the increase in tubule size are thought to favor the bioavailability of osteogenic growth factors.³⁹ Enzyme-linked immunosorbent assay experiments showed that demineralised dentin releases and activates the stored growth factors such as BMPs, IGF, FGF, and TGF- α .^{23,32} Few studies have found that protein components in teeth cause solid inflammatory reactions, which directly affect tissue repair and new bone production.^{23,44} Thermal and/or chemical treatments are proposed as successful protocols for the effectively deproteinisation of a tooth. The evaluation of annealed tooth-powder's direct and indirect cytotoxicity did not show a cytotoxic effect on human alveolar bone marrow stem cells.⁴¹ MC3T3-E1 osteoblasts cell line adheres and proliferates to the surface of chemical (sodium hydroxide) and thermal-treated tooth powder, forming a multilayered and dense cell sheet accumulated after 7 days of culture.⁴¹ Several researchers claimed that deproteinisation of tooth-derived materials decreases immunogenicity and prevents the host's immune following implantation. However, to the best of our knowledge, any in vitro evaluation of the inflammatory and immune cell response to deproteinized GBM or BBM was found in the literature.

In Vivo and Preclinical Evaluations

Human, rodent, and bovine tooth-based materials have been researched for efficacy as bone substitutes. Whatever studied species, the site of implantation (calvaria, mandible *versus* femur and tibia), the form (granular *vs.* block), and the process (demineralised, demineralised, thermal treatment, chemical treatment), the tooth-based materials showed, in the most of studies, good biocompatibility with a minimal inflammatory reaction. Bone graft materials should be kept in place and reabsorbed until new bone growth occurs. Several studies that looked at the influence of dentin demineralisation on bone formation found that as the amount of graft demineralisation increased, the rate of graft resorption increased as long as there was a limited inflammatory reaction surrounding the dentin graft.⁴⁷ Grafting dentin caused fibrous encapsulation, which hampered bone repair. This is most likely owing to micromovements generated by the dentin graft's nonfixation during the bone healing phase.⁴⁵

Regarding the definition of osteoinduction and the osteoconduction established by Tanoue et al,⁴⁶ the in vivo studies revealed that demineralized tooth matrix set high standards for osteoinduction and osteoconduction validations. The standard in vivo biological assay for bone induction in mice ectopic site showed that demineralized GBM induced independently bone and cartilage formation after 4 weeks of implantation^{3,23} versus 8 weeks for demineralized GBM.⁷

Compared with demineralised GBM, partially demineralised particles induced a higher osteoid formation following implantation in calvaria bone defect.¹ Osteocytes of the newly formed tissue in contact with partially demineralised particles formed a network connected by their cellular processes.⁴⁷ Other researchers discovered that when human demineralized dentin is inserted in the marrow space of a rabbit tibia, near-native bone, it encourages new bone formation, implying that the osteoconductive qualities of dentin play a more significant role during graft healing than the osteoinductive properties.⁴⁸

The bone induction sequence was comparable to that of the demineralised bone matrix. Four a few authors recommended using dentin particles ranging from 250 to 500 µm in size in bone site defect for better osteoinduction.⁴⁹ A complete resorption of demineralised dentin granules (less than 250 µm) occurred before bone formation.¹ Dentin–bone ankylosis and new bone formation were reported at 4 to 8 weeks postimplantation. Artificial macropores (holes of 250 µm in diameter) were performed to improve the blood vessel ingrowth within BBM.³¹ Compared with the TCP (Chronos), perforated dentin slices showed complete peripheral angiogenesis up to 14 days postimplantation in calvaria defect.^{50,51}

Other strategies have been employed to increase the bone regenerative capabilities of dentin. Kamal et al conducted a study on 16 New Zealand rabbits and improved surgical handling of dentin granules during graft insertion into alveolar clefts by creating a composite putty-TCP/HA and dentin granule mixture, limiting dentin graft mobility and improving graft stability in the defect. Putty β -TCP/HA/

dentin granule mixture had a statistically more significant bone volume fraction after 8 weeks, bone mineral density, and % residual graft volume than putty β -TCP/HA.⁵⁰ The use of a DDM as a carrier for recombinant human BMP-2 (rhBMP-2) has been proposed.³¹ The incorporation of rhBMP-2 in demineralised dentin was achieved by physical adsorption or entrapment within nanoporous dentinal tubules.⁴ Demineralized matrix/rhBMP-2 showed a mature bone with bone marrow at 2 weeks in mice and 4 weeks in rabbits.⁴⁷

Discussion

It is hard to evaluate radiographic and clinical effectiveness with different forms of bone grafts for osseous defects, owing to the variety of abnormalities and their locations observed in clinics and comparison research paucity. Regardless, a few broad generalisations can be derived from the literature on this subject. Due to the graft material's simplicity, the iliac crest is the most popular site for autologous bone grafting. Autografts are desirable because of their integration, rapid healing pace, and natural biocompatibility. On the other hand, autologous bone is undoubtedly a poor choice for osseous defect repair due to the frequency and severity of harvest site morbidity, especially when all other bone grafting options are devoid of this possible consequence.⁵¹

Clinical Applications of Autogenous Demineralised Dentin Matrix

Many clinical trials have been conducted on guided bone regeneration (GBR), socket preservation, and ridge augmentation. GBR is a surgical procedure that uses barrier membranes with or without particulate bone grafts or/and bone substitutes; socket preservation is a type of bone grafting procedure designed to protect the alveolar ridge and empty tooth socket from decaying and a ridge augmentation procedure is performed by placing tissue or a bone graft to fill the void from your missing tooth and to create a healthy base for dental implants. Such studies revealed that new bone was generated by osteoinduction and osteoconduction, with crystal bone resorption averaging 0.29 mm (0–3.0 mm) during the follow-up period.⁷ The average bone loss 8 months after prosthetic loading in the GBR group (14 implants) was 0.29 mm. In contrast, the average bone loss 7.6 months after prosthetic loading in the sinus graft group (14 implants) was 0.66 mm.³⁷ About 0.47 mm crestal bone loss was found in a GBR case series research with 15 patients and a 31-month follow-up period.²³

Another case series research on extraction socket preservation found that after 22.5 months (12–34 months) of functional loading, the average crestal bone loss around the implant was 0.05 mm. Because of its osteoconductivity and bone remodeling capabilities, the 3-month specimen showed newly created tissues.²³ A prospective, randomized clinical investigation comparing the clinical efficacy and histological outcomes of autogenous DDM with inorganic bovine bone in postextraction alveolar bone augmentation (BioOss, Geistlich, Switzerland) found that autogenous DDM was just as successful as inorganic bovine bone.¹¹

Demineralised Dentin Matrix Blocks

In 12 patients, the first clinical report using autogenous DDM blocks for socket preservation revealed excellent bone growth and strong DDM block integration into the recipient's bone.⁵³ During the early phases, the alveolar bone volume was maintained vertically and horizontally, and the produced bone was not resorbed. On histological evaluation, there were aponeurotic fusions between the gingiva and the DDM block, osteocytic embedding, osteoclastic resorption, and vascular invasion into the DDM block.

A case series study based on 22 patients who received a single implant with a DDM block in the posterior area of the maxilla (12 patients) or the mandible (10 patients) was performed with an average follow-up period of 44 months to evaluate the fate of DDM blocks during long-term follow-up observations. The results were compared with those of earlier short-term investigations, indicating that DDM blocks can reconstruct continuously under a functional load while maintaining proper volume.⁵⁴

Sinus Bone Graft of Demineralised Dentin Matrix Powder

Dr. Murata presented the first clinical instance of a sinus lifting treatment employing autogenous DDM at the 2003 IADR Congress.³ Lee⁵⁵ compared the efficiency of DDM to that of various other scaffolds in the sinus in a histomorphometric analysis. After 4 months, all groups had new bone formation around the transplant material and implant in the sinus. In patients treated with DDM or synthetic materials (11 patients/group), the quantity of bone resorption in the sinus was assessed using the crestal approach. The average bone resorption height was 0.76 mm in DDM and 0.53 mm in synthetic materials 1 year after the graft, demonstrating that DDM is an excellent alternative to synthetic bone graft for a bone-augmented sinus lift.^{56–60}

Limitation and Fi-index Tool

1. Limited number of studies: There may be a need for more high-quality studies explicitly focusing on tooth fragments for bone regeneration. The limited number of eligible studies can affect the overall strength and reliability of the systematic review.
2. Heterogeneity among studies: The included studies in the systematic review may vary regarding patient characteristics, sample sizes, methodologies, and outcome measures. This heterogeneity can make it challenging to pool and analyze the data meaningfully and statistically robustly.
3. Publication bias: There is a possibility that studies with positive results showing the effectiveness of tooth fragments for bone regeneration are more likely to be published. In contrast, studies with negative or inconclusive findings may remain unpublished. This publication bias can influence the overall conclusions drawn from the systematic review.
4. Methodological quality of studies: The systematic review relies on the quality of the included studies. The

systematic review's conclusions may be compromised if the selected studies have methodological flaws, such as small sample sizes, lack of blinding, or inadequate control groups.

5. Variability in tooth fragment characteristics: Tooth fragments used for bone regeneration may vary in size, shape, composition, and preparation techniques. This variability can influence their regenerative potential and complicate the synthesis of results across studies.
6. Lack of long-term data: Many studies on tooth fragments for bone regeneration may have short follow-up periods, limiting the ability to assess this approach's long-term efficacy and safety. Long-term data are crucial for understanding tooth fragment-based regeneration's durability and potential complications.
7. Clinical relevance: The systematic review may encounter challenges in determining the clinical significance of the findings. Translating the outcomes from controlled studies into real-world clinical practice can be complex, as various factors may influence treatment outcomes in different clinical settings.

This manuscript has been checked with the Fi-index tool and obtained a score of 0 for the first author only on the date 10/05/2023, according to SCOPUS.^{61,62} The fi-index tool aims to ensure the quality of the reference list and limit any autocitations.

Conclusion

Autogenous tooth bone graft is suitable to replace allograft, xenograft, and alloplastic bone grafts. There are no hereditary or infectious hazards with autogenous tooth bone graft material. Having good strength, it can bring about regeneration through its properties of osteoconduction and osteoinduction. Apart from that, this graft is convenient for clinicians and patients and very reasonable cost-wise. It is a graft material and should be researched further to confirm its osteogenic effects and biological safety. Future perspectives of this manuscript on teeth structure and composition versus alveolar bone can encompass several areas of research and development. Here are some potential future directions:

1. Tissue engineering and regenerative medicine: Advances in tissue engineering techniques may allow for bioengineered dental and bone tissue development. Researchers could use stem cells derived from dental pulp or alveolar bone to generate functional teeth or bone grafts in the laboratory. This could revolutionise dental and orthopaedic treatments by providing personalised and biocompatible solutions.
2. Biomimetic materials: Inspired by the similarities in composition between teeth and alveolar bone, biomimetic materials can be developed that mimic the structure and properties of natural teeth and bone. These materials could be used in various applications, such as dental restorations, implants, and bone graft substitutes, to enhance their performance and integration with the surrounding tissues.

3. Improved bone grafting techniques: Further research can focus on optimising the processing and preparation of autogenous tooth-based bone graft materials. This includes exploring different demineralisation methods, sterilisation techniques, and preservation strategies to improve tooth grafts' safety, efficacy, and shelf-life. Standardising criteria for tooth selection and evaluating the long-term outcomes of tooth-based bone grafting procedures would also be valuable.
4. DPSCs: DPSCs have great potential for tissue regeneration and repair. Future studies could delve deeper into the characterization, differentiation, and therapeutic applications of DPSCs, both in dental and nondental contexts. Understanding the molecular mechanisms underlying their regenerative properties could lead to the development of novel therapies for various conditions, including bone disorders and neurodegenerative diseases.
5. Clinical applications and outcomes: Clinical trials and longitudinal studies can provide further insights into tooth-based bone grafting procedures' effectiveness and long-term outcomes. This research can help establish evidence-based guidelines for selecting appropriate patients, optimal surgical techniques, and postoperative care. Comparative studies with other bone graft materials can also contribute to a better understanding of the advantages and limitations of tooth grafts.
6. Immunological response and biocompatibility: Investigating the immune response triggered by tooth graft materials and their long-term biocompatibility is crucial. Understanding how the host immune system interacts with tooth grafts can guide the development of strategies to minimise immunological reactions and promote favorable tissue integration.
7. Advanced imaging and characterization techniques: Advanced imaging modalities, such as micro-computed tomography, electron microscopy, and spectroscopic methods, can provide detailed structural and compositional information of teeth and alveolar bone at various scales. These techniques can aid in characterizing tooth graft materials, assessing their integration with host tissues, and evaluating their long-term stability and functionality.
8. Clinical translation and commercialisation: As tooth-based bone grafting procedures continue to promise, efforts can be directed toward translating research findings into clinical practice. Collaboration between researchers, clinicians, and industry partners is essential to ensure the development of standardized protocols, regulatory approvals, and commercial availability of tooth graft materials.

Overall, the future perspectives of this manuscript revolve around advancing the understanding of teeth and alveolar bone, exploring novel approaches for tissue engineering and regenerative medicine, optimising graft processing techniques, assessing long-term clinical outcomes, and developing innovative strategies to improve patient care in the fields of dentistry and orthopaedics.

Data Availability

Data are available on request to the corresponding author.

Authors' Contributions

V.T.O. and A.P. conceptualized the study; T.N. was involved in methodology; M.M. and G.F. contributed to validation; T.N. helped in formal analysis; C.D.A. was involved in investigation; F.C. and G.M. helped in resources; L.F. contributed to data curation; V.T.O. helped in writing—original draft preparation; A.P. and T.N. contributed to writing—review and editing; G.C. supervised the study; L.F. helped in project administration.

Conflict of Interest

None declared.

References

- Koga T, Minamizato T, Kawai Y, et al. Bone regeneration using dentin matrix depends on the degree of demineralization and particle size. *PLoS One* 2016;11(01):e0147235
- Smith AJ. Vitality of the dentin-pulp complex in health and disease: growth factors as key mediators. *J Dent Educ* 2003;67(06):678–689
- Murata M, Sato D, Akazawa T, Taira T, Sasaki T, Arisue M. Bone and cartilage induction in nude mice using demineralized dentin matrix. *J Hard Tissue Biol* 2003;11:110–114
- Murata. Bone engineering using human demineralized dentin matrix and recombinant human BMP-2. *J Hard Tissue Biol* 2005;14:80–81
- Yeomans JD, Urist MR. Bone induction by decalcified dentine implanted into oral, osseous and muscle tissues. *Arch Oral Biol* 1967;12(08):999–1008
- Park SM, Um IW, Kim YK, Kim WK. Clinical application of auto-tooth bone graft material. *J Korean Assoc Oral Maxillofac Surg* 2012;38:2–8
- Kim YK, Kim SG, Kim KW, Um IW. Extraction socket preservation and reconstruction using autogenous tooth bone graft. *J Korean Assoc Maxillofac Plast Reconstr Surg* 2011;33:264–269
- Kim ES. Autogenous fresh demineralized tooth graft prepared at chairside for dental implant. *Maxillofac Plast Reconstr Surg* 2015;37(01):8
- Joshi CP, Dani NH, Khedkar SU. Alveolar ridge preservation using autogenous tooth graft versus beta-tricalcium phosphate alloplast: A randomized, controlled, prospective, clinical pilot study. *J Indian Soc Periodontol* 2016;20(04):429–434
- Kim YK, Lee JH, Um IW, Cho WJ. Guided bone regeneration using demineralized dentin matrix: long-term follow-up. *J Oral Maxillofac Surg* 2016;74(03):515.e1–515.e9
- Pohl V, Pohl S, Sulzbacher I, Fuerhauser R, Mailath-Pokorny G, Haas R. Alveolar ridge augmentation using dystopic autogenous tooth: 2-year results of an open prospective study. *Int J Oral Maxillofac Implants* 2017;32(04):870–879
- Pang KM, Um IW, Kim YK, Woo JM, Kim SM, Lee JH. Autogenous demineralized dentin matrix from extracted tooth for the augmentation of alveolar bone defect: a prospective randomized clinical trial in comparison with an organic bovine bone. *Clin Oral Implants Res* 2017;28(07):809–815
- Li P, Zhu H, Huang D. Autogenous DDM versus Bio-Oss granules in GBR for immediate implantation in periodontal postextraction sites: a prospective clinical study. *Clin Implant Dent Relat Res* 2018;20(06):923–928
- Parvini P, Sader R, Sahin D, Becker J, Schwarz F. Radiographic outcomes following lateral alveolar ridge augmentation using autogenous tooth roots. *Int J Implant Dent* 2018;4(01):31
- Schwarz F, Hazar D, Becker K, Sader R, Becker J. Efficacy of autogenous tooth roots for lateral alveolar ridge augmentation and staged implant placement. A prospective controlled clinical study. *J Clin Periodontol* 2018;45(08):996–1004
- Del Canto-Díaz A, de Elío-Oliveros J, Del Canto-Díaz M, Alobera-Gracia MA, Del Canto-Pingarrón M, Martínez-González JM. Use of autologous tooth-derived graft material in the post-extraction dental socket. Pilot study. *Med Oral Patol Oral Cir Bucal* 2019;24(01):e53–e60
- Wu D, Zhou L, Lin J, Chen J, Huang W, Chen Y. Immediate implant placement in anterior teeth with grafting material of autogenous tooth bone vs xenogenic bone. *BMC Oral Health* 2019;19(01):266
- Shejali J, Thomas R, Kumar T, Shah R, Mehta DS, Gayathri GV. Immediate ridge augmentation using autogenous tooth root as a block graft in a periodontally hopeless extraction site: a pilot study. *J Oral Implantol* 2020;46(01):41–49
- Kupersschlag A, Keršytė G, Kurtzman GM, Horowitz RA. Autogenous dentin grafting of osseous defects distal to mandibular second molars after extraction of impacted third molars. *Compend Contin Educ Dent* 2020;41(02):76–82, quiz 83
- Tjäderhane L, Carrilho MR, Breschi L, Tay FR, Pashley DH. Dentin basic structure and composition—an overview. *Endod Topics* 2009;20(01):3–29
- Pashley DH. Dynamics of the pulpo-dentin complex. *Crit Rev Oral Biol Med* 1996;7(02):104–133
- Kim YK, Kim SG, Yun PY, et al. Autogenous teeth used for bone grafting: a comparison with traditional grafting materials. *Oral Surg Oral Med Oral Pathol Oral Radiol* 2014;117(01):e39–e45
- Zhang L, Wang DY, Fan J, Li F, Chen YJ, Chen JH. Stability of bonds made to superficial vs. deep dentin, before and after thermocycling. *Dent Mater* 2014;30(11):1245–1251
- Potdar PD, Jethmalani YD. Human dental pulp stem cells: applications in future regenerative medicine. *World J Stem Cells* 2015;7(05):839–851
- Oryan A, Alidadi S, Moshiri A, Maffulli N. Bone regenerative medicine: classic options, novel strategies, and future directions. *J Orthop Surg Res* 2014;9(01):18
- Titsinides S, Agrogiannis G, Karatzas T. Bone grafting materials in dentoalveolar reconstruction: a comprehensive review. *Jpn Dent Sci Rev* 2019;55(01):26–32
- National Institute for Occupational Safety and Health (NIOSH) Pocket Guide to Chemical Hazards. U.S. Department of Health and Human Services, Public Health Service, Centers for Disease Control and Prevention. Cincinnati, OH; 2015
- Bono N, Tarsini P, Candiani G. Demineralized dentin and enamel matrices as suitable substrates for bone regeneration. *J Appl Biomater Funct Mater* 2017;15(03):e236–e243
- Moharamzadeh K, Freeman C, Blackwood K. Processed bovine dentine as a bone substitute. *Br J Oral Maxillofac Surg* 2008;46(02):110–113
- Andersson L, Ramzi A, Joseph B. Studies on dentin grafts to bone defects in rabbit tibia and mandible; development of an experimental model. *Dent Traumatol* 2009;25(01):78–83
- Kabir MA, Murata M, Akazawa T, Kusano K, Yamada K, Ito M. Evaluation of perforated demineralized dentin scaffold on bone regeneration in critical-size sheep iliac defects. *Clin Oral Implants Res* 2017;28(11):e227–e235
- Kim YK, Lee JH, Kim KW, Um IW, Murata M, Ito K. Analysis of organic components and osteoinductivity in autogenous tooth bone graft material. *J Korean Assoc Maxillofac Plast Reconstr Surg* 2013;35:353–359
- Canullo L, Rossi-Fedele G, Camodeca F, Menini M, Pesce P. A pilot retrospective study on the effect of bone grafting after wisdom teeth extraction. *Materials (Basel)* 2021;14(11):2844
- Ahn GJ, Kim YK, Um IW, Kim JY. Evaluation of prognosis of autogenous tooth bone graft material according to the condition of donor tooth. *J Dent Implant Res.* 2015;341:7–11

- 35 Inoue T, Deporter DA, Melcher AH. Induction of cartilage and bone by dentin demineralized in citric acid. *J Periodontol Res* 1986;21(03):243–255
- 36 Gruskin E, Doll BA, Futrell FW, Schmitz JP, Hollinger JO. Demineralized bone matrix in bone repair: history and use. *Adv Drug Deliv Rev* 2012;64(12):1063–1077
- 37 Murata M, Sato D, Hino J, et al. Acid-insoluble human dentin as carrier material for recombinant human BMP-2. *J Biomed Mater Res A* 2012;100(03):571–577
- 38 Pobloth AM, Checa S, Razi H, et al. Mechanobiologically optimized 3D titanium-mesh scaffolds enhance bone regeneration in critical segmental defects in sheep. *Sci Transl Med* 2018;10(423):eaam8828
- 39 de Oliveira GS, Miziara MN, Silva ER, Ferreira EL, Biulchi AP, Alves JB. Enhanced bone formation during healing process of tooth sockets filled with demineralized human dentine matrix. *Aust Dent J* 2013;58(03):326–332
- 40 Murata M, Akazawa T, Takahata M, et al. Bone induction of human tooth and bone crushed by newly developed automatic mill. *J Ceram Soc Jpn* 2010;118:434–437
- 41 Tanwatana S, Kiewjurat A, Suttapreyasri S. Chemical and thermal deproteinization of human demineralized tooth matrix: physico-chemical characterization and osteoblast cell biocompatibility. *J Biomater Appl* 2019;34(05):651–663
- 42 Moharamzadeh K, Brook IM, Van Noort R. Biocompatibility of resin-based dental materials. *Materials (Basel)* 2009;2(02):514–548
- 43 Tabatabaei Mirakabad FS, Akbarzadeh A, Milani M, et al. A Comparison between the cytotoxic effects of pure curcumin and curcumin-loaded PLGA-PEG nanoparticles on the MCF-7 human breast cancer cell line. *Artif Cells Nanomed Biotechnol* 2016;44(01):423–430
- 44 Roberts TT, Rosenbaum AJ. Bone grafts, bone substitutes and orthobiologics: the bridge between basic science and clinical advancements in fracture healing. *Organogenesis* 2012;8(04):114–124
- 45 Mulliken JB, Glowacki J. Induced osteogenesis for repair and construction in the craniofacial region. *Plast Reconstr Surg* 1980;65(05):553–560
- 46 Tanoue R, Ohta K, Miyazono Y, et al. Three-dimensional ultrastructural analysis of the interface between an implanted demineralised dentin matrix and the surrounding newly formed bone. *Sci Rep* 2018;8(01):2858
- 47 Al-Asfour A, Farzad P, Al-Musawi A, Dahlin C, Andersson L. Demineralized xenogenic dentin and autogenous bone as onlay grafts to rabbit tibia. *Implant Dent* 2017;26(02):232–237
- 48 Um IW, Kim YK, Mitsugi M. Demineralized dentin matrix scaffolds for alveolar bone engineering. *J Indian Prosthodont Soc* 2017;17(02):120–127
- 49 Bormann KH, Suarez-Cunquero MM, Sinikovic B, et al. Dentin as a suitable bone substitute comparable to β -TCP—an experimental study in mice. *Microvasc Res* 2012;84(02):116–122
- 50 Kamal M, Andersson L, Tolba R, et al. Bone regeneration using composite non-demineralized xenogenic dentin with beta-tricalcium phosphate in experimental alveolar cleft repair in a rabbit model. *J Transl Med* 2017;15(01):263
- 51 Pape HC, Evans A, Kobbe P. Autologous bone graft: properties and techniques. *J Orthop Trauma* 2010;24(Suppl 1):S36–S40
- 52 Kim YK, Pang KM, Yun PY, Leem DH, Um IW. Long-term follow-up of autogenous tooth bone graft blocks with dental implants. *Clin Case Rep* 2017;5(02):108–118
- 53 Kim YK, Kim SG, Um IW, Kim KW. Bone grafts using autogenous tooth blocks: a case series. *Implant Dent* 2013;22(06):584–589
- 54 Jeong KI, Kim SG, Kim YK, Oh JS, Jeong MA, Park JJ. Clinical study of graft materials using autogenous teeth in maxillary sinus augmentation. *Implant Dent* 2011;20(06):471–475
- 55 Lee J-Y, Kim Y-K, Kim S-G, Lim S-C. Histomorphometric study of sinus bone graft using various graft material. *J Dent Rehabil Appl Sci* 2011;27:141–147
- 56 Kim YK, Lee J, Yun JY, Yun PY, Um IW. Comparison of autogenous tooth bone graft and synthetic bone graft materials used for bone resorption around implants after crestal approach sinus lifting: a retrospective study. *J Periodontal Implant Sci* 2014;44(05):216–221
- 57 McCrea SJJ. Coalescence of inter: osteotomy bone graft material inserted via separate transcrestal sinus osteotomies: a case report and concise review of the literature. *Eur J Dent* 2014;8(04):553–558
- 58 Lacerda-Santos R, Batista RG, Neves SS, et al. Effectiveness of secondary alveolar bone graft on canine eruption: systematic review. *Eur J Dent* 2021;15(03):579–587
- 59 Mathur A, Bains VK, Gupta V, Jhingran R, Singh GP. Evaluation of intrabony defects treated with platelet-rich fibrin or autogenous bone graft: a comparative analysis. *Eur J Dent* 2015;9(01):100–108
- 60 Kresnoodi U, Rahayu RP, Ariani MD, Soesanto S. The potential of natural propolis extract combined with bovine bone graft in increasing heat shock protein 70 and osteocalcin on socket preservation. *Eur J Dent* 2020;14(01):31–37
- 61 Fiorillo L. Fi-Index: a new method to evaluate authors Hirsch-Index reliability. *Publ Res Q* 2022;38(06):465–474
- 62 Fiorillo L, Cicciù M. The use of Fi-Index tool to assess per-manuscript self-citations. *Publ Res Q* 2022;38(9664):684–692