



# Postpneumonectomy Empyema in the Presence of COVID-19 Pneumonia after Non-COVID-19 ARDS

Veronika Leneis<sup>1</sup> Attila Nemeth<sup>2</sup> Christian Schlensak<sup>2</sup> Volker Steger<sup>2</sup>

<sup>1</sup>Department of Thoracic and Cardiovascular surgery, Faculty of medicine, Clinic of university, Eberhard-Karls-University Tuebingen, Tuebingen, Baden-Württemberg, Germany

<sup>2</sup>Department of Thoracic and Cardiovascular Surgery, Clinic of University, Tuebingen, Baden Württemberg, Germany

**Address for correspondence** Veronika Leneis, Faculty of Medicine, Eberhard-Karls-University, Isolde-Kurz-Strasse 28, 84032 Landshut, Germany (e-mail: veronika.leneis@student.uni-tuebingen.de).

Thorac Cardiovasc Surg Rep 2023;12:e51–e53.

## Abstract

### Keywords

- ▶ pleural empyema
- ▶ pyothorax
- ▶ SARS COVID-19 infection
- ▶ pneumonectomy
- ▶ aspergillosis
- ▶ bronchial stump insufficiency

Development of pleural empyema with or without bronchopleural fistula following pneumonectomy presents a major complication with a mortality of 10 to 20%. The surgical goals of bronchopleural fistula treatment are infection control, pus drainage, and lung re-expansion. The main goal is closure of the fistula. This can be achieved with various surgical methods, such as the Clagett or accelerated Weder procedure, omentoplasty, or a transpericardial approach, according to Abruzzini. We present the case of a 58-year-old patient with pleural empyema within the postpneumonectomy cavity in the presence of severe COVID-19 pneumonia after non-COVID-19 acute respiratory distress syndrome (ARDS) and extracorporeal membrane oxygenation (ECMO) therapy. The patient had undergone right-sided pneumonectomy for destroyed lung syndrome after invasive pulmonary aspergillosis

## Introduction

Pleural empyema, or pyothorax, is the accumulation of purulent exudate between the parietal and visceral pleura as a result of infection of the pleural cavity.<sup>1</sup>

Although pneumonia is considered the most common cause of pleural empyema, complications following thoracic surgery, such as trauma, iatrogenic infections, and pneumonectomy, can also lead to pleural empyema.<sup>2,3</sup>

Pneumonectomy can also be associated with other complications. Early complications are those described as occurring within the first 30 days postoperatively. The second most common early complications include postoperative pneumonia. Furthermore, postoperative atelectasis, pulmonary embolism, bronchopleural fistula, wound infection, and postoperative hemorrhage may occur. In the later course, bronchial fistula is prominent, for example, as bronchus

stump insufficiency after pneumonectomy with accompanying pleural empyema.<sup>4</sup>

In the therapy of postpneumonectomy pleural empyema, there are basically two treatment options, surgical therapeutic procedures with additional antimicrobial therapy if needed or pure conservative treatment. The conservative treatment method includes antimicrobial therapy, chest drain placement, and intrapleural fibrinolysis.<sup>5</sup>

This article describes the conservative management of a postpneumonectomy empyema using antimicrobial therapy and placement of a chest drain in combination with daily lavage of the postpneumonectomy space.

## Case Description

A 58-year-old patient with a history of seminoma, lymphoma, hepatitis C infection, and heavy nicotine abuse

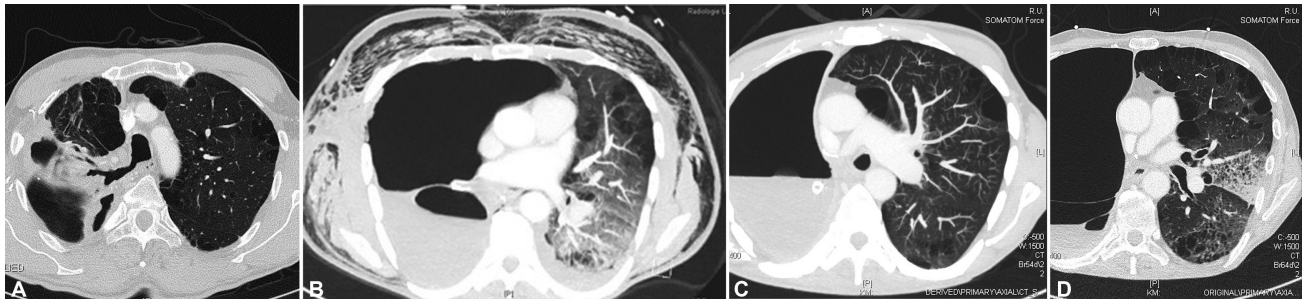
received  
November 14, 2022  
accepted after revision  
December 12, 2022

DOI <https://doi.org/10.1055/s-0043-1771197>.  
ISSN 2194-7635.

© 2023. The Author(s).

This is an open access article published by Thieme under the terms of the Creative Commons Attribution-NonDerivative-NonCommercial-License, permitting copying and reproduction so long as the original work is given appropriate credit. Contents may not be used for commercial purposes, or adapted, remixed, transformed or built upon. (<https://creativecommons.org/licenses/by-nc-nd/4.0/>)

Georg Thieme Verlag KG, Rüdigerstraße 14, 70469 Stuttgart, Germany



**Fig. 1** (A–D) Diagnostics via axial computed tomography (CT). COVID-19 was diagnosed on December 21, 2021. The next available CT is dated January 7, 2022 and thus does not correspond to COVID-19 pneumonia. The CT (C) from January 7, 2022 corresponds to the condition after COVID-19 infection with the question for possible surgery planning. Except for the known aspergilloma for 7 years, no other previous lung diseases are known. (A) Preoperative CT. (B) Postoperative CT. (C) CT before intrapleural lavage with vancomycin. (D) CT after removal of the thoracic drainage.

underwent a right-sided pneumonectomy due to a destroyed lung syndrome after invasive pulmonary aspergillosis (►Fig. 1A; July 3, 2021). On postoperative day 1, he went for a smoke and developed left-sided pneumonia, which led to acute respiratory distress syndrome (ARDS). In addition to left-sided pneumonia, the computed tomography (CT) images (►Fig. 1B) showed subcutaneous emphysema and a slight mediastinal shift to the left. Since these findings were compatible with a bronchopleural fistula, a bronchoscopy was ordered on the third postoperative day, which ruled out a bronchopleural fistula. A venovenous extracorporeal membrane oxygenation therapy (VV-ECMO) was started and carried out for the following 20 days. Shortly before termination of the ECMO therapy, gram-positive cocci and gram-negative *Citrobacter* were detected in bronchial secretions. After ECMO therapy and tracheostomy weaning, the patient was transferred to a pulmonary rehabilitation center. The endotracheal tube was in place from September 26th to October 5th, 2021, and the tracheostomy tube was in place from October 5th to 20th, 2021. No air leak was described. The patient was transferred to the rehabilitation center without a chest tube.

Four weeks later, he presented with partial respiratory insufficiency and fever due to COVID-19 pneumonia of the left lung. Additionally, a bronchial stump insufficiency was suspected. *Staphylococcus aureus* was detected in the pleural punctate. Antibiotic therapy with meropenem was started, which was extended later with cephazolin in place of flu-cloxacillin in accordance with the antibiogram and due to the lower liver toxicity with known hepatitis C infection. Standard supportive therapy for COVID-19 pneumonia with rosuvastatin, urbason, and anticoagulation was continued. The patient had a chest tube placed on the right side at the referring hospital without an air leak after arrival at our center. Bronchoscopy excluded the suspicion of bronchial stump insufficiency.

Due to COVID-19 pneumonia, reduced performance status, and morphologic changes of the lung parenchyma, seen in the computed tomography (CT) scans (►Fig. 1C), we considered the patient inoperable for a thoracoplasty. Daily intrathoracic vancomycin (2 g in 2-L “full electrolyte solution”) irrigation was performed for 11 days via the placed chest tube. After germ-free swabs of the chest tube, final

irrigation with vancomycin, caspofungin, and gentamycin was performed, and the chest tube was subsequently withdrawn (►Fig. 1D). The further hospital stay was uneventful. With a germ-free smear, the chest tube was removed on January 19th, 2022. In the further course, there was a single dyspnea symptom with a drop in saturation, which was resolved by inhalation therapy with salbutamol. The patient spent another 12 days in inpatient care without chest drainage. The patient was transferred to a postoperative rehabilitation clinic. The follow-up was done in an outpatient clinic near his hometown.

## Discussion

Based on this case, we were able to demonstrate that conservative treatment can be successful in the therapy of postpneumonectomy empyema. There is still disagreement in the current literature. The Cochrane collaboration has shown that most recommendations do not take into account comorbidities, underlying lung function, the severity of concomitant or causative pneumonia, the degree of pleural inflammation, and/or the virulence of the pathogens detected.<sup>6</sup>

In this case, surgical treatment of postpneumonectomy empyema was not possible due to the presence of COVID-19 infection and reduced performance status. However, pleural empyema could be successfully treated purely conservatively despite predamaged lung and past COVID-19 infection.

Conservative treatment in our case included established COVID-19 therapy with a glucocorticoid, a statin, and an anticoagulant. After *S. aureus* was detected in the pleural punctate, antibiotic therapy was started with 1 g of meropenem intravenously, three times daily. In addition, the patient received daily intrapleural lavages with 2 g of vancomycin dissolved in 2 L of “full electrolyte solution” for 10 days. This was adapted from our experience with vancomycin irrigation of the pleura in parapneumonic pleural empyema and in the treatment of mediastinitis.<sup>7</sup>

## Conclusion

Our case shows the viability of adequate drainage of the empyema in combination with repeated irrigation of the postpneumonectomy cavity and long-course antibiotic therapy as

an alternative treatment option. We used vancomycin as a local irrigation solution because of its broad spectrum of activity, covering the most common pathogens of pleural empyema.

Conservative treatment in these patients is not the standard therapy but should be considered in patients with reduced operability.

#### Conflict of Interest

None declared.

#### References

- 1 Ubbink DT, Westerbos SJ, Evans D, Land L, Vermeulen H. Topical negative pressure for treating chronic wounds. *Cochrane Database Syst Rev* 2008;3(03):CD001898
- 2 Hecker E, Hecker HC, Hecker KA. Pleuraempyem: Behandlungsstrategien unter Berücksichtigung der Ätiologie. *Zentralbl Chir* 2013;138(03):353–377, quiz 378–379
- 3 Hecker E. Bronchoskopie in der Thoraxchirurgie. In: Nakohosteen J, Scherff A, Darwiche D, Hecker E, Ewig S. Hrsg. *Bronchoskopie und Thorakoskopie*. 4. Auflage Heidelberg: Springer; 2009
- 4 Feindt P. Surgical therapy of lung cancer. *Klin Onkol* 2007/2008
- 5 Hecker E, Hamouri S. Video-assisted thoracoscopic surgery (VATS) for the management of parapneumonic pleural empyema. *Zentralbl Chir* 2008;133(03):212–217
- 6 Höfken H, Hecker E. Standardisierte Therapie des Pleuraempyems per VATS. *Zentralbl Chir* 2011:136-V\_46
- 7 McHugh SM, Collins CJ, Corrigan MA, Hill ADK, Humphreys H. The role of topical antibiotics used as prophylaxis in surgical site infection prevention. *J Antimicrob Chemother* 2011;66(04):693–701