

Transorbital Intracranial Injury by a Chopstick

Rami Darwazeh¹ Xiaochuan Sun²

¹Department of Neurosurgery, Arab Women's Union Hospital, Nablus, Palestine

²Department of Neurosurgery, The First Affiliated Hospital of Chongqing Medical University, Chongqing, China

Indian J Neurosurg 2024;13:84–88.

A 5-year-old girl tripped while carrying a bowl of rice and plastic chopsticks. One of the plastic chopsticks penetrated the medial aspect of the right upper eyelid. In the emergency room, she was fully conscious and without any evident neurological damage. From a computed tomography (CT) study (►Fig. 1A and B) and three-dimensional reconstruction (►Fig. 1C), the chopstick was found to be passing through the right superior orbital fissure into the cranium. No hematoma was found and an angiogram showed no vascular injury. Under general anesthesia, the chopstick was withdrawn without difficulty in one piece (►Fig. 1D) and the patient remained well without any complications. Immediate postoperative CT scan showed no evidence of neural damage or intracranial hemorrhage (►Fig. 1E and F). Postoperative prophylactic antibiotics were administered to prevent infections.^{1–4} Pre- and postoperative ophthalmological examination revealed normal visual acuity and intact ocular movements. The patient was discharged home 5 days after the operation. At a 3-month follow-up, there were no neurological/ophthalmological deficits or intracranial infections.

Among all head injuries, penetrating transorbital intracranial injury accounts for a small percentage.^{1–4} Additionally, such injuries can result in ophthalmoplegia, blindness, brainstem damage, and intracerebral hemorrhage.^{1–4} The management of these types of injuries is complex and the delay in treatment can result in a poor prognosis.^{1,2,4} There are various approaches, which are employed to remove transorbital intracranial penetrating foreign objects, which include direct withdrawal, transorbital or transcranial (frontotemporal, frontal orbitozygomatic, bifrontal, subtemporal, and subfrontal) approaches (►Table 1).^{1–4} Furthermore, all patients with transorbital intracranial injuries by chopstick should receive aggressive broad-spectrum intravenous antibiotics immediately after the injury because of high infection rates.^{1–4}

Address for correspondence Rami Darwazeh, PhD, Department of Neurosurgery, Arab Women's Union Hospital, Nablus, Palestine (e-mail: rami_6600@yahoo.com).

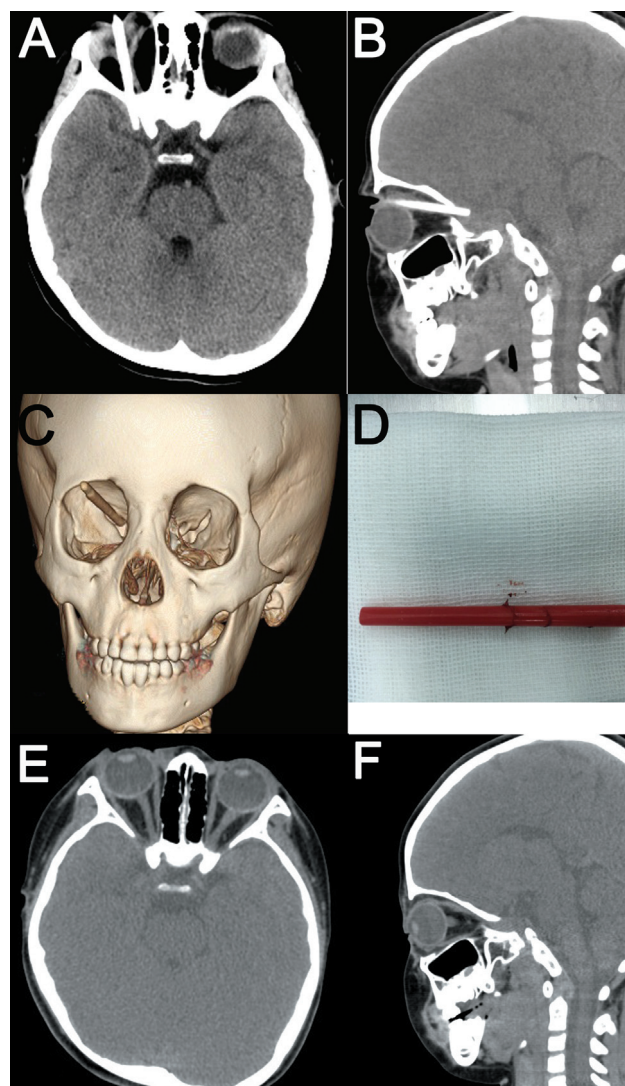


Fig. 1 Noncontrast head computed tomography scans (A, axial image; B, sagittal image) and three-dimensional reconstruction (C) showing the chopstick passing through the right superior orbital fissure into the cranium. An intact chopstick, which measured 5.3 cm in length, was removed in one piece (D). Immediate postoperative noncontrast head computed tomography scans (E, axial image; F, sagittal image) showing no evidence of neural damage or intracranial hemorrhage.

article published online
July 10, 2023

DOI <https://doi.org/10.1055/s-0043-1770907>.
ISSN 2277-954X.

© 2023. The Author(s).

This is an open access article published by Thieme under the terms of the Creative Commons Attribution License, permitting unrestricted use, distribution, and reproduction so long as the original work is properly cited. (<https://creativecommons.org/licenses/by/4.0/>)

Thieme Medical and Scientific Publishers Pvt. Ltd., A-12, 2nd Floor, Sector 2, Noida-201301 UP, India

Table 1 Summary of reported cases of penetrating transorbital intracranial injuries by chopsticks

Number	Authors (year)	Patient's age (y)	Sex	Type of chopstick	Symptoms and signs	Management	Outcome
1	Zheng et al (2022) ⁵	53	Male	Wooden chopstick	Diplopia, paroxysmal headaches, and slow light reflection of the left pupil	Medical treatment (no surgery)	Died
2	Chung et al (2022) ¹	1	Male	Wooden chopstick	Mild upper eyelid swelling, fever, and bloody tears in the left eye	Withdrawn by the guardian (no surgery)	Good outcome without any ophthalmic or neurological sequelae
3	Yamashita et al (2007) ⁶	4	Female	Wooden chopstick	A cut wound on the medial margin of the right lower lid with no swelling or hematoma. A slight disturbance in ocular motility (adduction and downward rotation) and a slight loss of visual acuity in the right eye	Surgery	Favorable outcome
4	Di Roio et al (2000) ⁷	6	Male	Wooden chopstick	Fever, headaches, neck stiffness, and vomiting	Surgery	Favorable outcome
5	Huang et al (2020) ⁸	36	Male	Plastic chopstick	Significant swelling to the ecchymosed right eye	Surgery (transorbital approach)	Residual 10% adduction limitation
6	Matsumoto et al (1998) ⁹	3	Female	Plastic chopstick	Complete loss of vision in the left eye	Surgery	Blindness
7	Sun et al (2016) ²	57	Male	Wooden chopstick	Loss of vision and light reflex in the right eye	Surgery	Blindness
		23	Male	Wooden chopstick	Swollen and bruised right eye. Mydriasis and restricted extraocular movements with left-sided hemiplegia, hemihypoesthesia and right central facial nerve palsy	Surgery (frontotemporal "pterional" approach)	Left hemiplegia
8	Mzimhiri et al (2016) ¹⁰	4	Male	Wooden chopstick	Glasgow Coma Scale score of 5/15 and a 4-mm dilated and fixed pupil on the left eye that was unresponsive to light	Surgery (frontotemporal "pterional" approach)	Died
		2	Male	Wooden chopstick	Pain in the right eyebrow without loss of vision	Surgery (subfrontal approach)	Good outcome without any neurological deficits
		50	Male	Wooden chopstick	Periorbital swelling, headaches, and loss of consciousness for 12 hours after trauma. Glasgow Coma Scale score was 14/15, left diplopia and ophthalmoplegia with partial ptosis. The pupil on the left side was dilated and unresponsive to light with limited eye movements and reduced jaw sensation to touch and pain	Surgery (subtemporal approach)	Favorable outcome

(Continued)

Table 1 (Continued)

Number	Authors (year)	Patient's age (y)	Sex	Type of chopstick	Symptoms and signs	Management	Outcome
9	Park et al (2006) ¹¹	9	Female	Wooden chopstick	Eyelid swelling	Surgery (frontotemporal "pterional" approach)	Good outcome without any deficits
		1	Male	Metallic chopstick	Eyelid swelling and right-side hemiparesis	Withdrawn without difficulty (no craniotomy)	Minimal weakness of the right side
		5	Male	Metallic chopstick	Eyelid swelling, mild left upward gaze limitation, and fever	Withdrawn without difficulty (no craniotomy)	Good outcome without any deficits
		2	Male	Metallic chopstick	Eyelid swelling	Withdrawn without difficulty (no craniotomy)	Good outcome without any deficits
10	Kawamura et al (1997) ¹²	4	Male	Wooden chopstick	3-year-delayed cerebrospinal fluid rhinorrhea	Surgery (bifrontal craniotomy)	Good outcome without any deficits
11	Ishisaka et al (2017) ¹³	1.5	Male	Wooden chopstick	There was only a 1-cm laceration on the right upper eyelid	Surgery	Good outcome without complications
12	Yuan et al (2020) ¹⁴	15	Male	Wooden chopstick	Forehead wound infection, refractory hyperpyrexia, and cerebrospinal fluid leak from the left eye socket	Surgery (frontal craniotomy)	Favorable outcome without reoccurrence of cerebrospinal fluid leak. Neurological examination showed full functional recovery, except for the loss of vision in the left eye
13	Mitilian et al (2009) ³	4	Male	Wooden chopstick	Mild confusion, vomiting, mild exophthalmos with the eyeball deviated upwards, mydriatic reactive pupil, and paresis of the left arm	Withdrawal of the chopstick under computerized tomography control (no craniotomy)	Mild dysmetria in the left arm
14	Shimizu et al (2020) ¹⁵	40	Female	Chopstick (unknown type)	Conjunctival hemorrhage with no direct and indirect light reflex in the left eye	Medical treatment (no surgery)	Loss of vision in the left eye
15	Mzimhiri et al (2016) ¹⁶	50	Male	Wooden chopstick	Painful left eye, swelling, and inability to open the eye for 2 days before admission	Surgery (subtemporal craniotomy)	Dilated pupil and limited eye movements
16	Kim et al (2005) ¹⁷	1.5	Male	Metallic chopstick	Swelling of the right eyelid	Surgery (bifrontal craniotomy)	Good outcome without any deficits

Table 1 (Continued)

Number	Authors (year)	Patient's age (y)	Sex	Type of chopstick	Symptoms and signs	Management	Outcome
17	Kadota et al (1988) ¹⁸	38	Female	Wooden chopstick	Left hemiparesis and hemihypesthesia with right cranial nerve palsy of the 2nd, 3rd, 4th, and 6th nerves as well as the 1st branch of the 5th nerve	Surgery (frontotemporal "pterional" approach)	Right hemiparesis
18	Yamazaki et al (2023) ¹⁹	24	Male	Wooden chopstick	Headache, vomiting, and bleeding from the wound site. Swollen eyelid and inability to open the left eye. Fixed and dilated pupil without reaction to light	Surgery (frontotemporal "pterional" approach)	Left trochlear nerve palsy
19	Matsuyama et al (2001) ²⁰	1	Male	Wooden chopstick	Swollen and bruised eyelid	Surgery (frontolateral craniotomy)	Good outcome without any neurological deficits
20	Shin et al (2012) ⁴	38	Male	Plastic chopstick	Pain, swelling, and numbness around his left eye	Withdrawn without difficulty (no craniotomy)	Nonreactive to light and facial weakness
21	Hiraishi et al (2007) ²¹	14	Female	Plastic chopstick	Fever, headache, and stiff neck 9 years after the injury	Surgery (frontotemporal decompressive craniectomy)	Slight hyposmia
22	Nishio et al (2004) ²²	13	Female	Wooden chopstick	Fever, nausea, and headache 7 years after the injury	Surgery (frontotemporal "pterional" approach)	Good outcome without any deficits
23	Yamasaki et al (2013) ²³	4	Female	Plastic chopstick	Clinical manifestations of meningitis (fever, headache, and stiff neck)	Withdrawn by the patient (no craniotomy)	Favorable outcome

This study describes an unusual case of transorbital intracranial injury caused by a chopstick. In selective cases with no radiological evidence of vascular and neural injuries, the foreign body can be removed straightforwardly without the requirement for a craniotomy. Moreover, pre- and postoperative imaging along with close observation of the patient's condition is essential.

Conflict of Interest

None declared.

Acknowledgment

We would like to thank the Neurosurgery Department of Arab Women's Union Hospital, Nablus, Palestine and the Neurosurgery Department of The First Affiliated Hospital of Chongqing Medical University, Chongqing, China.

References

- Chung YW, Lee SY, La TY. A case of unsuspected trans-orbital-cranial penetrating injury by a wooden chopstick in a one-year-old infant. *Int J Ophthalmol* 2022;15(03):523–526
- Sun G, Yagmurlu K, Belykh E, Lei T, Preul MC. Management strategy of a transorbital penetrating pontine injury by a wooden chopstick. *World Neurosurg* 2016;95:622.e7–622.e15
- Mitilian D, Charon B, Brunelle F, Di Rocco F. Removal of a chopstick out of the cavernous sinus, pons, and cerebellar vermis through the superior orbital fissure. *Acta Neurochir (Wien)* 2009;151(10):1295–1297
- Shin TH, Kim JH, Kwak KW, Kim SH. Transorbital penetrating intracranial injury by a chopstick. *J Korean Neurosurg Soc* 2012;52(04):414–416
- Zheng L, Xu H, Chen X, Li D, Ji X, Wang T. A case of death of purulent meningitis caused by transorbital intracranial penetrating injury due to long-term residual bamboo chopstick. *Leg Med (Tokyo)* 2022;55:102012
- Yamashita K, Noguchi T, Mihara F, et al. An intraorbital wooden foreign body: description of a case and a variety of CT appearances. *Emerg Radiol* 2007;14(01):41–43
- Di Roio C, Jourdan C, Mottolese C, Convert J, Artru F. Craniocerebral injury resulting from transorbital stick penetration in children. *Childs Nerv Syst* 2000;16(08):503–506, discussion 507
- Huang YT, Kung WH, Chang CH, et al. Endoscopy-assisted extraction of orbital and nasal foreign body. *Taiwan J Ophthalmol* 2020;11(04):421–424
- Matsumoto S, Hasuo K, Mizushima A, et al. Intracranial penetrating injuries via the optic canal. *AJNR Am J Neuroradiol* 1998;19(06):1163–1165
- Mzimmbiri JM, Li J, Bajawi MA, Lan S, Chen F, Liu J. Orbitocranial low-velocity penetrating injury: a personal experience, case series, review of the literature, and proposed management plan. *World Neurosurg* 2016;87:26–34
- Park SH, Cho KH, Shin YS, et al. Penetrating craniofacial injuries in children with wooden and metal chopsticks. *Pediatr Neurosurg* 2006;42(03):138–146
- Kawamura S, Hadeishi H, Sasaguchi N, Suzuki A, Yasui N. Penetrating head injury caused by chopstick—case report. *Neurol Med Chir (Tokyo)* 1997;37(04):332–335
- Ishisaka E, Murai Y, Morita A, Shirokane K, Hattori Y, Baba E. Radiological findings of transorbital penetrating intracranial injury in a child. *Childs Nerv Syst* 2017;33(11):2061–2064
- Yuan YK, Sun T, Zhou YC, Li XP, Yu H, Guan JW. Rational design of secondary operation for penetrating head injury: a case report. *Chin J Traumatol* 2020;23(02):84–88
- Shimizu N, Baba T, Watanabe Y, Yamamoto S. Self-inflicted transorbital injury by chopstick in patient with schizophrenia. *BMJ Case Rep* 2020;13(12):e239721
- Mzimmbiri JM, Li J, Xia Y, Yuan J, Liu J, Liu Q. Surviving penetrating brainstem injury by bamboo sticks: rare case reports and a brief review of literature. *Neurosurgery* 2016;78(05):E753–E760
- Kim S, Lee JY, Song JS, Oh J. Transorbital-intracranial injury by a chopstick: three-dimensional computed tomography. *Acta Ophthalmol Scand* 2005;83(05):609–610
- Kadota K, Asakura T, Tamura M, et al. Transorbital intracranial penetration by chopstick. Case report [in Japanese]. *Neurol Med Chir (Tokyo)* 1988;28(11):1128–1132
- Yamazaki D, Ogihara N, Yako T, et al. Transorbital penetrating head injury by a wooden chopstick in the cavernous sinus: a case report and literature review. *Nagoya J Med Sci* 2023;85(01):179–184
- Matsuyama T, Okuchi K, Nogami K, Hata M, Murao Y. Transorbital penetrating injury by a chopstick—case report. *Neurol Med Chir (Tokyo)* 2001;41(07):345–348
- Hiraishi T, Tomikawa M, Kobayashi T, Kawaguchi T. Delayed brain abscess after penetrating transorbital injury [in Japanese]. *No Shinkei Geka* 2007;35(05):481–486
- Nishio Y, Hayashi N, Hamada H, Hirashima Y, Endo S. A case of delayed brain abscess due to a retained intracranial wooden foreign body: a case report and review of the last 20 years. *Acta Neurochir (Wien)* 2004;146(08):847–850
- Yamasaki F, Ohge H, Tsumura R, et al. Transorbital penetrating intracranial injury by a chopstick: a case report and review of the literature [in Japanese]. *No Shinkei Geka* 2013;41(11):1001–1009