

# Updates on the Surgical Approach to Fibroids: The Importance of Radiofrequency Ablation

Caroline S. Kwon, MD<sup>1</sup> Noor Dasouki Abu-Alnadi, MD<sup>1</sup>

<sup>1</sup>Department of Obstetrics and Gynecology, University of North Carolina, Chapel Hill, North Carolina

Address for correspondence Caroline S. Kwon, MD, Department of Obstetrics and Gynecology, University of North Carolina, 4010 Old Clinic Building, Campus Box 7570, Chapel Hill, NC 27599-7570 (e-mail: carolineskwon@gmail.com).

Semin Intervent Radiol 2023;40:335–341

## Abstract

Uterine fibroids are the most common benign neoplasm of the female pelvis and have a lifetime prevalence exceeding 80% among African American women and approaching 70% among Caucasian women. Approximately 50% of women with fibroids experience symptoms which can range from heavy menstrual bleeding and bulk-related symptoms such as pelvic pressure with bladder and bowel dysfunction to reproductive dysfunction (e.g., infertility or obstetric complications) and pain. The choice of treatment is primarily guided by the type of symptoms in the individual patient and whether they prefer to retain fertility. While hysterectomy provides definitive resolution of fibroid symptoms and remains the most common treatment option, this procedure is invasive with a long recovery window. Radiofrequency ablation (RFA) is now emerging as a uterine preserving and minimally invasive therapy for symptomatic fibroids. Since its introduction, growing evidence for safety and efficacy of RFA has been generated with low rates of complications. This review will discuss RFA for the management of symptomatic uterine fibroids with a special focus on technical approaches, short- and long-term outcomes including fertility outcomes.

## Keywords

- ▶ fibroid
- ▶ uterus
- ▶ menorrhagia
- ▶ radiofrequency ablation
- ▶ fertility
- ▶ surgery
- ▶ interventional radiology

Uterine fibroids, also referred to as leiomyomas or myomas, are the most common benign neoplasm of the female pelvis and have a lifetime prevalence exceeding 80% among African American women and approaching 70% among Caucasian women.<sup>1</sup> Approximately 50% of women with fibroids experience symptoms which can be classified into the following categories: heavy or prolonged menstrual bleeding, bulk-related symptoms such as pelvic pressure with bladder and bowel dysfunction, reproductive dysfunction (e.g., infertility or obstetric complications), and pain.<sup>2</sup> The choice of treatment is primarily guided by the type of symptoms in the individual patient and whether they prefer to retain fertility.<sup>3</sup> Hysterectomy provides definitive resolution of fibroid symptoms and has long been known to be the most common treatment option. However, this procedure is invasive with a long recovery window. For patients who do not desire definitive surgical management via hysterectomy or do not use or respond to medical management, alternative uterus-

sparing procedures are highly sought due to their less invasive and fertility-sparing nature.<sup>3,4</sup>

Resecting options include myomectomy via transabdominal, laparoscopic, and hysteroscopic approach. Myomectomy is a surgical procedure to remove uterine fibroids while leaving the uterus intact. In laparoscopy and transabdominal approach, complications include hemorrhage, conversion to hysterectomy, infection, and adhesive disease.<sup>5</sup> Hysteroscopic complications include uterine perforation, urinary tract or bowel injury, cervical laceration, excessive fluid absorption, and embolism.<sup>6</sup> Nonresective options include uterine artery embolization (UAE), magnetic resonance high-intensity focused ultrasound (MR-HIFU), and radiofrequency ablation (RFA). Common complications with UAE include pelvic pain, fever, and vaginal discharge. In this article, we will focus on the utilization of RFA in managing uterine fibroids, as this technique has made the most recent advances as a safe and effective minimally invasive treatment option. Throughout

this review, we will compare RFA to myomectomy given its common overlapping indications, similar procedure characteristics, and due to more favorable patient-focused outcomes compared to other alternatives.<sup>7</sup>

## History of Radiofrequency Ablation

RFA has had broad use in various surgical subspecialties prior to implementation in gynecology. In the 1990s, RFA was first suggested to ablate liver tumors. Since then, RFA has been applied to treat cancers in the adrenal gland, breast, kidney, bone, lung, pancreas, and thyroid.<sup>8-11</sup> In 2002, Bruce Lee, MD, was the first to publish laparoscopic ultrasound-guided RFA of uterine fibroids as a uterine-conserving procedure, known as the Acessa procedure (Hologic; Marlborough, MA).<sup>12</sup> He had considered other forms of fibroid destruction including cryosurgery, microwave, and laser probes but elected to develop a system specifically to treat uterine fibroids using radiofrequency energy due to its safety profile and reliability in ablating fibroids up to 7 cm in diameter.<sup>13</sup> This device received U.S. Food and Drug Administration (FDA) approval in 2012. Another technology focused on a transcervical approach to RFA began its development in 2005. Sonata (Gynesonics, Redwood City, CA) is also an RFA device that uses an incisionless transcervical approach to ablate fibroids. This device received FDA approval in 2018.

RFA is a “volume reduction” procedure. While it can help some women avoid hysterectomy, the uptake of the procedure broadly has not yet soared and is less frequently utilized than UAE. Contributing to this may be that the treatment is not yet been approved for fertility preservation by the FDA. Furthermore, not all insurance companies will cover the cost of the procedure. Healthy, full-term pregnancies after the procedure have been reported, although more data are needed. Researchers are continuing to collect data to provide a more thorough assessment of how the treatment affects fertility.<sup>14,15</sup>

## How Does Radiofrequency Ablation Work?

Radiofrequency ablation uses elevated temperature to produce tissue destruction. Heat may be applied by direct thermal conduction or by ultrasound or electromagnetic (RF) energy. Radiofrequency waves, with its long wavelength, low frequency, and low energy on the electromagnetic spectrum (between 3 kHz and 300 GHz), are an ideal candidate for controlled and predictable ablation of tissue. Of note, medical procedures typically use frequencies between 450 and 500 kHz.<sup>13</sup>

Placement of the electrode into a target tissue results in transmission of the current through the tissue with a particular point of entry. The current then travels to the electrode return pads and back to the generator, completing the circuit. Heat is created through ionic (Na, K, Cl) friction and spreads by simple thermal conduction, producing a volumetric ablation through coagulative necrosis.

Human cells die nearly immediately at 60 °C; proteins start to denature once a fibroid becomes appropriately

heated to this temperature. Higher temperatures between 60 and 99 °C are desirable to produce a larger ablation volume in a shorter amount of time.<sup>9</sup> However, temperatures greater than 100 °C produce local tissue charring and vaporization which cause lower current density and insulation, decreasing both heat generation and conduction. This can potentially result in incomplete ablations. Therefore, a slow, methodical deposition of energy is more effective in ablating target tissue rather than a rapid and high temperature rise.<sup>16</sup>

## Types of Radiofrequency Ablation

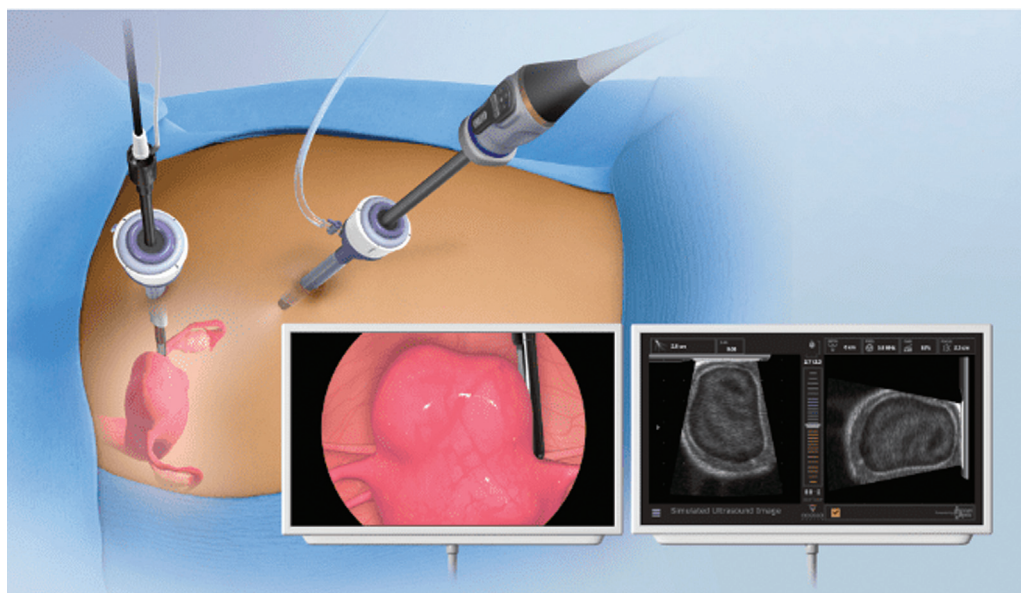
Both laparoscopic RFA and transcervical RFA are safe and effective procedures once proceduralists have been appropriately trained on their use. RFA can be quickly learned with a majority of gynecologists noting confidence and no increase in adverse events compared to experienced RFA surgeons after performing their fifth proctored procedure.<sup>17</sup> In contrast, myomectomy and hysterectomy require 40 to 50 cases to achieve surgeon competency. While both technologies utilize ultrasound guidance to direct placement of monopolar, expandable, radiofrequency electrodes into myomas, they do differ in how they achieve this.

### Laparoscopic RFA (Acessa Procedure)

The Acessa procedure utilizes laparoscopic radiofrequency volumetric tissue ablation by utilizing low-voltage, high-frequency alternating currents (► **Fig. 1**). Two standard laparoscopic ports are placed, a 5-mm umbilical port for the laparoscope and a 10-mm suprapubic port for the ultrasound transducer. Since the laparoscopic ultrasound transducer is placed directly on the uterine surface, the image produced has significantly greater resolution which is beneficial to locate fibroids that may have otherwise gone undetected. Next, the handpiece is placed percutaneously through a small skin incision, advanced to the fibroid, and carefully inserted 1 cm into the fibroid capsule. Depressing the foot pedal initiates the ablation. The electrode array is deployed into the fibroid. The elevated temperature from the device causes tissue destruction by heat created through ionic friction which then spreads by conduction resulting in cellular death.<sup>6</sup> After the ablation duration is complete, the foot pedal is again depressed to stop the procedure. The electrode arrays are then retracted, and the handpiece tip is allowed to cool for 60 seconds prior to removing from the target tissue.<sup>18</sup> Patients return home the same day and require only NSAIDs for pain management.

### Transcervical RFA (Sonata System)

The Sonata system enables sonography-guided RFA of uterine fibroids using an incisionless, transcervical approach (► **Fig. 2**). With the patient placed in dorsal lithotomy position, the cervix is serially dilated to 27 Fr to ultimately accommodate the 8.4-mm diameter assembled device. The device, consisting of a reusable curvilinear intrauterine ultrasound probe and a single-use RFA handpiece that combines into a single unit, is then inserted transcervically. The RFA handpiece comes equipped with a port for infusing



**Fig. 1** Laparoscopic radiofrequency ablation of uterine leiomyomas. (Reprinted with permission from Gyn Surgical Solutions/Hologic, Inc.)

hypotonic fluid into the endometrial cavity as needed. The device is advanced to the fundus and a survey is performed to identify the size and location of fibroids. Once the desired ablation zone of a particular fibroid has been determined, the tip of the ultrasound probe is articulated to target the fibroid and a sharp cannula is deployed from the shaft of the RFA handpiece, penetrating the fibroid tissue and stabilizing the device. The needle electrodes are then deployed. Once safety has been confirmed, the device is held steady, and the footswitch is pressed to deliver radiofrequency energy. Once the ablation is complete, the RF generator will automatically turn off. The needle electrodes and introducer can be retracted, and subsequent ablation can then be performed on the same fibroid or additional fibroids targeted in the same manner.<sup>19</sup> Patients return home the same day and require only NSAIDs for pain management.

### Multiple Treatment Options: When to Use One Approach Over Another?

Current management strategies mainly involve surgical interventions, but the choice of treatment is guided by patient's age, medical and surgical history, and desire to preserve fertility. The management of fibroids also depends on the number, size, and location of fibroids.

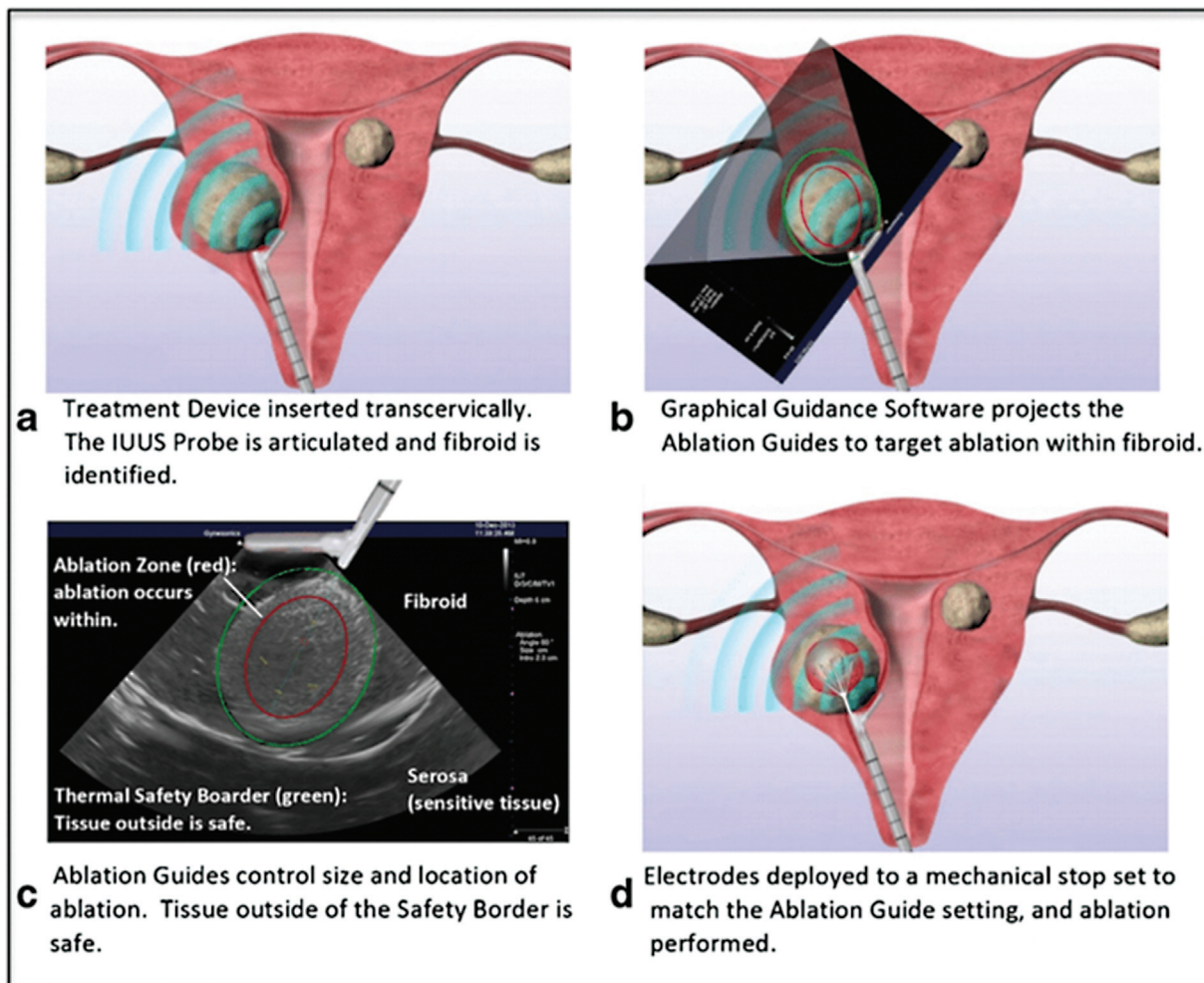
RFA reduces the size of fibroids but does not eliminate them. Its minimally invasive nature, using heat to target fibroids one by one, thus reducing their size significantly, is ideal in improving symptom management and overall quality of life. Recovery is rapid and patients have reported only mild postoperative pain. Post-RFA pregnancy data are currently limited. We recommend RFA in patients with symptomatic FIGO type 2 to 6 myomas who do not desire future fertility.

Laparoscopic hysterectomy is a definitive therapy for fibroids with the lowest reintervention rates and the high-

est rate of symptom relief. It has a range outside of completely curing fibroids; the removal of fallopian tubes has been shown to reduce the risk of ovarian cancer; the removal of ovaries may be recommended for patients who have a family history of ovarian cancer or who test positive for BRCA-1, BRCA-2 gene mutations; and other pathologies such as endometriosis may be addressed concomitantly. We recommend hysterectomy in these situations and when women do not desire future fertility or prefer uterine preservation.

Laparoscopic myomectomy is perceived by many gynecologists to be a more technically complex procedure, but the advantages are real: less severe postoperative morbidity, faster recovery with laparoscopic procedures, and no significant difference between reproductive outcomes after laparoscopic or abdominal myomectomy. However, there have been reports of uterine rupture after laparoscopic myomectomy, thus emphasizing the importance of adequate closure of the myometrial defect. Additionally, perioperative complication rates can be as high as 30% particularly due to increased blood loss.<sup>20</sup> Less than 15% of patients who undergo myomectomy will require a second surgery at 5 years.<sup>7</sup> We recommend laparoscopic myomectomy as the intervention of choice for all fibroids not amenable to medical therapy or hysteroscopic resection in patients who desire future fertility.

UAE is a minimally invasive alternative to hysterectomy or myomectomy, and 85% of women experience improvement in heavy menstrual bleeding, pain, and symptoms related to uterus enlargement.<sup>7</sup> The procedure is especially effective for multiple fibroids and large fibroids. Global uterine size is affected by UAE, while RFA reduces individual fibroid volume only. In addition to its minimally invasive nature, it presents as an alternative to hormone therapy, involves minimal or no hospital stay, allows a quick return to daily activities, and significantly improved quality of life. It is important to note that for patients who desire future fertility, the fertility rates



**Fig. 2** Transcervical radiofrequency ablation with the Sonata system (a-d), demonstrating the SMART Guide which delineates the ablation zone (red ellipsoid) (b, c) and thermal safety border (green ellipsoid) (c). (Reprinted with permission from Lindner LH, Roy K, Toub DB. Transcervical fibroid ablation (TFA) with the Sonata system: updated review of a new paradigm for myoma treatment. *Current Obstetrics and Gynecology Reports* 2022;11(03):238–248.)

post-UAE have not yet been effectively quantified. We recommend UAE for patients who are symptomatic from their fibroids, do not desire future fertility, and wish to avoid surgery such as a hysterectomy.

## Short- and Long-Term Outcomes

### Laparoscopic RFA

Laparoscopic RFA was first studied in fibroids with < 7 cm and less than 14-week-size uterus, but subsequent studies have demonstrated its use in fibroids up to 10 cm.<sup>21,22</sup> Though total adverse events are low (1.78%), a case report of postoperative necrosis and peritonitis in a treated fibroid of > 10 cm dimension has been described.<sup>23</sup> Serosal bowel injury and postoperative pelvic abscess due to ultrasound probe use were also noted in the pivotal HALT trial. The average length of stay is 10.7 hours with mean return to work after 4.3 days.<sup>24</sup>

In the pivotal HALT trial, menstrual blood loss reduction was measured via alkaline hematin.<sup>23</sup> This reduced within 3 months of treatment by 31.8% (95% confidence interval

[CI]: –40.3% to –20.3%) and decreased to 38.3% (95% CI: –45.2% to –31.4%) at 12 months ( $p < 0.001$ ). Similarly, within 3 months, the total mean fibroid volume reduced by 39.8% (95% CI: –44% to –35.6%) with continued decrease at 12 months to 45.1% (95% CI: –51.6% to –38.6%,  $p = 0.001$ ). Decreased symptom severity and increased quality-of-life measures were also noted. Three-year follow-up has shown stable improvement in these two scores. Surgical reoperation rate at 1 year is low at 3.8% but has been reported as high as 11% at 3 years in the HALT follow-up survey.<sup>25</sup> Further evaluation noted that half of the subjects who underwent reoperation at 36 months were diagnosed with concurrent adenomyosis. This of note was an exclusion criterion to receiving RFA in the HALT trial and may account for the need for additional treatment. A meta-analysis of seven studies has shown the overall reoperation rate to be 4.39% (95% CI: 1.6–8.45%;  $I^2 = 65\%$ ).<sup>26</sup> For comparison, the rate of reoperation over the same period of time is 17% for UAE, 21% for hysteroscopic myomectomy, 24% for endometrial ablation, and 11% for laparoscopic myomectomy.<sup>27</sup>

### Transcervical RFA

Transcervical myoma ablation is quick as well as incisionless. The average length of stay is 2.5 hours with over 50% of patients resuming normal activities after 1 day.<sup>28</sup> Transcervical RFA is designed for ablation of not only FIGO type 1 or 2 fibroids but also FIGO types 3, 4, 5, 6, and 2–5. Given the most frequent postprocedure effect is leiomyoma sloughing (in up to 30% of cases), this approach is not recommended for type 0 fibroids.

In the pivotal SONATA trial, the average reduction in total myoma volume was 62.4% ( $n = 128$ ) by 12 months.<sup>28</sup> Menstrual bleeding reduction was defined as a 50% or greater reduction in a menstrual pictogram score in at least 45% of patients; this was achieved in 65.3% (79/121) of patients at 12 months posttreatment. Analysis of the U.S.-only cohort ( $n = 122$ ) from the SONATA trial found 86.3% of patients experienced improved menstrual bleeding as soon as 3 months.<sup>29</sup> Only one patient underwent elective hysterectomy for abnormal uterine bleeding prior to 12 months, but hypermenorrhea can occur postablation. Similar findings regarding decrease in fibroid volume were found in the FAST-EU trial. A clinically meaningful reduction in menstrual blood loss was defined as a 22% reduction in bleeding. This occurred in 37 of 49 (75%) patients by 3 months. Of note, a majority of the fibroids treated in this cohort were type 1 or type 2 in location while the Sonata pivotal trial treated mostly type 3, 4, 5, or 6 fibroids.

Long-term studies have yielded promising results for transcervical RFA. Surgical reintervention rates due to heavy menstrual bleeding remain as low as 9.2% at 3 years and 11.8% at 5.4 years.<sup>30</sup> Quality of life and symptom severity scores remain stable at least until 3 years after treatment with 94% patients reporting continued satisfaction with transcervical RFA.<sup>31</sup> No long-term serious complications related to the device or procedure have been described.

### Comparative Outcomes

Myomectomy is the second most common surgical treatment of fibroids.<sup>32</sup> Only two randomized studies have evaluated the performance of laparoscopic RFA compared to laparoscopic myomectomy given the unique similarities as less invasive procedures with quick recovery (► **Table 1**). In TRUST (Trial of Uterine-Sparing Techniques) and a subsequent 1-year follow-up survey, both procedures led to significant improvement in fibroid-related symptoms such as heavy bleeding, increased abdominal girth, and pelvic pain. Laparoscopic myomectomy resulted in a greater reduction in symptom severity (12.1 vs. 23.4%,  $p < 0.05$ ) and improvement in quality-of-life scores (95.6 vs. 78.7%,  $p < 0.05$ ).<sup>22</sup> At 12 months, less patients who underwent laparoscopic myomectomy reported heavy menstrual bleeding. Contrarily, Brucker et al noted no differences in patient-reported outcomes between the two groups.<sup>33,34</sup> Both trials found decreased operative time, intraoperative blood loss, length of stay, and complication rates in laparoscopic RFA. Interestingly, despite use of intraoperative laparoscopic ultrasound, the total number of fibroids treated by laparoscopic RFA may

be higher than laparoscopic myomectomy.<sup>33</sup> This is likely due to the fact that 1- to 2-cm fibroids can be easily accessed and ablated without the need of a myometrial incision.

There are no studies that exclusively evaluate transcervical RFA and laparoscopic myomectomy. A comparative study (CHOICES) of all routes of myomectomy and transcervical RFA showed higher procedure and hospitalization costs in myomectomy (\$7,563 vs. \$11,425,  $p < 0.002$ ).<sup>35</sup> Operative time and length of stay were shorter with transcervical RFA. The only complications reported were in three myomectomy patients who required perioperative transfusion.

### Fertility Outcomes

Fibroids can cause infertility and adversely affect pregnancy including causing spontaneous abortion, malpresentation, preterm labor, Cesarean delivery, and postpartum hemorrhage.<sup>36</sup> RFA is not approved by the FDA for women who desire future fertility. This is in part due to initial clinical trials excluding premenopausal women who sought childbearing. In one case series of 30 pregnancies following laparoscopic RFA, there were 26 full-term live births (86.7%) and 4 spontaneous abortions (13.3%).<sup>37</sup> This miscarriage rate is similar to the U.S. national average. There was an equal distribution of cesarean and vaginal deliveries (50% each) with the leading indication for cesarean delivery the unknown safety of vaginal delivery following a RFA procedure. No adverse outcomes such as preterm delivery, placental abruption, or placenta accreta spectrum occurred, but one case of placenta previa and postpartum hemorrhage was reported. Though uterine rupture was not recorded, this is a rare event and notably only a 1.7% risk after myomectomy.<sup>38</sup> These overall findings are similar in studies examining transcervical RFA.<sup>39</sup> Further long-term data are needed to assess these less common but serious pregnancy-related risks to guide counseling patients who desire fertility and RFA. Preliminary data suggest childbearing may be safe and a full-term vaginal delivery can be a reasonable expectation.

RFA appears to have less long-term fertility consequences compared to myomectomy. Postablation MRI has shown no reduction in uterine wall thickness or development of myometrial scar.<sup>40</sup> This is an important finding as vaginal delivery may be contraindicated in some patients who undergo laparoscopic or abdominal myomectomy due to risk of uterine dehiscence and rupture. Likewise, postmyomectomy intrauterine adhesion formation can be as prevalent as 45%, but synechiae have not been seen after RFA during hysteroscopic evaluation.<sup>41–43</sup> For women who wish to preserve fertility but are not good candidates for myomectomy, RFA and UAE are both viable options. The patient should be counseled about the limited fertility data for both options.

### Conclusion

The safety and efficacy of RFA for symptomatic uterine fibroids is promising and rapidly emerging. Long-term studies have yielded promising results for both laparoscopic and

**Table 1** Comparison of surgical uterine-sparing interventions for uterine leiomyomas

Intervention	Ideal leiomyoma characteristics	Approach	Notable side effects or risks	Leiomyoma volume reduction at 12 mo (%)	UFS-QOL HRQL score increase	Reintervention rate at 36 mo
L-RFA	FIGO 2–6, < 7–10 cm	Laparoscopic 10 mm + 5 mm incisions, percutaneous puncture	Pelvic infection (rare)	45.1	38.6 (36 mo)	11.0
TC-RFA	FIGO 1–6, < 7–10 cm	Cervical dilation	Leiomyoma sloughing, leukorrhea	62.4	43.7 (36 mo)	8.2
Myomectomy	FIGO 0–7, any size	Hysteroscopic, laparoscopic, minilaparotomy, or abdominal	Blood loss, greater LOS, surgical complications	100	(24 mo)	11.0

Abbreviations: FIGO, International Federation of Gynecology and Obstetrics; LOS, length of stay; L-RFA, laparoscopic radiofrequency ablation; TC-RFA, transcervical radiofrequency ablation; UFS-QOL HRQL, Uterine Fibroid Symptom and Quality of Life, Health-Related Quality of Life.  
Source: Reprinted with permission from Stewart KA, Greenberg JA, Kho KA, Cohen Rassier SL. Radiofrequency ablation of leiomyomas. *Obstet Gynecol* 2023 (publish ahead of print). doi: 10.1097/aog.0000000000005196.

transcervical RFA with low surgical reintervention rates and improved quality of life and symptom severity scores. As reproductive outcomes following RFA are not yet clearly known, further long-term data are needed to assess these less common but serious pregnancy-related risks to guide counseling patients who desire fertility and RFA.

#### Conflict of Interest

Neither author has any conflict to disclose.

#### References

- Baird DD, Dunson DB, Hill MC, Cousins D, Schectman JM. High cumulative incidence of uterine leiomyoma in black and white women: ultrasound evidence. *Am J Obstet Gynecol* 2003;188(01): 100–107
- Barbieri RL. New hormonal medical treatment is an important advance for AUB caused by uterine fibroids. *OBGM* 2020;32(08):. Doi: 10.12788/obgm.0024
- Liao L, Chen L, Melamed A, Hershman DL, Wright JD. Use of conservative therapies before hysterectomy for uterine leiomyomas. *Obstet Gynecol* 2023;141(02):371–374
- Borah BJ, Nicholson WK, Bradley L, Stewart EA. The impact of uterine leiomyomas: a national survey of affected women. *Am J Obstet Gynecol* 2013;209(04):319.e1–319.e20
- Parker WH. Uterine fibroids (leiomyomas): abdominal myomectomy. In: Chakrabarti A, eds. *UpToDate*. Waltham, MA; February 14, 2020
- Bradley LD. Overview of hysteroscopy. In: Eckler K, ed. *UpToDate*. Waltham, MA; December 21, 2020
- Manyonda I, Belli AM, Lumsden MA, et al; FEMME Collaborative Group. Uterine-artery embolization or myomectomy for uterine fibroids. *N Engl J Med* 2020;383(05):440–451
- Nath S, Nath CA, Pettersson K. Percutaneous lumbar zygapophysial (Facet) joint neurotomy using radiofrequency current, in the management of chronic low back pain: a randomized double-blind trial. *Spine* 2008;33(12):1291–1297, discussion 1298
- Doukas G, Samani NJ, Alexiou C, et al. Left atrial radiofrequency ablation during mitral valve surgery for continuous atrial fibrillation: a randomized controlled trial. *JAMA* 2005;294(18): 2323–2329
- Kim YS, Rhim H, Lim HK, et al. Intraoperative radiofrequency ablation for hepatocellular carcinoma: long-term results in a large series. *Ann Surg Oncol* 2008;15(07):1862–1870
- Varkarakis IM, Allaf ME, Inagaki T, et al. Percutaneous radio frequency ablation of renal masses: results at a 2-year mean followup. *J Urol* 2005;174(02):456–460, discussion 460
- Lee BB. Radiofrequency ablation of uterine leiomyomata: a new minimally invasive hysterectomy alternative. *Obstet Gynecol* 2002;99(Suppl):9S
- Hammerich D. Tissue ablation. In: Webster JG, ed. *Wiley Encyclopedia of Medical Devices and Instrumentation*. New Jersey: John Wiley & Sons; 2006:362–379
- Hong K, Georgiades C. Radiofrequency ablation: mechanism of action and devices. *J Vasc Interv Radiol* 2010;21(8, Suppl):S179–S186
- Kho K, Shepherd J, Sobolewski C. Panel 2-RF frequency ablation of uterine fibroids - the new frontier. Presented at AAGL's 50th Global Congress on MIGS; November 15, 2021; Austin, TX
- Goldberg SN, Gazelle GS, Halpern EF, Rittman WJ, Mueller PR, Rosenthal DI. Radiofrequency tissue ablation: importance of local temperature along the electrode tip exposure in determining lesion shape and size. *Acad Radiol* 1996;3(03):212–218
- Jacoby VL, Parvataneni R, Oberman E, et al. Laparoscopic radiofrequency ablation of uterine leiomyomas: clinical outcomes during early adoption into surgical practice. *J Minim Invasive Gynecol* 2020;27(04):915–925

- 18 Accessa ProVu System user guide. Accessa. Accessed April 20, 2023 at: <https://www.hologic.com/package-inserts/gyn-surgical-products/accessa-laparoscopic-radiofrequency-ablation>
- 19 Sonata System instructions for use, with technical appendix. Gynesonics. Accessed April 20, 2023 at: <https://gynesonics.com/us/wp-content/uploads/sites/2/2021/03/LS-03818-009.A-REF-009-IFU-Sonata-2.2.pdf>
- 20 Iversen H, Lenz S, Dueholm M. Ultrasound-guided radiofrequency ablation of symptomatic uterine fibroids: short-term evaluation of effect of treatment on quality of life and symptom severity. *Ultrasound Obstet Gynecol* 2012;40(04):445–451
- 21 Yu S, Bhagavath B, Shobeiri SA, Eisenstein D, Levy B. Clinical and patient reported outcomes of pre- and postsurgical treatment of symptomatic uterine leiomyomas: a 12-month follow-up review of TRUST, a surgical randomized clinical trial comparing laparoscopic radiofrequency ablation and myomectomy. *J Minim Invasive Gynecol* 2022;29(06):726–737
- 22 Chudnoff S, Guido R, Roy K, Levine D, Mihalov L, Garza-Leal JG. Ultrasound-guided transcervical ablation of uterine leiomyomas. *Obstet Gynecol* 2019;133(01):13–22
- 23 Lin E, Sendukas E, Kho KA. Postoperative uterine necrosis and peritonitis following laparoscopic radiofrequency myoma ablation. *J Minim Invasive Gynecol* 2022;29(10):1123–1124
- 24 Bradley LD, Pasic RP, Miller LE. Clinical performance of radiofrequency ablation for treatment of uterine fibroids: systematic review and meta-analysis of prospective studies. *J Laparoendosc Adv Surg Tech A* 2019;29(12):1507–1517
- 25 Berman JM, Guido RS, Garza Leal JG, Pemueler RR, Whaley FS, Chudnoff SG. Halt Study Group. Three-year outcome of the Halt trial: a prospective analysis of radiofrequency volumetric thermal ablation of myomas. *J Minim Invasive Gynecol* 2014;21(05):767–774
- 26 Lin L, Ma H, Wang J, et al. Quality of life, adverse events, and reintervention outcomes after laparoscopic radiofrequency ablation for symptomatic uterine fibroids: a meta-analysis. *J Minim Invasive Gynecol* 2019;26(03):409–416
- 27 Davis MR, Soliman AM, Castelli-Haley J, Snabes MC, Surrey ES. Reintervention rates after myomectomy, endometrial ablation, and uterine artery embolization for patients with uterine fibroids. *J Womens Health (Larchmt)* 2018;27(10):1204–1214
- 28 Chudnoff SG, Berman JM, Levine DJ, Harris M, Guido RS, Banks E. Outpatient procedure for the treatment and relief of symptomatic uterine myomas. *Obstet Gynecol* 2013;121(05):1075–1082
- 29 Hudgens J, Johns DA, Lukes AS, Forstein DA, Delvadia D. 12-month outcomes of the US patient cohort in the SONATA pivotal IDE trial of transcervical ablation of uterine fibroids. *Int J Womens Health* 2019;11:387–394
- 30 Brölmann H, Bongers M, Garza-Leal JG, et al. The FAST-EU trial: 12-month clinical outcomes of women after intrauterine sonography-guided transcervical radiofrequency ablation of uterine fibroids. *Gynecol Surg* 2016;13(01):27–35
- 31 Garza-Leal JG. Long-term clinical outcomes of transcervical radiofrequency ablation of uterine fibroids: the VITALITY Study. *J Gynecol Surg* 2019;35(01):19–23
- 32 Lukes A, Green MA. Three-year results of the SONATA pivotal trial of transcervical fibroid ablation for symptomatic uterine myomata. *J Gynecol Surg* 2020;36(05):228–233
- 33 Gingold JA, Gueye NA, Falcone T. Minimally invasive approaches to myoma management. *J Minim Invasive Gynecol* 2018;25(02):237–250
- 34 Brucker SY, Hahn M, Kraemer D, Taran FA, Isaacson KB, Krämer B. Laparoscopic radiofrequency volumetric thermal ablation of fibroids versus laparoscopic myomectomy. *Int J Gynaecol Obstet* 2014;125(03):261–265
- 35 Hahn M, Brucker S, Kraemer D, et al. Radiofrequency volumetric thermal ablation of fibroids and laparoscopic myomectomy: long-term follow-up from a randomized trial. *Geburtshilfe Frauenheilkd* 2015;75(05):442–449
- 36 Brooks EA, Singer AM, Delvadia DR, et al. The CHOICES Study: facility level comparative cost, resource utilization, and outcomes analysis of myomectomy compared to transcervical fibroid ablation. *Clinicoecon Outcomes Res* 2020;12:299–306
- 37 Cardozo ER, Clark AD, Banks NK, Henne MB, Stegmann BJ, Segars JH. The estimated annual cost of uterine leiomyomata in the United States. *Am J Obstet Gynecol* 2012;206(03):211.e1–211.e9
- 38 Berman JM, Shashoua A, Olson C, Brucker S, Thiel JA, Bhagavath B. Case series of reproductive outcomes after laparoscopic radiofrequency ablation of symptomatic myomas. *J Minim Invasive Gynecol* 2020;27(03):639–645
- 39 Claeys J, Hellendoorn I, Hamerlynck T, Bosteels J, Weyers S. The risk of uterine rupture after myomectomy: a systematic review of the literature and meta-analysis. *Gynecol Surg* 2014;11(03):197–206
- 40 Christoffel L, Bends R, Toub D, et al. Pregnancy outcomes after transcervical radiofrequency ablation of uterine fibroids with the Sonata system. *J Gynecol Surg* 2022;38(03):207–213
- 41 Bongers M, Gupta J, Garza-Leal JG, Brown M, Felberbaum R. The INTEGRITY Trial: preservation of uterine-wall integrity 12 months after transcervical fibroid ablation with the Sonata system. *J Gynecol Surg* 2019;35(05):299–303
- 42 Bongers M, Quinn SD, Mueller MD, et al. Evaluation of uterine patency following transcervical uterine fibroid ablation with the Sonata system (the OPEN clinical trial). *Eur J Obstet Gynecol Reprod Biol* 2019;242:122–125
- 43 Taskin O, Sadik S, Onoglu A, et al. Role of endometrial suppression on the frequency of intrauterine adhesions after resectoscopic surgery. *J Am Assoc Gynecol Laparosc* 2000;7(03):351–354