



Ipsilateral Uterine Artery Access Through Unilateral Transfemoral Approach Using Simple-Curve Catheter

Anupam Lal¹ Rajesh Vijayvergiya² Manphool Singhal¹

¹Department of Radiodiagnosis and Imaging, Postgraduate Institute of Medical Education and Research, Chandigarh, India

²Department of Cardiology, Postgraduate Institute of Medical Education and Research, Chandigarh, India

Address for correspondence Manphool Singhal, MD, DNB, FICR, FSCCT, FSCMR, Department of Radiodiagnosis and Imaging, Postgraduate Institute of Medical Education and Research, Chandigarh 160012, India (e-mail: drmsinghal@yahoo.com).

Indian J Radiol Imaging 2023;33:543–547.

Abstract

Uterine artery embolization (UAE) is a technique for management of various obstetrical and gynecological problems. Transfemoral approach (TFA) is preferred which can be unilateral or bilateral; however, unilateral puncture is preferred due to lesser chances of puncture-related complications as compared to bilateral puncture. UAE through unilateral TFA is possible with use of reverse loop catheters (Roberts uterine catheter [RUC] or Gandras catheter) to access ipsilateral uterine artery. Other way of cannulating the ipsilateral uterine artery is by maneuvering catheters to form Waltman's loop/Simmon's reverse loop. With advent of RUC, unilateral TFA became standard of care. In the recent past, RUC was retracted from Indian market and its nonavailability had mandated use of either bilateral TFA or use of catheters and techniques used in the past for unilateral TFA. Herein, we describe a technique of doing UAE by unilateral TFA using simple gentle curve catheter (Picard) by making a reverse curve loop.

Keywords

- ▶ uterine artery embolization
- ▶ transfemoral approach
- ▶ 5F-Picard catheter
- ▶ 0.035 curved-tipped hydrophilic guidewire
- ▶ reverse loop

Introduction

Uterine artery embolization (UAE) through unilateral transfemoral approach (TFA) in absence of commercially available reverse loop catheter (Roberts uterine catheter [RUC]) is challenging. We did UAE by unilateral TFA using simple gentle curve catheter (Picard) in 12 patients with 100% technical success and comparable fluoroscopic times. This article describes this technique in details where a reverse curve loop was made to cannulate uterine arteries (UAs).

Technique Description

Step 1: Right transfemoral puncture followed by 5F arterial sheath placement in right common femoral artery. Insertion of 5F-Picard catheter with 0.035 curved-tip hydrophilic

guidewire in abdominal aorta followed by crossing over to opposite common iliac artery (CIA) (▶ **Fig. 1A** and **B**).

Step 2: Placement of guidewire in contralateral superficial femoral artery (SFA) followed by advancement of catheter tip till SFA origin or hip joint level. Removal of guidewire (▶ **Fig. 2**).

Step 3: Insertion of guidewire with *hard end* tip till aortic bifurcation (▶ **Fig. 3A**) and gentle push upwards of both guidewire and catheter (▶ **Fig. 3B**) together till catheter forms “inverted-U loop” in abdominal aorta (▶ **Fig. 3C**). Tip of catheter during this maneuver retracts proximally from contralateral femoral artery to lie within external iliac or CIA (▶ **Fig. 3B**). Now, with this maneuver catheter forms a shape akin to RUC and behaves similarly while maneuvering within the pelvic vessels.

article published online
June 26, 2023

DOI <https://doi.org/10.1055/s-0043-1770086>.
ISSN 0971-3026.

© 2023. Indian Radiological Association. All rights reserved.
This is an open access article published by Thieme under the terms of the Creative Commons Attribution-NonDerivative-NonCommercial-License, permitting copying and reproduction so long as the original work is given appropriate credit. Contents may not be used for commercial purposes, or adapted, remixed, transformed or built upon. (<https://creativecommons.org/licenses/by-nc-nd/4.0/>)
Thieme Medical and Scientific Publishers Pvt. Ltd., A-12, 2nd Floor, Sector 2, Noida-201301 UP, India

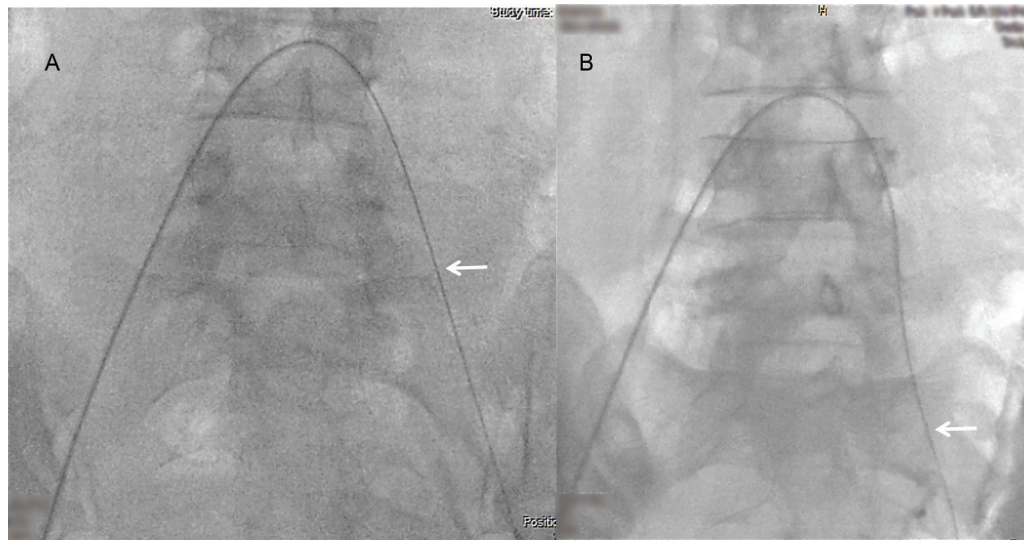


Fig. 1 (A, B) Fluoroscopic image (A) shows 5F-Picard catheter with 0.035 curved-tipped hydrophilic guidewire (arrow) after crossing the aortic bifurcation through 5F arterial sheath placement in the right common femoral artery through right transfemoral puncture. Note 0.035 curved-tipped hydrophilic guidewire in opposite common iliac artery. Fluoroscopic image (B) shows position of catheter-guidewire (arrow) assembly in distal left common iliac artery (CIA).

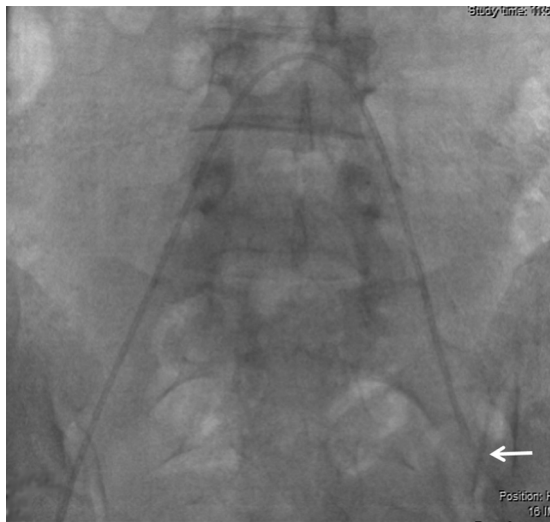

Fig. 2 Fluoroscopic image shows catheter tip at level of origin of left (contralateral) superficial femoral artery (SFA) (arrow). Guidewire is withdrawn after desired position is achieved.

Step 4: Gently pull catheter, to advance catheter tip in contralateral left CIA (► **Fig. 4A**). Catheter tip can then be easily maneuvered into internal iliac artery (IIA) followed by selective cannulation of UA (Fig. 4B). Guidewire can be used as and when desired.

Step 5: After embolization of contralateral UA gently keep pushing catheter till catheter tip lies at aortic bifurcation (► **Fig. 5A**). Now pull catheter with tip directed to same side of femoral puncture (► **Fig. 5B**). Further pulling out catheter will bring its tip down distally into ipsilateral CIA (► **Fig. 5C**). Then, cannulation of IIA and UA (► **Fig. 5D**) can be done easily.

Step 6: Following embolization of ipsilateral UA, push catheter till its tip lies in lower abdominal aorta (► **Fig. 6A**).

Pass guidewire and place again in contralateral SFA (► **Fig. 6B**) and roll over catheter over it and remove the assembly (► **Fig. 6C**).

Discussion

UAE is an established technique for many gynecological and obstetrical problems.¹⁻⁶

Usually preferred approach is TFA which can be unilateral or bilateral with equivalent technical success; however, unilateral TFA puncture is preferred due to lesser chances of puncture-related complications as compared to bilateral puncture.^{7,8}

Previously, UAE, through unilateral TFA was possible with formation of Waltman's loop using a simple curve catheter where reverse loop was made by immersing catheter with reshaping wire in boiling water.⁹ Other techniques used in the past were creation of Simmons' reverse curve (akin to Waltman's loop) using 5F cobra-shaped catheter (Cobra; Terumo, Tokyo, Japan) and hydrophilic polymer-coated 0.032-inch guidewire (Radifocus; Terumo)^{10,11} or using an especially designed catheter with a suture.¹² Few authors have also used 4F Rosch inferior mesenteric catheter (Cordis, Miami, Florida, United States) with acceptable technical success up to 79.2¹³ and 91.8%.¹⁴ In both these series either bilateral TFA or additional hardware (catheters or micro-catheters) were used.^{13,14}

With availability of reverse catheters like Gandras or RUC, UAE by unilateral TFA became popular with RUC being the catheter of choice.^{6,14-16} However, lately RUC had been retracted from markets because of unknown reasons, forcing the interventional radiologists to use bilateral TFA or unilateral TFA with catheters and techniques used in the past.

At our institution we performed UAE through right TFA approach using 5F-Picard angiographic catheter with 100%

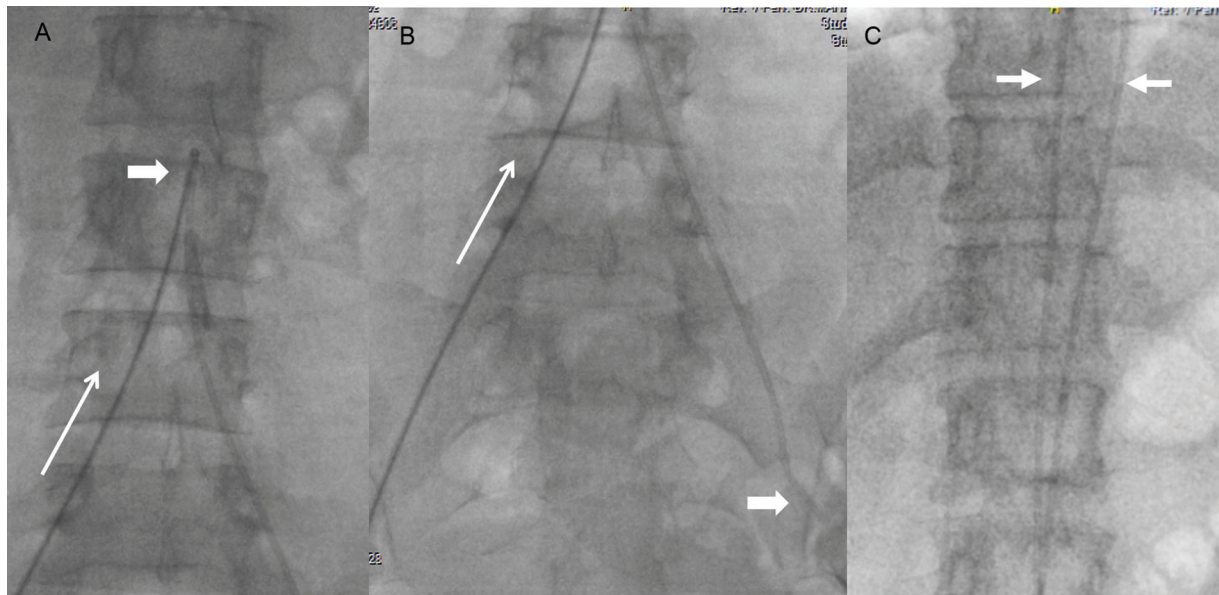


Fig. 3 (A–C) Fluoroscopic image (A–C) show insertion of guidewire with *hard end* till aortic bifurcation (thick arrow in A) and gentle push upwards (thin arrow in A and B) till the catheter forms an “inverted-U loop” in abdominal/lower thoracic aorta (arrows in C). The tip of the catheter during this maneuver will be retracted proximally from the contralateral femoral artery to lie within the contralateral external iliac artery or common iliac artery (thick arrow in B). Now, with this maneuver the catheter forms a loop like Waltman’s loop/Simmons’ reverse curve shape akin to Roberts uterine curve catheter and behaves in a similar fashion.

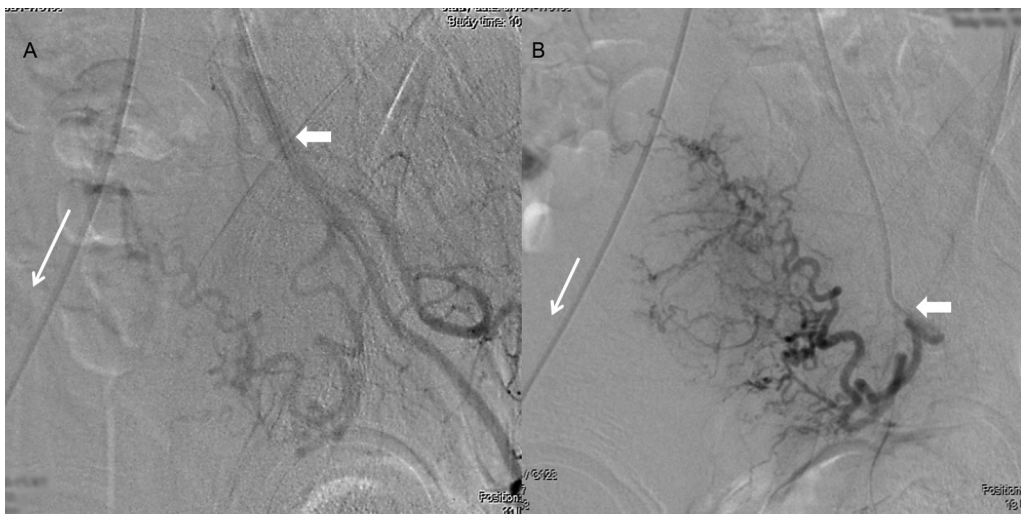

Fig. 4 (A, B) Angiographic images (A and B) show catheter (thick arrow in A) in anterior division of contralateral left internal iliac artery after pulling the catheter (thin long arrow). With further maneuvering (long arrow in B) cannulation of uterine artery can be done (thick arrow in B).

technical success with acceptable procedure (25–50 minutes) and fluoroscopic time (15–25 minutes). The technique is simple and can be performed in any interventional angiographic suite without any requirement of additional hardware. The key point was to make simple catheter a reverse-curve catheter (like Simmons’ reverse loop) akin to RUC that cannulates all desired branches of IIA on both the sides easily. This was achieved by first placing the catheter tip in contralateral SFA and then passing stiff (hard) end of 0.035 hydrophilic

guidewire in proximal ipsilateral CIA near aortic bifurcation and then gently pushing upwards the guidewire with catheter assembly till it forms an inverted loop in abdominal aorta (►Figs. 1–3). Once the catheter forms the desired loop in the abdominal aorta, the guidewire is withdrawn and subsequently the catheter tip can easily be maneuvered to cannulate contralateral IIA and UA using floppy end of the guidewire (►Fig. 4). Once embolization is done on the contralateral side, the catheter is pushed till the tip lies at

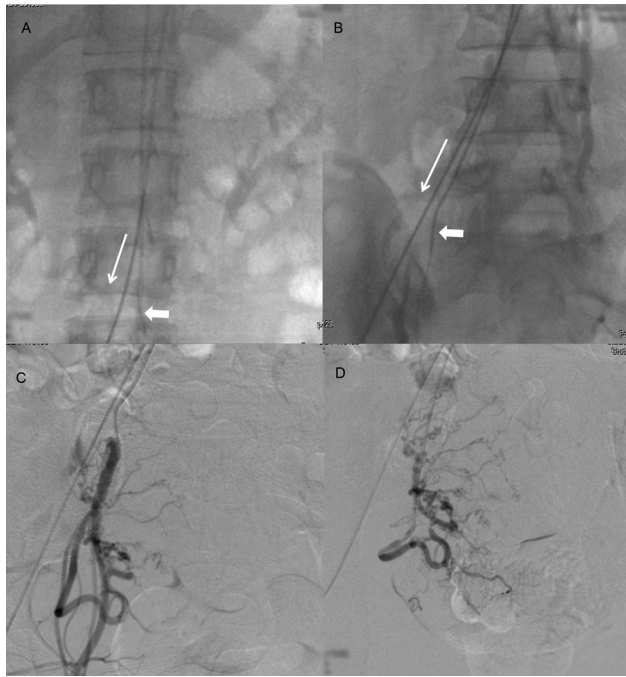


Fig. 5 (A–D) Fluoroscopic images (A and B). After embolization of contralateral uterine artery (left side here) gentle pushing (thin long arrow in A) of the catheter will take the catheter tip to lie at aortic bifurcation (thick arrow in A). After pulling the catheter (thin long arrow in B) with the tip directed to the same side of femoral puncture (right side here) will bring the catheter to the ipsilateral common iliac artery (thick arrow in B). Angiographic images (C and D). Further pulling out the catheter at desired site will bring its tip down distally into the ipsilateral internal iliac artery (C) and ipsilateral uterine artery (D).

aortic bifurcation and then maneuvered so that the tip lies in ipsilateral CIA, gently pulling the catheter and guidewire assemble together (►Fig. 5) places the catheter in IIA and then UA can be cannulated by maneuvering. The technique thus allows selective cannulation of UAs without requirement of additional hardware, further if so desired a microcatheter can be easily passed through the catheter for superselective

cannulation of branches of UAs as the bend that forms is gentle without acute angulations.

Once the embolization is done on both sides the catheter is pushed back in aorta with the tip directed toward contralateral CIA and guidewire passed with floppy end and the catheter passed over it till the loop vanishes and the tip of the catheter lies in SFA. Subsequently, the assembly is withdrawn (►Fig. 6).

A technique similar to our technique has been described in literature by Pelage et al and Costantino et al.^{10,11} Pelage et al¹⁰ cannulated contralateral UA without formation of reverse loop and ipsilateral UA was cannulated with formation of Simmons' reverse loop. Reverse loop was formed by keeping the catheter tip of 5F cobra-shaped catheter (Cobra; Terumo) in contralateral UA and after placement of 0.032-inch hydrophilic polymer-coated guidewire a strong torque was applied to make an inverted loop in aorta and the catheter pulled to cannulate the ipsilateral UA. Costantino et al¹¹ in their article describe cannulation of contralateral UA using microcatheter after placing hydrophilic 5F cobra-shaped catheters (Glidecath; Terumo, Somerset, New Jersey, United States) in IIA; however, the ipsilateral UA was cannulated similar to our technique by forming reverse loop. Our technique vis-à-vis previously described techniques is simpler, safe, and does not require any additional hardware like microcatheters as used by Costantino et al and not associated with any inadvertent complications like arterial injury or dissection which may arise due to strong applied torque (though not reported by Pelage et al). Also, withdrawal of catheter assembly postprocedure by our technique is easy without any chance of knotting of catheter.

Conclusion

Technique described by us for bilateral UA access for UAE by unilateral TFA approach is simple, easy, and cost effective with 100% technical success and does not require any additional hardware. Procedure and fluoroscopic time remain the same as with RUC catheter.

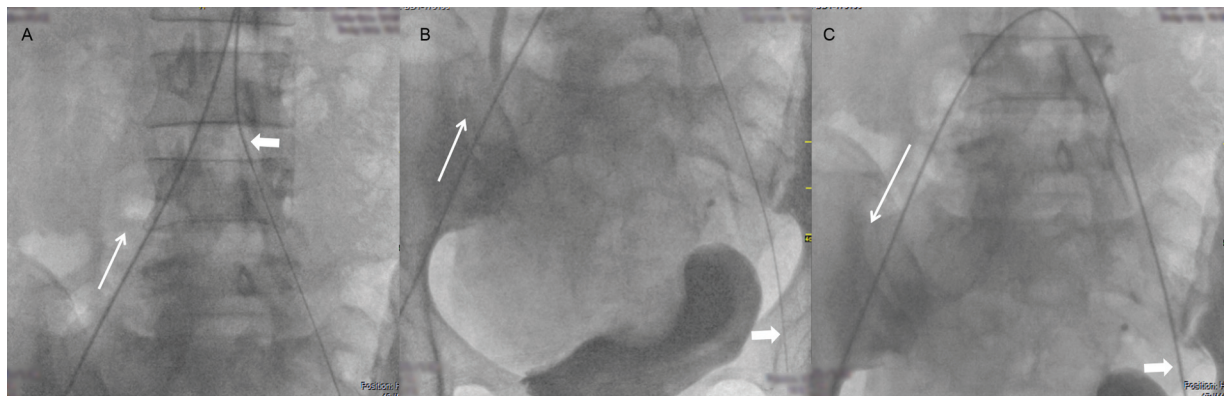


Fig. 6 (A–C) Fluoroscopic images (A–C). After embolization of ipsilateral uterine artery push the catheter (thin long arrows in A) till its tip lies in lower abdominal aorta and tip of catheter directed toward contralateral common iliac artery (thick arrow A). Once that position is achieved pass on the guidewire with floppy end (0.035 curved-tipped hydrophilic guidewire) and place again in contralateral superficial femoral artery (SFA) (thick arrow in B) and roll over catheter over it (thick arrow in C) and pull the assembly (long arrow in C).

Funding

None.

Conflict of Interest

None declared.

References

- 1 Spies JB, Bruno J, Czeyda-Pommersheim F, Magee ST, Ascher SA, Jha RC. Long-term outcome of uterine artery embolization of leiomyomata. *Obstet Gynecol* 2005;106(5 Pt 1):933–939
- 2 Goodwin SC, Spies JB, Worthington-Kirsch R, et al; Fibroid Registry for Outcomes Data (FIBROID) Registry Steering Committee and Core Site Investigators. Uterine artery embolization for treatment of leiomyomata: long-term outcomes from the FIBROID Registry. *Obstet Gynecol* 2008;111(01):22–33
- 3 Gonsalves M, Belli A. The role of interventional radiology in obstetric hemorrhage. *Cardiovasc Intervent Radiol* 2010;33(05):887–895
- 4 Kirby JM, Kachura JR, Rajan DK, et al. Arterial embolization for primary postpartum hemorrhage. *J Vasc Interv Radiol* 2009;20(08):1036–1045
- 5 Soyer P, Dohan A, Dautry R, et al. Transcatheter arterial embolization for postpartum hemorrhage: indications, technique, results, and complications. *Cardiovasc Intervent Radiol* 2015;38(05):1068–1081
- 6 Das CJ, Rathinam D, Manchanda S, Srivastava DN. Endovascular uterine artery intervention. *Indian J Radiol Imaging* 2017;27:488–495
- 7 Worthington-Kirsch R, Spies JB, Myers ER, et al; FIBROID Investigators. The Fibroid Registry for outcomes data (FIBROID) for uterine embolization: short-term outcomes. *Obstet Gynecol* 2005;106(01):52–59
- 8 Gandras EJ. The Gandras catheter for uterine artery embolization: the procedure-driven development of a novel medical device. *Minim Invasive Ther Allied Technol* 2009;18(02):93–97
- 9 Waltman AC, Courey WR, Athanasoulis C, Baum S. Technique for left gastric artery catheterization. *Radiology* 1973;109(03):732–734
- 10 Pelage JP, Soyer P, Le Dref O, et al. Uterine arteries: bilateral catheterization with a single femoral approach and a single 5-F catheter—technical note. *Radiology* 1999;210(02):573–575
- 11 Costantino M, Lee J, McCullough M, Nsouli-Maktabi H, Spies JB. Bilateral versus unilateral femoral access for uterine artery embolization: results of a randomized comparative trial. *J Vasc Interv Radiol* 2010;21(06):829–835, quiz 835
- 12 Shlansky-Goldberg R, Cope C. A new twist on the Waltman loop for uterine artery embolization for fibroid. *J Vasc Interv Radiol* 2001;12:997–1000
- 13 Ho SS, Cowan NC. Uterine artery embolisation for uterine fibroids using a 4F Rosch inferior mesenteric catheter. *Eur Radiol* 2005;15(06):1168–1172
- 14 Kroencke TJ, Kluner C, Hamm B, Gauruder-Burmester A. Use of the 4F Rösch inferior mesenteric catheter in embolization procedures in the pelvis: a review of 300 cases. *Cardiovasc Intervent Radiol* 2007;30(02):268–272
- 15 van Overhagen H, Reekers JA. Uterine artery embolization for symptomatic leiomyomata. *Cardiovasc Intervent Radiol* 2015;38(03):536–542
- 16 Singhal M, Gupta P, Sikka P, Khandelwal N. Uterine artery embolization following internal iliac arteries ligation in a case of postpartum hemorrhage: a technical challenge. *J Obstet Gynaecol India* 2015;65(03):202–205