



Severe Oculorespiratory Reflex during Ophthalmic Artery Catheterization in an Infant with Retinoblastoma

Balaji Vaithialingam¹  Swaroop Gopal² Shishir Chandrashekhar¹

¹Department of Anaesthesiology, Sakra World Hospital, Bengaluru, Karnataka, India

²Department of Neuro-Endovascular Surgery, Sakra World Hospital, Bengaluru, Karnataka, India

Address for correspondence Balaji Vaithialingam, MD, DM, Department of Anesthesia, Sakra World Hospital, Bellandur, Bengaluru 560103, Karnataka, India (e-mail: balamedicine04@gmail.com).

Indian J Radiol Imaging 2023;33:574–575.

Superselective ophthalmic artery injection of the chemotherapeutic agent is a new treatment option for advanced retinoblastoma.¹ We present a case of severe bronchospasm with loss of tidal volume and oxygen desaturation in an infant during ophthalmic artery catheterization under general anesthesia.

A 9-month-old infant (weight 6 kg) presented with haziness of the left eye and was diagnosed as a case of left eye retinoblastoma based on fundoscopic examination. A superselective intra-arterial injection of melphalan was planned in the digital subtraction angiographic suite under general anesthesia. Under sevoflurane inhalation induction, a 24-G intravenous cannula was secured in the left hand, and the trachea was intubated with a 4.5 uncuffed PVC tube after paralysis with 3 mg of intravenous atracurium. Intraoperative anesthesia was maintained with sevoflurane, and analgesia was supplemented with 0.3 mg intravenous morphine. The patient had stable intraoperative hemodynamics (heart rate, 120–140/min and systolic blood pressure, 50–70 mm Hg) and lungs were ventilated in pressure-controlled mode (pressure support = 15 cm H₂O) to achieve a tidal volume of 60 to 70 mL. A 5F introducer sheath was placed in the right femoral artery through the Seldinger technique and 50 U/kg of unfractionated heparin was administered intravenously. A 5F diagnostic catheter (Cobra, GLIDECATH, Terumo International Systems, Japan) was coaxially introduced through the femoral sheath and placed in the left internal carotid artery. Following the proper placement of the diagnostic catheter, a 2.1F (OD) microcatheter (Headway Duo, MicroVention, United States) was navigated and stationed in the ostia of the left ophthalmic artery (► Fig. 1). A sudden total disappearance of the end-tidal carbon dioxide (EtCO₂) waveform with complete loss of tidal volume was

noted at a set pressure of 15 cm H₂O in the pressure-controlled ventilation mode immediately following ophthalmic artery catheterization with mild bradycardia (85 beats per minute). The peripheral oxygen saturation dropped to 85%, and the breathing system check revealed no leaks or disconnections. Immediate hand ventilation with 100% oxygen at 8 L/min was performed, and a tight bag was observed, indicating decreased lung compliance. Auscultation revealed minimal bilateral air entry, and tracheal suction with a catheter revealed no obstruction. The possibility of an anaphylactic reaction was ruled out because there was no skin rash or hemodynamic instability. Because the onset of an adverse respiratory event coincided with the placement of the ophthalmic artery catheter, the possibility of an oculorespiratory reflex was considered, and the operator was notified immediately. The operator avoided further catheter manipulation for 2 minutes with the catheter in the ophthalmic artery. Intravenous propofol (5 mg) was administered to relieve the severe bronchospasm. After 2 minutes, the bag compliance improved to 100% with the appearance of the EtCO₂ waveform on hand ventilation. Intravenous hydrocortisone (10 mg) was administered, and the patient was ventilated in the pressure-controlled mode without further complications. The trachea was successfully extubated after a successful ophthalmic artery injection of the chemotherapeutic agent.

The development of an oculorespiratory reflex during superselective catheterization of the ophthalmic artery can be fatal. The onset of the reflex is usually abrupt and always coincides with the catheterization of the ophthalmic artery.² The dural covering around the ophthalmic artery is densely innervated by trigeminal nerve endings, and a sudden stretch or dilatation of the ophthalmic artery can initiate

article published online
June 26, 2023

DOI <https://doi.org/10.1055/s-0043-1770084>.
ISSN 0971-3026.

© 2023. Indian Radiological Association. All rights reserved.

This is an open access article published by Thieme under the terms of the Creative Commons Attribution-NonDerivative-NonCommercial-License, permitting copying and reproduction so long as the original work is given appropriate credit. Contents may not be used for commercial purposes, or adapted, remixed, transformed or built upon. (<https://creativecommons.org/licenses/by-nc-nd/4.0/>)

Thieme Medical and Scientific Publishers Pvt. Ltd., A-12, 2nd Floor, Sector 2, Noida-201301 UP, India

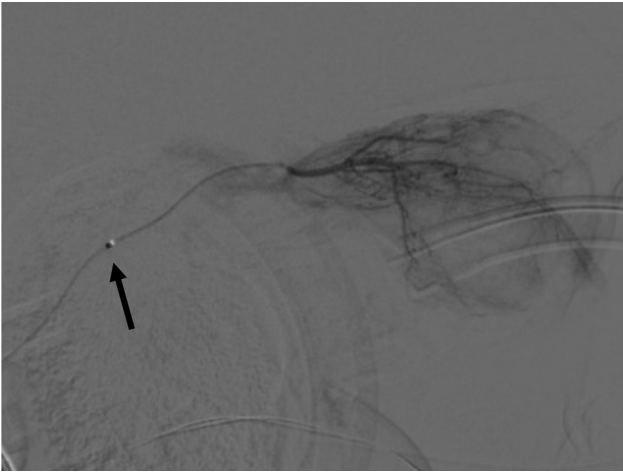


Fig. 1 Digital subtraction angiographic image showing microcatheter in the left ophthalmic artery ostia (arrow).

cardiorespiratory reflexes. A sudden change in pulmonary compliance can occur in 29% of cases during ophthalmic artery catheterization.³ The oculorespiratory reflex can be an atypical form of bronchospasm with no wheeze and manifests as a sudden drop in tidal volume. It is prudent to notify the operator to withdraw the ophthalmic artery catheter or avoid any catheter manipulation during the event. Intravenous adrenaline (0.5–1 mcg/kg) can reverse severe bronchospasm in the oculorespiratory reflex. Pressure-controlled ventilation can prevent a sudden increase in peak airway pressure and detect small drops in tidal volume.

To conclude, anesthesiologists and neuroradiologists should be aware of the oculorespiratory reflex during super-

selective ophthalmic artery catheterization, which manifests as a sudden drop in tidal volume and an decrease in lung compliance.

Note

The authors affirm that human research participants (parents) provided consent for the publication.

Author Contributions

B.V. contributed with design, conceptualization, medical writing, and initial draft. S.G. and S.C. performed manuscript review and editing.

Funding

None.

Conflict of Interest

None declared.

References

- 1 Shields CL, Dockery PW, Yaghy A, et al. Intra-arterial chemotherapy for retinoblastoma in 341 consecutive eyes (1,292 infusions): comparative analysis of outcomes based on patient age, race, and sex. *J AAPOS* 2021;25(03):150.e1–150.e9
- 2 Phillips TJ, McGuirk SP, Chahal HK, et al. Autonomic cardiorespiratory reflex reactions and superselective ophthalmic arterial chemotherapy for retinoblastoma. *Paediatr Anaesth* 2013;23(10):940–945
- 3 Kato MA, Green N, O'Connell K, et al. A retrospective analysis of severe intraoperative respiratory compliance changes during ophthalmic arterial chemosurgery for retinoblastoma. *Paediatr Anaesth* 2015;25(06):595–602