



Traumatic Acute Vertex Epidural Hematoma (vEDH): A Case Report

Lamkordor Tyngkan¹ Memida Laloo² Mebanshanbor Garod Pasi¹

¹Department of Neurosurgery, Bethany Hospital Shillong, Nongrim Hills, Shillong, Meghalaya, India

²Department of Neurosurgery, North Eastern Indira Gandhi Regional Institute of Health and Medical Science (NEIGRIHMS), Shillong, Meghalaya, India

Address for correspondence Lamkordor Tyngkan, MBBS, MS, MCh, Bethany Hospital Shillong, Nongrim Hills, Shillong, Meghalaya, 793003, India (e-mail: lamkordor_tyngkan@yahoo.com).

Indian J Neurotrauma

Abstract

Keywords

- ▶ craniotomy
- ▶ epidural hematoma
- ▶ fall
- ▶ hemostasis
- ▶ vertex

Vertex epidural hematoma (vEDH) is a rare type of intracranial hematoma, which accounts for 0.024% of all head injuries and 0.47 to 8.2% of intracranial hematoma, with high mortality rate of approximately 50% if not detected early. We report a case of 30-year-old male with fall from height presenting with headache and bradycardia. Craniotomy with complete evacuation of vEDH was done. vEDH is a relatively rare entity and in suspected case of vEDH one should always get thin cuts of computed tomography along with sagittal and coronal cuts.

Introduction

Vertex epidural hematoma (vEDH) is a rare type of intracranial hematoma, which accounts for 0.024% of all head injuries and 0.47 to 8.2% of intracranial hematoma, with high mortality rate of approximately 50% if not detected early.^{1,2} It is commonly caused by linear crossing skull fracture over the sinus caused by direct insult to the vertex or diastasis of the sagittal suture. Other possible cause is tear of superior sagittal sinus (SSS), post-surgery.^{1,2} vEDH can be presented with nonspecific symptoms or signs, acute or chronic presentation.^{1,3} vEDH radiological features and diagnosis are challenging because of its higher location that can be missed if radiologist takes a large cuts and also because of its similarity in density to the surrounding bone.¹ So, thin-slice cuts of computed tomography (CT) brain with coronal and sagittal cuts reconstructions were advised or even requesting magnetic resonance imaging (MRI) brain.

Case Report

We reported a case of 30-year-old male who presented to emergency room with alleged history of fall from height

(second floor of a construction building) while working. He presented with complaint of loss of consciousness for 3 minutes, headache, and vomiting. On examination, his Glasgow coma scale was E4V5M6, pupil's bilateral equal size reacting to light and bradycardia. Noncontrast computed tomography (NCCT) head was done suggestive of fracture over the vault of skull along with diastasis of sagittal suture and there is bilateral vertex acute EDH with extension into bifrontal region with mass effect (▶ **Figs. 1** and **2**). Patient underwent bilateral parasagittal frontoparietal craniotomy and a strip of bone along sagittal suture is left intact (▶ **Fig. 3**) with evacuation of hematoma. Intraoperatively, there is linear fracture crossing sagittal suture along with diastasis of sagittal suture and oozing of blood from veins draining into SSS that was controlled by hemostatic agent (gelatin foam) and dural hitch stitches. Postoperative period was uneventful and postoperative NCCT head was done suggestive of complete evacuation of EDH (▶ **Fig. 4**).

Discussion

vEDH is a relatively uncommon entity that accounts for 0.47 to 8.2% of intracranial hematoma, with high mortality rate of

DOI <https://doi.org/10.1055/s-0043-1769799>.
ISSN 0973-0508.

© 2023. The Author(s).

This is an open access article published by Thieme under the terms of the Creative Commons Attribution License, permitting unrestricted use, distribution, and reproduction so long as the original work is properly cited. (<https://creativecommons.org/licenses/by/4.0/>)

Thieme Medical and Scientific Publishers Pvt. Ltd., A-12, 2nd Floor, Sector 2, Noida-201301 UP, India

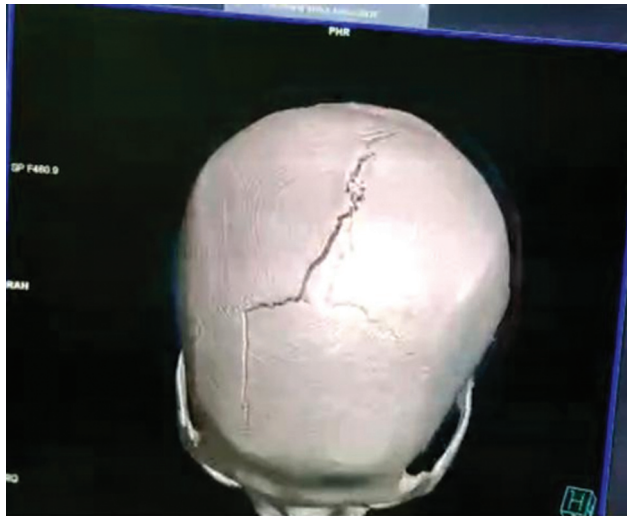


Fig. 1 Computed tomography head showing fracture over vault of skull along with diastasis of sagittal suture.

approximately 50% if not detected early.^{1,2} vEDHs are EDH occurring in the quadrangular area of the skull, bounded anteriorly by bregma and coronal sutures, posteriorly by lambda and lambdoid suture, and laterally by the parietal eminence.⁴ It is commonly caused by linear crossing skull fracture over the sinus caused by direct insult to the vertex or diastasis of the sagittal suture. Other possible cause is tear of SSS, post-surgery.^{1,2} In our case, source of bleeding is from draining veins into SSS as no dural tear was seen over the SSS.

vEDH usually has nonspecific features, hence making it difficult to localize clinically. vEDH may have acute or chronic presentation; headache and vomiting are the most common symptoms. Paraplegia and hemiparesis can also be seen owing to compression of motor homunculus where upper limbs and lower limbs lie in close proximity.⁵ Our case




Fig. 3 Postoperative computed tomography showing bilateral parasagittal craniotomy with drain in situ.

presents with headache and bradycardia most likely due to increase in intracranial pressure.^{1,3}

vEDH can be difficult to diagnose in CT especially if CT is taken in large cuts and no sagittal or coronal cuts is taken. In axial cuts, vEDH can be seen as vague hyperdense area in highest cuts. Therefore, thin CT cuts, sagittal and coronal cuts should be taken in a suspected case of vEDH. MRI scans are very useful in diagnosing vEDH, due to multiplanar capability and lack of bone artifacts. However, the MRI is not used routinely because of the longer time taken and higher cost.^{2,5} In our case, CT was done that showed fracture line over the vault of skull, diastasis of sagittal sinus, and vague hyperdense area in axial cuts of CT in highest locations.

Management of vEDH varies from case to case. It depends upon location of hematoma, size of hematoma, clinical presentation of patient, and rapidity of evolving of vEDH.

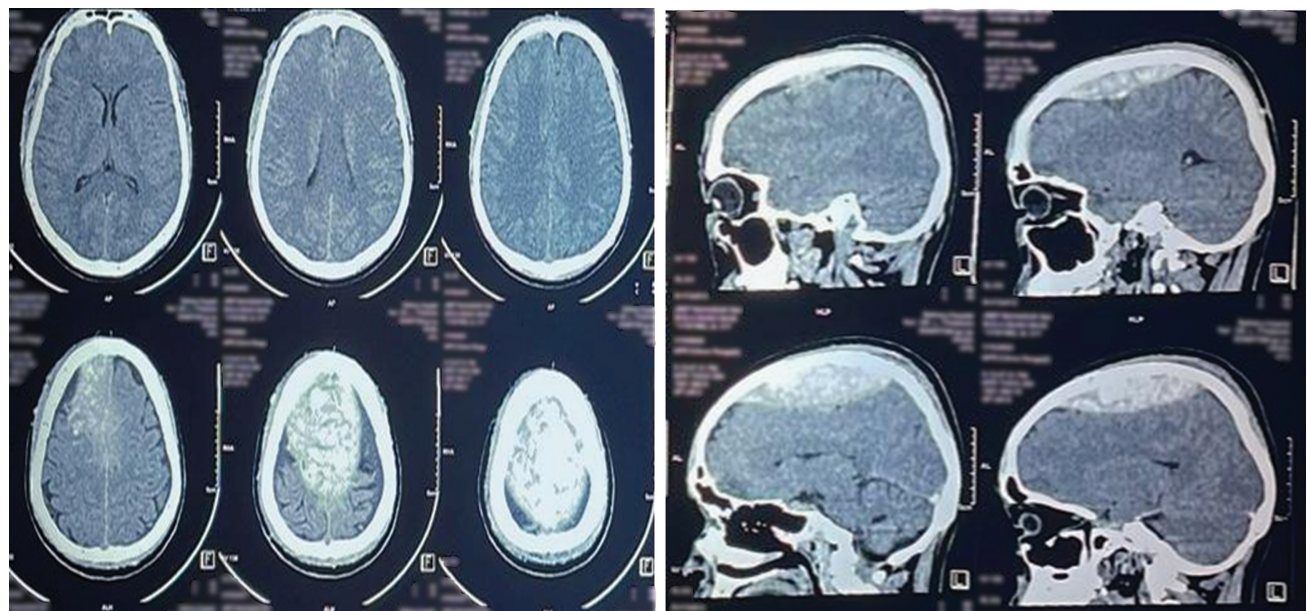


Fig. 2 Computed tomography head (axial and sagittal cuts) showing vertex epidural hematoma.

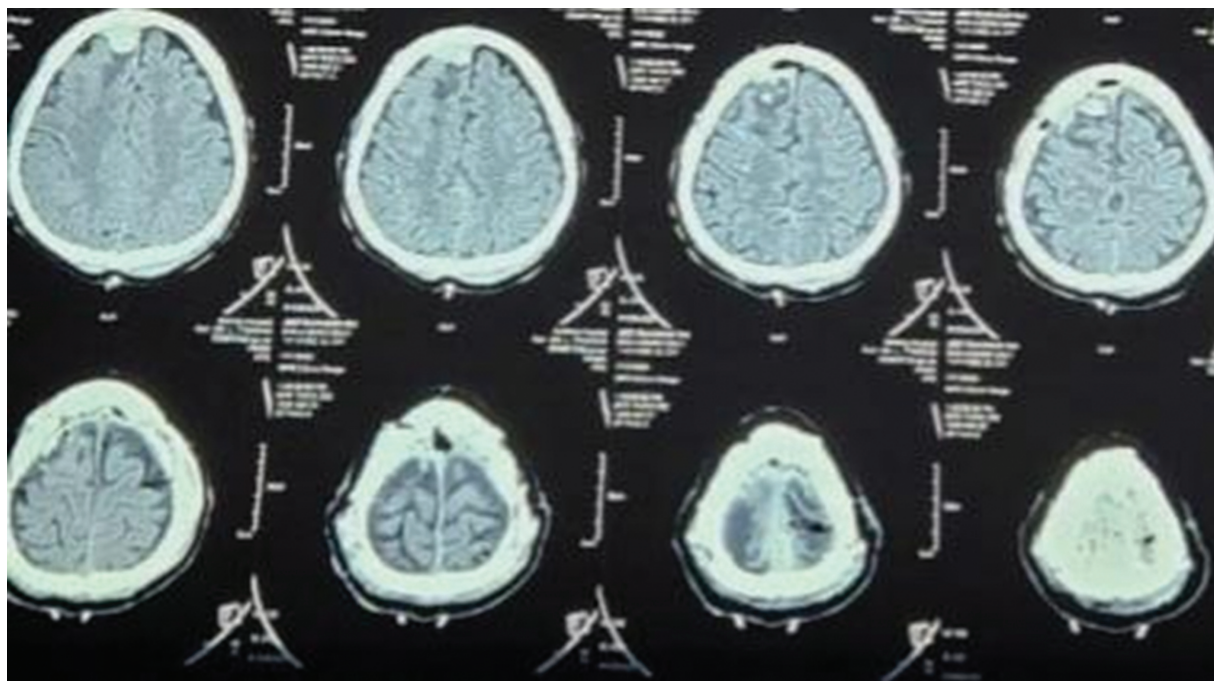


Fig. 4 Postoperative computed tomography showing complete evacuation of vertex epidural hematoma.

Small hematomas can be managed conservatively. Broadly, the indications for surgery in the case of vEDH are deteriorating consciousness, features of severely increased intracranial pressure, features of focal neurological deficit, and hematoma measuring more than 30 mL in volume.⁶ Surgical management consists of craniotomy with complete hematoma evacuation with hemostasis using hemostat agents like gelatin foam or using dural hitch stitches.

Conclusion

vEDH is a relatively rare entity and in suspected case of vEDH one should always get thin cuts of CT along with sagittal and coronal cuts. When operating on such cases, surgical team should prepare for possibility of massive blood loss and shock.

Conflict of Interest

None declared.

References

- 1 Aji YK, Rasi M, Apriawan T, Bajamal AH. Vertex extradural hematomas: when to operate?: a case report *Indones J Neurosurg* 2018; 2:31-33
- 2 Harbury OL, Provenzale JM, Barboriak DP. Vertex epidural hematomas: imaging findings and diagnostic pitfalls. *Eur J Radiol* 2000;36(03):150-157
- 3 Hun J, Won K, Yoon K, Hyun T, Jong K, Kim H. Clinical features and treatment strategies for vertex epidural hematoma: a systematic review and meta - analysis from individual participant data. *Neurosurg Rev* 2021. Doi: 10.1007/s10143-021-01589-z
- 4 Columella F, Gaist G, Piazza G, Caraffa T. Extradural haematoma at the vertex. *J Neurol Neurosurg Psychiatry* 1968;31(04):315-320
- 5 Messori A, Pauri F, Rychlicki F, Veronesi V, Salvolini U. Acute posttraumatic paraplegia caused by epidural hematoma at the vertex. *AJNR Am J Neuroradiol* 2001;22(09):1748-1749
- 6 Bullock MR, Chesnut R, Ghajar J, et al; Surgical Management of Traumatic Brain Injury Author Group. Surgical management of acute epidural hematomas. *Neurosurgery* 2006;58(3, Suppl): S7-S15, discussion Si-iv