




# Melioidosis Presenting as Splenic Abscess: A Case Report

Pranav S. Kumar<sup>1</sup> Chhagan Lal Birda<sup>2</sup> Yadav Suresh Chand<sup>1</sup> Taruna Yadav<sup>3</sup> Ashish Agarwal<sup>2</sup>

<sup>1</sup>Department of Medicine, All India Institute of Medical Sciences, Jodhpur, Jodhpur, Rajasthan, India

<sup>2</sup>Department of Gastroenterology, All India Institute of Medical Sciences, Jodhpur, Jodhpur, Rajasthan, India

<sup>3</sup>Department of Radiology, All India Institute of Medical Sciences, Jodhpur, Jodhpur, Rajasthan, India

Address for correspondence Ashish Agarwal, MD, DM, FIAE, ESEGH (Gastroenterology, UK), Department of Gastroenterology, All India Institute of Medical Sciences, Jodhpur, Room no. 114, A block, 1st floor, OPD wing, Jodhpur, Rajasthan 342001, India (e-mail: drashu123@gmail.com).

J Gastrointest Infect 2023;13:38–40.

## Abstract

### Keywords

- ▶ tuberculosis
- ▶ diabetes
- ▶ *Burkholderia*
- ▶ melioidosis
- ▶ alcohol abuse
- ▶ splenic abscess
- ▶ mediastinal lymphadenopathy

Melioidosis is an infectious disease caused by Gram-negative bacilli *Burkholderia pseudomallei*. Infection is acquired by direct exposure through broken skin, inhalation, or ingestion of the bacterium. Melioidosis has a wide variety of clinical presentations, ranging from an asymptomatic infection or localized cutaneous manifestations at the site of the entry, deep-seated abscess, to multiple organ involvement with sepsis leading to death. Although not uncommon, there is a lack of awareness of its variable presentation leading to a delay in the diagnosis and thus treatment. The diagnosis of melioidosis rests on the culture of the organism from biological samples. Presentation as a splenic abscess is rather rare and a high index of suspicion is needed for the diagnosis. In this article, we report an interesting case of recurrent splenic abscess which was eventually diagnosed to be due to melioidosis.

## Introduction

Melioidosis has been aptly called the “great mimicker” owing to the nonspecific signs and symptoms and a wide variety of presentations. The diagnosis requires awareness of the presentation and high index of suspicion and is established by the growth of the organism on a culture of biological samples.

## Case Report

Our patient was a 37-year-old gentleman with uncontrolled diabetes and with a history of alcohol abuse, who presented with chief complaints of high-grade fever with chills and pain in the abdomen for 3 days. The pain was in the left hypochondrium, continuous, sharpshooting in character, and

severe in intensity with an increase in intensity with deep inspiration and coughing and radiation to the left shoulder. He had a history of similar complaints four times in the last year when he was treated with empirical intravenous and oral antibiotics. A contrast-enhanced computerized tomography (CECT) of the abdomen done 6 months back had revealed a ruptured splenic abscess and an ultrasound-guided aspiration had revealed only features of reactive inflammation and patient was treated empirically with broad-spectrum antibiotics. He also had a history of fever, nonproductive cough, and weight loss 2 years back during the evaluation of which a CECT of the thorax had revealed enlarged mediastinal lymph nodes for which patient was treated empirically with anti-tuberculous therapy (ATT) with improvement in the symptoms.

received  
February 7, 2023  
revised  
March 2, 2023  
accepted  
March 19, 2023

DOI <https://doi.org/10.1055/s-0043-1768939>.  
ISSN 2277-5862.

© 2023. Gastrointestinal Infection Society of India. All rights reserved.

This is an open access article published by Thieme under the terms of the Creative Commons Attribution-NonDerivative-NonCommercial-License, permitting copying and reproduction so long as the original work is given appropriate credit. Contents may not be used for commercial purposes, or adapted, remixed, transformed or built upon. (<https://creativecommons.org/licenses/by-nc-nd/4.0/>)

Thieme Medical and Scientific Publishers Pvt. Ltd., A-12, 2nd Floor, Sector 2, Noida-201301 UP, India

Blood investigations were notable for an elevated erythrocyte sedimentation rate (56 mm/h) and hemoglobin A1c (10.4%). CECT abdomen was done which revealed a peripherally enhancing fluid collection in gastrosplenic ligament and splenic hilum with multiple small hypodense splenic lesions with a small subcapsular splenic lesion (→ Fig. 1). A review of the upper abdominal sections of the CECT chest done 2 years back, revealed few small hypoechoic lesions with enhancement in the spleen, which were initially ascribed to tuberculosis. A fine-needle aspiration cytology retrieved pus which showed a growth of *Burkholderia pseudomallei* on culture with negative Ziehl–Neelsen stain for acid-fast bacillus and tuberculosis polymerase chain reaction. The patient was treated with intravenous ceftazidime sixth hourly for 2 weeks followed by trimethoprim-sulfamethoxazole (TMP-SMX) (320 mg/1600 mg twice daily) orally for 3 months as maintenance therapy. Currently, the patient is asymptomatic with a repeat imaging showing significant resolution of the splenic hilar collection and perfusion changes in the spleen (→ Fig. 1).

## Discussion

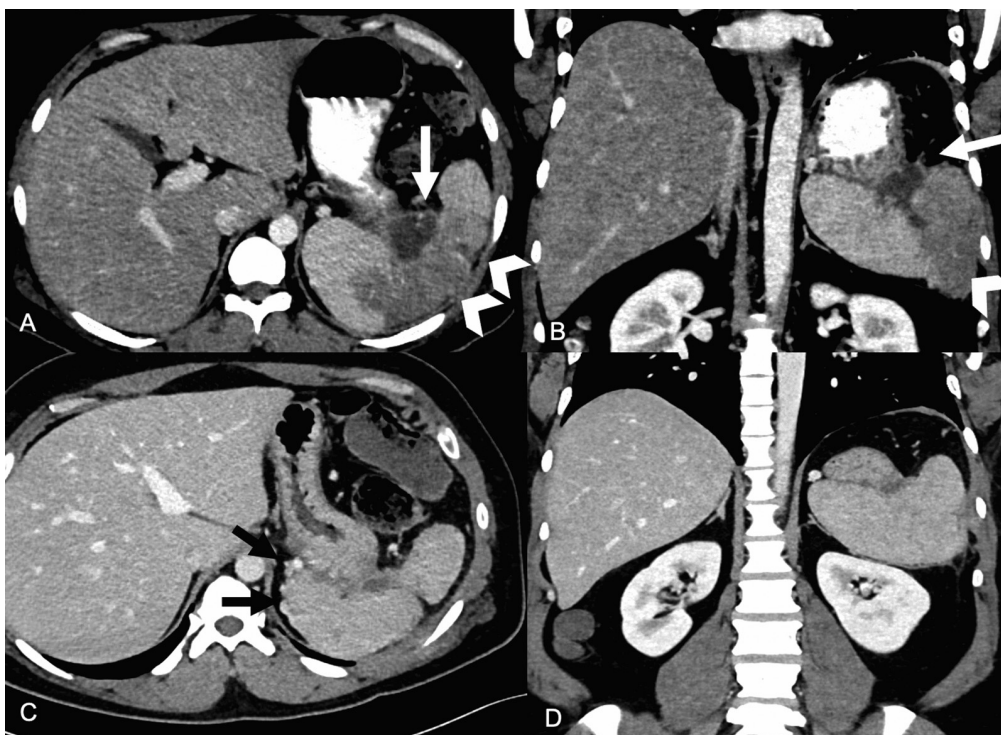Melioidosis is an emerging infectious disease resulting from infection with a Gram-negative bacterium *B. pseudomallei*.<sup>1</sup> Although the likely incidence of the infection is 165,000 cases per year, only 1,300 cases per year have been reported since 2010, which is just 1% of the expected incidence.<sup>2</sup>

This highlights the lack of awareness and difficulty in the diagnosis of melioidosis.

The bacterium *B. pseudomallei* is a common organism found in the superficial layer of the soil and surface groundwater. Infection is acquired by direct exposure through broken skin, inhalation, or ingestion of the bacterium. Risk factors for melioidosis include age > 45 years, immunosuppression, diabetes mellitus, excessive alcohol consumption, chronic lung and kidney disease, and thalassemia. Our patient had uncontrolled diabetes with a history of excessive alcohol consumption, thus conferring an increased risk.

Presentation can be either acute (85% cases) with sepsis with or without pneumonia or localized abscess, or chronic (15–20%) where the symptoms persist for more than 2 months. A high proportion (5–28%) of patients develop a recurrent infection that could result from recrudescence of the original strain due to incomplete clearance. A small percentage of patients develop a latent infection with reactivation and symptoms after many years of exposure.<sup>3</sup>

The diagnosis rests on the culture of the organism from blood, throat, or rectal swabs or the aspirated pus in cases with localized abscess. As cultures have a low sensitivity for diagnosis, repeated culture is necessary for patients with suspected melioidosis. The treatment of melioidosis rests on an early diagnosis and timely starting of antimicrobials specific for *B. pseudomallei*. Antimicrobial therapy consists



**Fig. 1** Contrast-enhanced computerized tomography (CT) images in portal venous phase. (A) Axial and (B) coronal images at first presentation show a peripherally enhancing fluid collection (white arrows) in gastrosplenic ligament and splenic hilum. Splenic vein thrombosis with perfusion changes and hypodense areas (arrowheads) were present in the spleen. After percutaneous aspiration and 3 months of medical treatment, (C) axial and (D) coronal images show significant resolution of the splenic hilar collection and perfusion changes in the spleen. Venous collaterals (black arrows) are noted in perisplenic region.

of an initial intensive phase followed by a prolonged maintenance/eradication phase. Intravenous meropenem/ceftazidime is the drug of first choice for the intensive phase, which should be given for a minimum of 2 weeks. TMP-SMX is the preferred agent for the maintenance therapy and should be given for at least 3 months after the end of the intensive phase. In patients with TMP-SMX intolerance or toxicity, doxycycline can be used as an alternative agent for maintenance therapy. Although recrudescence with a relapse of symptoms is still common after adequate therapy, the risk is decreased to almost half (< 5%).<sup>4</sup>

Our patient possibly had melioidosis to begin with, 2 years back. The delay in the diagnosis was due to a lack of awareness and inadequate sampling. ATT and multiple courses of antibiotics lead to a latent infection with repeated recrudescence and relapse of symptoms.<sup>5</sup> Thus, it is suggested that diagnosis of melioidosis should always be considered in patients with risk factors presenting with fever, especially in patients with deep-seated abscesses.

To conclude, although not so uncommon, melioidosis is a neglected and grossly underdiagnosed infectious disease. An increased awareness of the risk factors and clinical presentation leading to an early diagnosis coupled with a prolonged course of targeted antibiotics are sine qua non for adequate management of the disease.

#### Ethical Statement

As only anonymized data are being reported, ethical clearance was waived off by the ethics committee. A written and informed consent for publication was taken from the patient before submission of the case report.

#### Authors' Contribution

Conception and design of the study: A.A., C.L.B.  
 Generation, collection, assembly, analysis, and/or interpretation of data: P.K., S.Y., T.Y.  
 Drafting or revision of the manuscript: P.K., S.Y., C.L.B., A.A.  
 Critical revision of the article for important intellectual content: C.L.B., A.A., T.Y.  
 Approval of the final version of the manuscript: All the authors approved the final manuscript.  
 Guarantor of article: A.A.

#### Data Availability Statement

There is no data associated with this work.

#### Conflict of Interest

None declared.

#### References

- 1 Willcocks SJ, Denman CC, Atkins HS, Wren BW. Intracellular replication of the well-armed pathogen *Burkholderia pseudomallei*. *Curr Opin Microbiol* 2016;29:94–103
- 2 Limmathurotsakul D, Golding N, Dance DAB, et al. Predicted global distribution of *Burkholderia pseudomallei* and burden of melioidosis. *Nat Microbiol* 2016;1:15008
- 3 Yee KC, Lee MK, Chua CT, Puthuchear SD. Melioidosis, the great mimicker: a report of 10 cases from Malaysia. *J Trop Med Hyg* 1988;91(05):249–254
- 4 Lipsitz R, Garges S, Aurigemma R, et al. Workshop on treatment of and postexposure prophylaxis for *Burkholderia pseudomallei* and *B. mallei* infection, 2010. *Emerg Infect Dis* 2012;18(12):e2
- 5 Ross BN, Myers JN, Muruato LA, Tapia D, Torres AG. Evaluating new compounds to treat *Burkholderia pseudomallei* infections. *Front Cell Infect Microbiol* 2018;8:210