




# Clinical Results of Nonvascularized Metatarsal Articular Bone Grafting for Osteochondral Defects of the Radiocarpal and Distal Radioulnar Joint

Shirley D. Stougie, BHS<sup>1</sup>  Peter Hoogvliet, MD, PhD<sup>1</sup> Lara Plugge, MSc<sup>1</sup> J. Henk Coert, MD, PhD<sup>1</sup>

<sup>1</sup> Department of Plastic, Reconstructive and Hand Surgery, University Medical Centre Utrecht, Utrecht, The Netherlands

Address for correspondence Shirley D. Stougie, BHS, Department of Plastic, Reconstructive and Hand Surgery, University Medical Centre Utrecht, Utrecht, The Netherlands  
(e-mail: s.d.stougie@umcutrecht.nl).

J Wrist Surg 2024;13:127–136.

## Abstract

**Background** Treatment of post-traumatic osteochondral defects in the radiocarpal and distal radioulnar joint with nonvascularized metatarsal articular bone grafting is an option to restore the joint (cartilage) surface and wrist function.

**Purpose** To evaluate the clinical midterm results of 10 consecutive patients who were treated with a nonvascularized metatarsal bone graft for cartilage bone defects of the lunate facet, scaphoid facet, sigmoid notch, or the radial part of the ulnar head.

**Patients and Methods** Patients with isolated osteochondral defects of the lunate facet, scaphoid facet, sigmoid notch, or radial part of the ulnar head, respectively, as a result of wrist trauma were retrospectively identified in a prospectively collected database. The patients symptoms were limited wrist motion and/or pain. Clinical results and complications were extracted from patient's medical files and two questionnaires consisting of the Patient-Rated Wrist Evaluation and additional questions regarding patient satisfaction and return to work and/or hobby.

**Results** Minor complications occurred in three cases and required surgery. In five cases an acceptable donor site foot morbidity was seen at 1 year. One patient was not satisfied due to persistent wrist pain despite adequate range of motion. One patient could not return to its prior work. Another patient could not resume its hobby.

**Conclusion** Retrospective evaluation of 10 cases with resurfacing of the scaphoid facet, sigmoid notch, and/or lunate facet, or radial part of the ulnar head has shown that osseointegration was possible without a vascular pedicle to the graft in all cases with a (mean) follow-up of 5 years. This technique may become an alternative treatment when implants become less available.

**Level of Evidence** Level III

## Keywords

- ▶ nonvascularized
- ▶ bone graft
- ▶ metatarsal

Symptomatic osteoarthritis of the wrist and limited wrist motion can hinder daily living activities<sup>1</sup> and is often initially seen by hand therapists for nonoperative management. Surgery is indicated for patients with insufficient pain relief

despite splints and adaptation of activities of daily living. Surgical techniques generally consist of joint replacement or fusion.<sup>2</sup> Both treatments aim to reduce pain, whereas joint replacement also intends to preserve joint motion. The

received

January 19, 2023

accepted

April 3, 2023

article published online

May 2, 2023

DOI <https://doi.org/10.1055/s-0043-1768923>.

ISSN 2163-3916.

© 2023. The Author(s).

This is an open access article published by Thieme under the terms of the Creative Commons Attribution-NonDerivative-NonCommercial-License, permitting copying and reproduction so long as the original work is given appropriate credit. Contents may not be used for commercial purposes, or adapted, remixed, transformed or built upon. (<https://creativecommons.org/licenses/by-nc-nd/4.0/>)

Thieme Medical Publishers, Inc., 333 Seventh Avenue, 18th Floor, New York, NY 10001, USA

disadvantages of these techniques are implant failure and decreased range of motion, respectively.<sup>3</sup> When implants become less available, an alternative, less known, and applied technique could be the use of vascularized or nonvascularized articular bone grafting to restore the joint cartilage surface and also function. Only a few studies describe the application of this type of bone grafts with promising short- to midterm results.<sup>4–7</sup> This paper evaluates the clinical midterm results of 10 consecutive patients who were treated with a nonvascularized metatarsal bone graft for cartilage bone defects of the distal radius or distal ulna. In this study three patients of the series of Goon et al<sup>7</sup> were included and evaluated at a longer follow-up time.

## Methods

### Study Design

Patients with painful post-traumatic osteoarthritis of the radiocarpal or distal radioulnar joint and limited wrist motion, who were treated with nonvascularized metatarsal articular bone grafts to resurface the lunate facet, scaphoid facet, sigmoid notch, or the radial part of the ulna head, were retrospectively identified in a prospectively collected database. A letter of notification was sent to the patients for the upcoming survey, and they were asked for written informed consent.

After written informed consent was obtained the patients completed the Dutch Language Version of the Patient-Rated Wrist Evaluation (PRWE) questionnaire.<sup>8</sup> The PRWE questionnaire measures pain and function of the operated hand (0 points is no pain and not limited in function, 100 points is a lot of pain and very limited in function). Patient satisfaction was determined on a 5-point scale with 1 indicating very unsatisfied and 5 very satisfied. Patient satisfaction was determined by asking whether they would recommend the procedure to family and/or friends and if they would choose

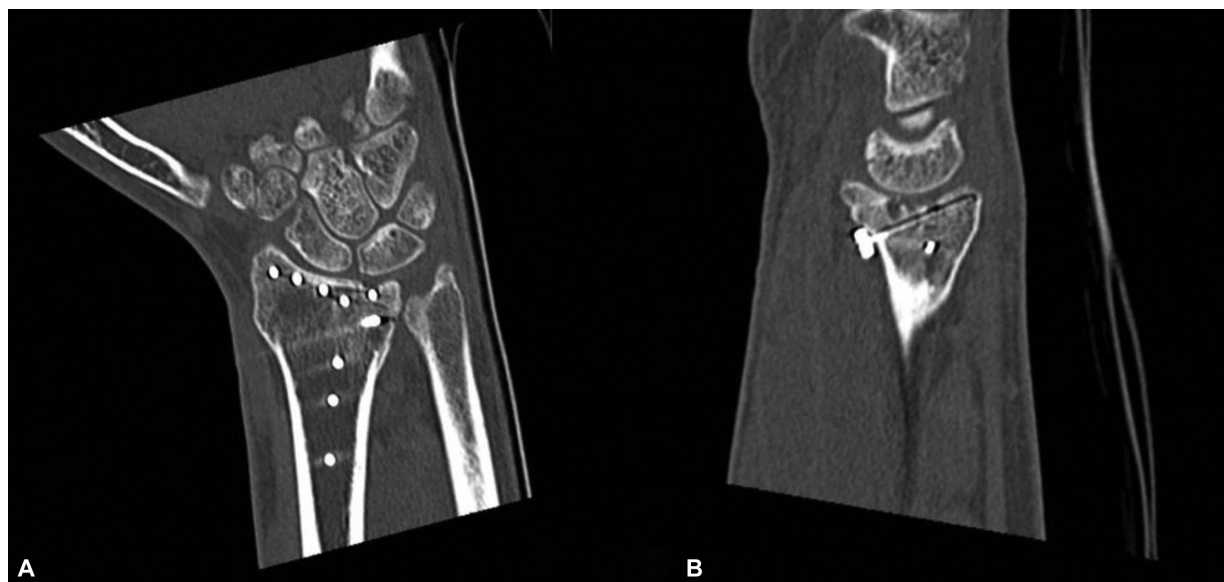
for the same procedure when in the same circumstances. Besides the following surgical characteristics, previous operations, indication, reconstruction + additional procedures, cartilage status, graft fixation, complications, and reoperations, the following medical data were extracted from the patient's medical files, gender, age, follow-up time, wrist range of motion, grip strength, visual analogue scale (VAS) score for pain, PRWE, patient satisfaction, return to work and/or hobby, hand dominance, affected hand, and mean time between injury and reconstruction. This study was approved by the local ethics committee.

### Preoperative Assessment

X-rays and computed tomography (CT) scans determined the extent of the loss of articular cartilage (►Fig. 1). Patients with isolated osteochondral defects of the lunate facet or lunate facet and sigmoid notch or scaphoid facet were included. A contraindication for this procedure is substantial loss of articular cartilage of both facets and defective joint cartilage of the carpal bones as described in detailed by Del Piñal et al.<sup>9</sup>

### Surgical Technique and Postoperative Treatment

All operations were performed by the senior author (J.H.C.) with an experience level V according to Nakamura.<sup>10</sup> Surgical characteristics are described in ►Table 1. The surgical procedure was performed as described in detailed by Goon et al<sup>7</sup> and differed slightly from the surgical technique as described in detailed by Del Piñal et al.<sup>9</sup> As reported in the cadaveric study of Del Piñal et al,<sup>9</sup> the base of the third and fourth metatarsal were due to its slightly concave shape and size (19-mm length dorsoplantar, dorsal width 12 mm, and plantar width 8 mm) chosen as a proper articular bone graft for reconstruction of the lunate facet or scaphoid facet, rather than a costal cartilage graft or autologous proximal tibiofibular joint graft. Since the concavity of a costal cartilage



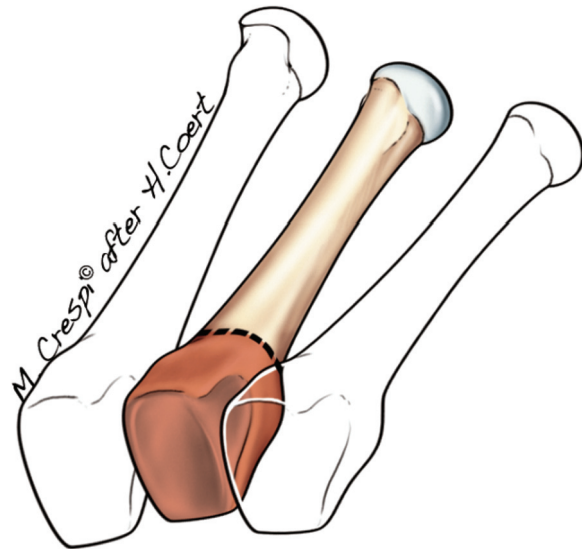
**Fig. 1** (A) Preoperative computed tomography (CT) scan of an osteochondral defect of the lunate facet in case 1. (B) Lateral CT scan of an osteochondral defect of the lunate facet in case 1.

graft is larger than the base of the third and fourth metatarsal and the size of a proximal tibiofibular joint is relatively large for reconstruction of small defects. Reconstruction of both facets is not possible due to its size limitation.<sup>9</sup> The reason J. H.C. harvested nonvascularized rather than vascularized bone grafts was twofold: the arterial network has a wide variable anatomy and the fragile periosteal vessels may easily tear during dissection. In this procedure microsurgical dissection and anastomosis is not necessarily due to the quality of the cancellous bone of the distal radius and its blood supply, resulting in less operating time, an easier inset, and less bulky graft.

Postoperative regime consisted of 1 week of casting. Hand therapy started after 7 days with early active mobilization of the wrist and tendon gliding exercises assisted with a removable splint for 5 weeks. This is in contrast with the 3, 4, and 5 weeks of immobilization by Mehin et al,<sup>4</sup> Obert et al,<sup>6</sup> and Del Piñal et al,<sup>5</sup> respectively.

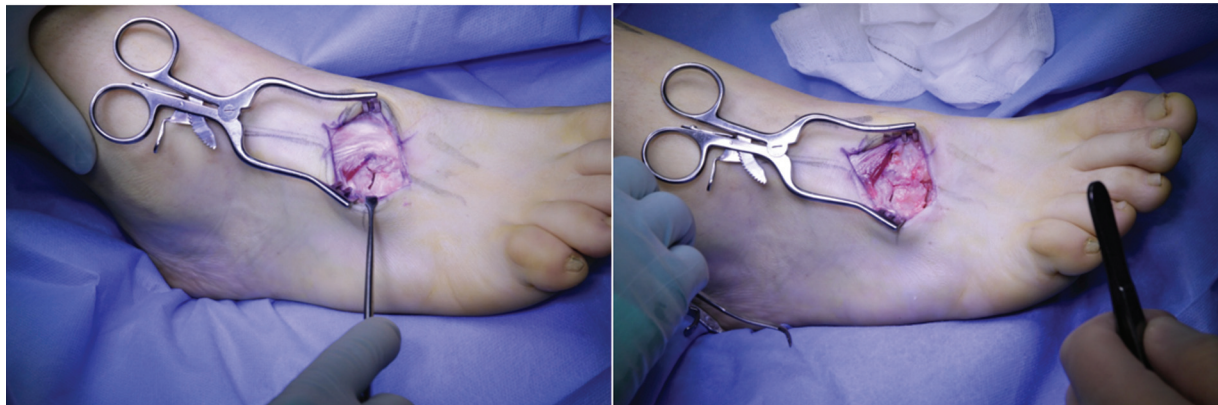### Harvesting Metatarsal Autograft without Vascular Pedicle

The head of the second metatarsal bone or the base of the third or fourth metatarsal bone was identified using a mini fluoroscan and a lazy S incision was performed. The extensor digitorum and extensor hallucis brevis were retracted laterally and the joint

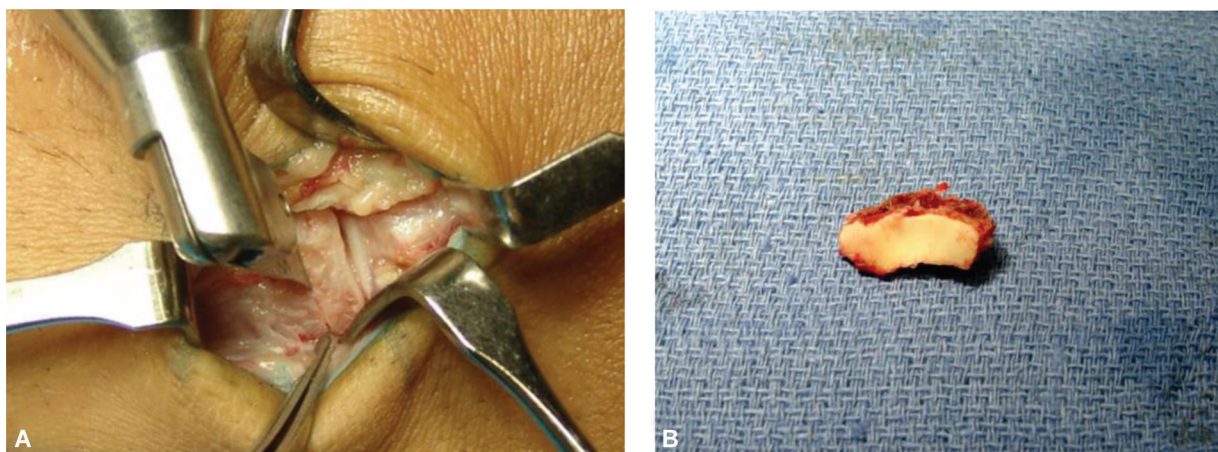


**Fig. 4** Illustration of the nonvascularized articular bone graft of the base of the third metatarsal bone. The cut is performed at the dashed line.

capsule of the third or fourth tarsometatarsal joint was approached via an I-shaped incision (►**Fig. 2**). In two cases the base of the fourth metatarsal bone was harvested (►**Fig. 3**), in five cases the base of the third metatarsal bone (►**Fig. 4**). In

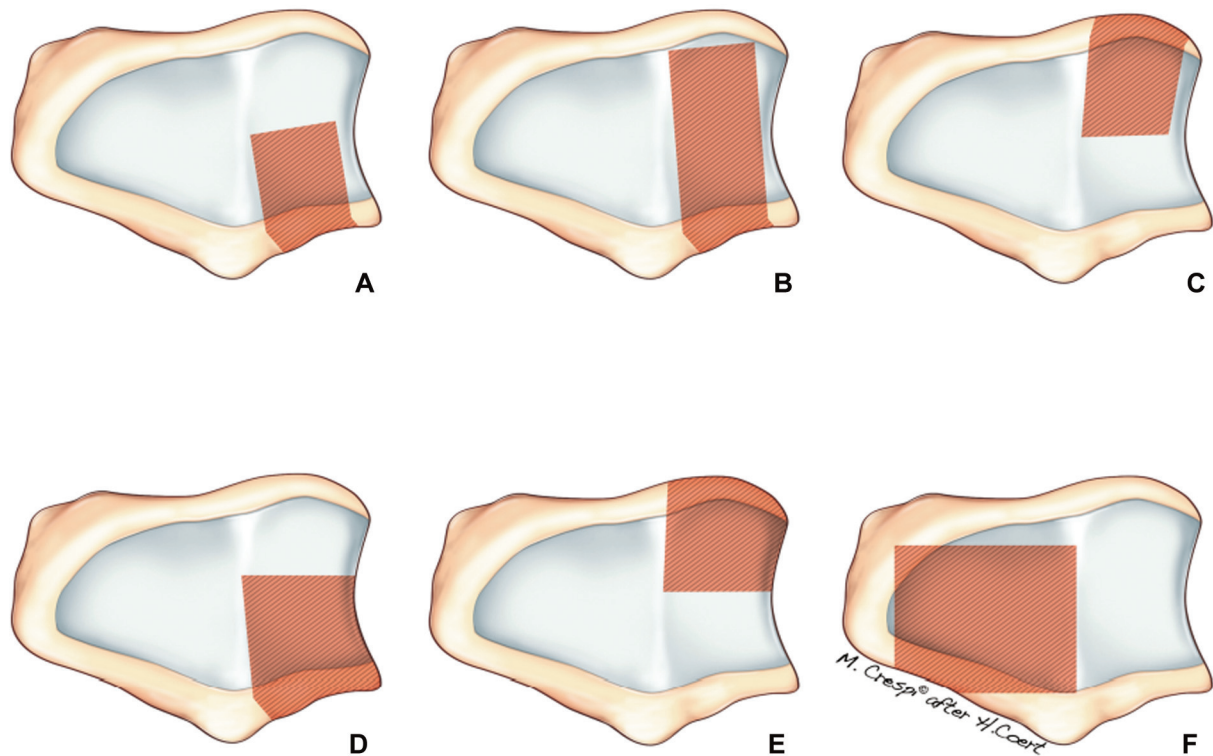


**Fig. 2** Harvest base of fourth metatarsal graft without vascular pedicle.

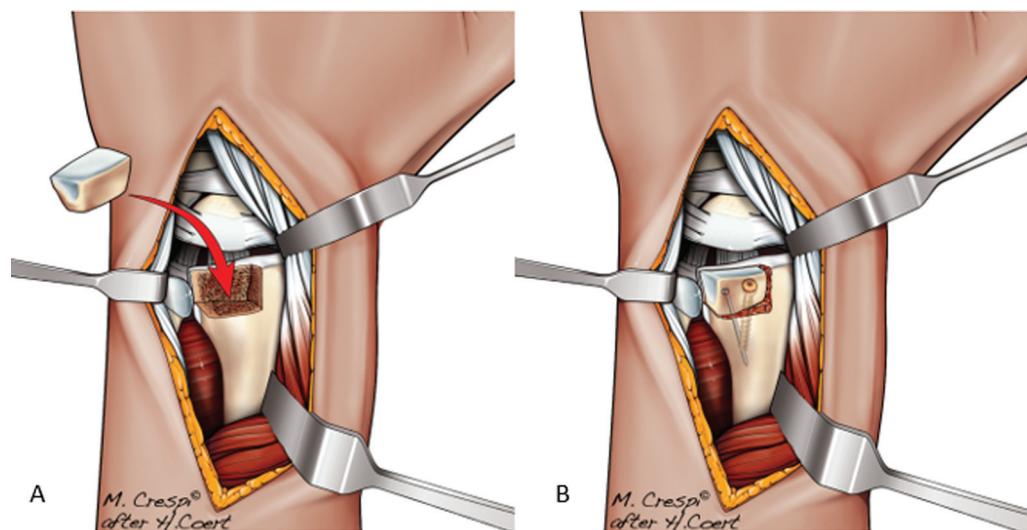


**Fig. 3** (A) The cut in the distal radius with an oscillating saw. (B) Lunate facet after resection.





**Fig. 5** Illustration of possible reconstructions of the articular surface of the distal radius. (A) Dorsal aspect of the lunate facet. (B) Lunate facet. (C) Volar aspect of the lunate facet. (D) Dorsal aspect of the lunate facet and the sigmoid notch. (E) Volar aspect of the lunate facet and the sigmoid notch. (F) Scaphoid facet.



**Fig. 6** (A) Insertion of the graft. (B) Fixation with Kirschner-wire(s) and/or cancellous screw(s).

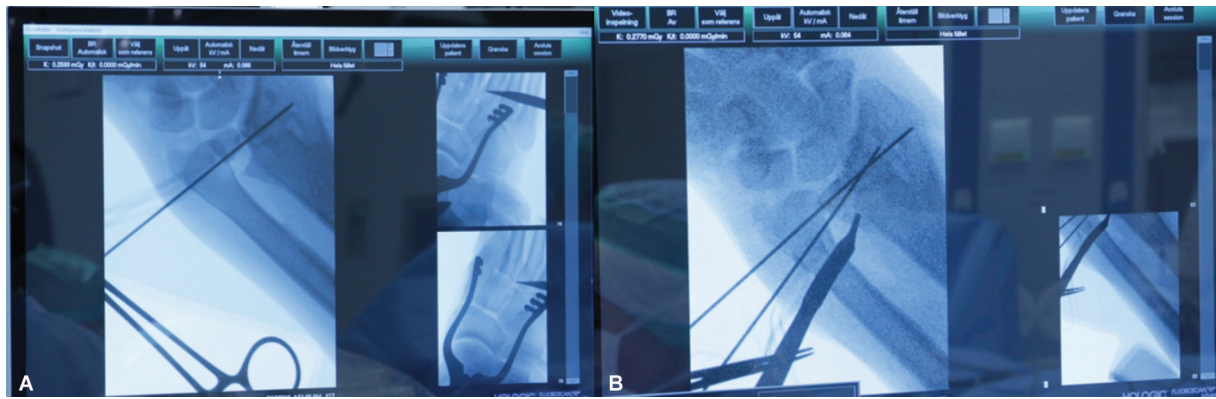
two cases the head of the second metatarsal bone was harvested. Possible reconstructions of the articular surface of the distal radius are illustrated in **Fig. 5**.

These nonvascularized articular bone grafts were harvested according to the technique described by Del Piñal et al.<sup>9</sup> As needed, the base or head of the metatarsal bone was cut to obtain the graft with an oscillating saw. Subsequently, the graft was made to size and inserted “press fit” and then fixed with Kirschner wires (K-wire) or screw and K-wire (**Fig. 7**).

Postoperative treatment consisted of 4 weeks of casting with the foot in a neutral position followed by wearing hiking shoes for an additional period of 4 weeks. Note, in case 1, the postoperative treatment consisted of 6 weeks of foot casting as a result of replacing the base of the metatarsal by the lunate facet that had been removed from the distal radius.

#### Insert of Osteochondral Defects in Distal Radius

The distal radius was approached dorsally via a longitudinal incision. In the extensor retinaculum a Z-shaped incision was



**Fig. 7** (A) Intraoperative fluoroscan. (B) Intraoperative fluoroscan to check position of the graft.

performed to open the third and fourth extensor compartment. A distally based capsular was made similar to arthroplasty of the wrist. The posterior interosseous nerve was divided. With the CT scan and visual confirmation, the damaged area of the distal radius or distal ulna was removed. The cut was made with an oscillating saw in the shape of a rectangle. Four patients had an excision of the dorsal aspect of the lunate facet (►Fig. 5A) with an ulnar cortical pillar of bone left intact. One patient had excision of the scaphoid facet (►Fig. 5F) and two had an excision of the lunate facet and sigmoid notch (►Fig. 5D). In the latter, the medial pillar of bone was offered. In the cases where the ulnar pillar of bone was left intact, the autograft was adjusted and press fit fixed to better accommodate the graft with the metaphyseal and to preserve the insertion of the TFCC. Fixation of the graft (►Fig. 6) was mostly done by buried K-wires (►Fig. 7) and/or corticocancellous screws with a K-wire (►Table 1).

### Reconstruction of Osteochondral Defects in the Ulnar Head

In this study the ulnar head was partially replaced in two cases. The distal ulna was approached dorsally via a hockey stick longitudinal incision over the fifth extensor compartment. The floor of this compartment was used to expose the ulnar head. Partial resection of the second metatarsal or third metatarsal head was performed with keeping the plantar cortex of the metatarsal head intact for adjustment with the fascia plantaris. The sigmoid notch was inspected. Postoperative regime was 6 weeks of casting; 4 weeks long and 2 weeks of forearm casting, which is in contrast with the 3-week-long arm casting by Del Piñal et al.<sup>5</sup>

### Radiographic Assessment

Postoperative X-rays and CT scans were obtained postoperatively for graft positioning and incorporation.

### Statistics

Gaussian variables are presented as means with standard deviations and non-Gaussian variables are presented as medians with range.

## Results

### Demographics and Follow-up

The functional complaints of the patients were pain and/or limited wrist motion. One patient treated with a nonvascularized metatarsal articular graft was excluded due to a central radius defect. The indication for reconstruction was isolated osteochondral defects of the lunate facet, lunate facet and sigmoid notch, radial part of the ulnar head, and scaphoid facet. The study included four men and five women (mean age: 42 y, range: 24–60 y) with isolated symptomatic osteoarthritis of the radiocarpal ( $n=7$ ) or distal radioulnar ( $n=2$ ) joint who were treated with a nonvascularized metatarsal articular bone graft between 2012 and 2022 at the University Medical Centre (►Table 2). All patients had a history of an intra-articular distal radius fracture. The dominant hand was operated in three patients. The mean time between injury and nonvascularized metatarsal bone grafting was 20 months (range: 9–132). Patients were evaluated after a (mean) follow-up of 5 years (range: 18–111).

### Clinical Evaluation

Pre- and postoperative data in terms of active range of motion, grip strength, VAS pain scores, and patient-rated functional outcome measures (PRWE) were not available in all patients and postoperative examination did not take place at standardized moments since surgery (►Table 2). All patients except for one were satisfied with the procedure. This one patient kept considerable wrist pain (VAS score seven) after consecutive reconstruction of the distal radius as well as the distal ulna probably as a result of substantial loss of articular cartilage of the radiocarpal and distal radioulnar joint (case 5 + 8). This patient was the only patient that could not return to its prior work.

### Complications and Revision Surgery

The following three minor complications (►Table 1) occurred in just as many cases (33.3%): one protruding screw in the distal ulna, one protruding K-wire in the distal radius and one adhesion of the extensor tendon of the second digit. The osteosynthesis material complications probably occurred as a result of bone remodeling as described by Del

**Table 1** Surgical characteristics

Case	Previous operation	Functional complaints	Indication for reconstruction + additional procedure	Cartilage status	Graft fixation	Complications	Reoperations
1	Volar locking plate	Pain, limited wrist motion	Isolated osteochondral defect of the lunate facet + removal plate	60% articular surface defect Normal carpal cartilage	2 × 1.5 mm screw	None	None
2	Bone graft from pelvis used for cyst in distal radius	Limited wrist motion	Isolated osteochondral defect of the lunate facet	60% articular surface defect Normal carpal cartilage	2 Kirschner-wires	None	None
3	None	Pain, limited wrist motion	Isolated osteochondral defect of the lunate facet	60% articular surface defect Normal carpal cartilage	1 Kirschner-wire + 1 screw	Adhesion EDC2	Tenolysis EDC2
4	Volar locking plate	Pain, limited wrist motion	Isolated osteochondral defect of the lunate facet and sigmoid notch + removal of three-angle stable screws ulna side radius	60% articular surface defect Normal carpal cartilage	2 Kirschner-wires	None	None
5	SL and LT capsuloplasty	Pain	Isolated osteochondral defect of the lunate facet and sigmoid notch	70% articular surface defect Normal carpal cartilage	2 Kirschner-wires	Persistent ulnar wrist pain	Reconstruction partial distal ulna
6	Volar locking plate + TFCC reinsertion	Pain	Isolated osteochondral defect of the lunate facet	60% articular surface defect Normal carpal cartilage	2 Kirschner-wires	None	None
7	None	Pain	Isolated osteochondral defect of the scaphoid facet	70% articular surface defect Normal carpal cartilage	2 Kirschner-wires	Protruding Kirschner-wire	Flattening Kirschner-wire
8	Reconstruction lunate fossa + sigmoid notch	Pain	Isolated osteochondral defect of the radial part of the ulnar head	60% articular surface defect Normal sigmoid notch cartilage	1 screw	Protruding screw distal ulna	Removal of screw
9	Adams-Berger procedure	Pain	Isolated osteochondral defect of the radial part of the ulnar head	60% articular surface defect Normal sigmoid notch cartilage DRUJ stable	2 Kirschner-wires	None	None

Abbreviations: DRUJ, distal radioulnar articulation; EDC, extensor digitorum communis; LT, lunotriquetral; SL, scapholunate; TFCC, triangular fibrocartilage complex; TWA, total wrist arthroplasty.

**Table 2** Demographic characteristics and clinical outcome

Case	Gender (M/F)	Age (y)	FU (mo)	Flex + ext pre/post (degrees)	Rotation pre/post (degrees)	Grip pre/post (kg)	VAS pre/post (0–10)	PRWE post	PRS	Work status
1	M	26	111	70/106	–/156	–/44	7/0	P0 F0 T2	Satisfied	ICT manager
2	M	43	105	105/148	180/180	62.7/41	0/0	P0 F0 T2	Satisfied	Farmer
3	M	27	104	135/164	180/180	35/41	2/0	P0 F0 T1	Satisfied	Physiotherapist
4	F	30	26	35/120	150/180	–	5/1	P15 F15 T33	Satisfied	Administrative assistant
5	F	57	45	95/–	180/180	–	–/8	–	Not satisfied	Production employee
6	M	24	48	95/60	160/160	–	–/2	P13 F0 T16	Satisfied	Gardener
7	F	60	18	75/100	170/180	–	–/0	P0 F0 T4	Satisfied	Returned
8	F	57	53	–/55	180/160	–	8/7	P34 F24 T64	Not satisfied	Did not return as a production employee
9	F	52	27	105/95	160/160	–	–/4	P25 F9,5 T44,5	Satisfied	Nurse
Ave.		41.8	59.7	89/113	151/150	49/41	4.4/1.6	P7,4 F6,1 T20,3		

Abbreviations: Ave., average; ICT, information and communications technology; F, female; FU, follow-up; M, male; post, postoperative; pre, preoperative; PRS, patient-rated satisfaction; PRWE, Patient-Rated Wrist Evaluation; VAS, visual analogue scale.

Notes: PRWE: range from 0 to 50 for pain and function; with 0 best and 50 indicating worst outcome. Total score ranges from 0 to 100, with 0 best and 100 indicating worst outcome.

Piñal et al<sup>11</sup> or as a result of an early active mobilization regime. The three patients mentioned above were operated again: removal of the screw, flattening the K-wire, and tenolysis. In five cases mild foot pain and stiffness was seen at 1 year that was treated by wearing hiking shoes.

### Radiological Evaluation

Total bone fusion was achieved in all cases after a (mean) follow-up of 5 years (range: 18–111 mo) without evidence of nonunion, avascular necrosis, or bone resorption (► **Table 3**).

### Discussion

This study describes the midterm results of nonvascularized metatarsal articular bone grafting in 10 patients with large post-traumatic osteochondral defects of the wrist with a (mean) follow-up of 5 years. In all cases osseointegration was possible without a vascular pedicle to the bone graft. Three patients in the study described by Goon et al<sup>7</sup> were in this

current study included and evaluated at a follow-up duration up to 9 years. The patients had a pain score in the VAS of 0 points during rest and activities. In one case the mean grip strength decreased in time (62.7 vs. 41.0 kg) probably due to less manual laborer work as a farmer because a part of its cattle was sold several years after his surgery. These patients were very satisfied with the procedure and able to practice their hobbies such as triathlon, cross fit, and mountain biking. Overall, the mean wrist motion increased in five cases and decreased in two cases. The pain score in the VAS decreased in five cases. These operative procedures are prone to minor osteosynthesis material complications, probably as a result of bone remodeling as described by Del Piñal et al<sup>11</sup> or as a result of an early active mobilization regime.

The donor site used in this study was described by Goon et al<sup>7</sup> and is in line with Del Piñal et al<sup>9</sup> but differed slightly from the donor sites used by Mehin et al<sup>4</sup> and Obert et al<sup>6</sup> that makes a detailed comparison of the functional not possible (► **Table 3**). The functional outcome data in the studies are not sufficient to allow comparison between the data due to

**Table 3** Comparison table vascularized and nonvascularized articular bone grafting studies

Study	Mehin et al, 2003 (n = 2)	Obert et al, 2011 (n = 7)	Del Piñal et al, 2012 (n = 1)	Del Piñal et al, 2013 (n = 7)	Stougie et al, 2022 (n = 9)
Donor site	Autologous proximal tibiofibular joint graft	Autologous anterior costal cartilage graft	Autologous 2nd metatarsal graft	Autologous 3rd metatarsal graft	Autologous 2nd, 3rd, 4th metatarsal graft
Surgical technique	Nonvascularized	Nonvascularized	Vascularized	Vascularized	Nonvascularized
Gender	1M, 1F	4M, 3F	1M	6M, 1F	4M, 5F
Mean age, y (range)	36 (22–49)	41 (18–74)	26	36 (26–55)	42 (23–60)
Delay (mo)	17	–	3, 5	17	30
Dominant hand affected	1	3	–	4	3
Relevant medical history	Intra-articular malunion of the distal radius (n = 1) Acute severe distal radius fracture (n = 1) <sup>a</sup>	Intra-articular malunion of the distal radius (n = 5) Septic scaphoid radial destruction (n = 1) Osteoarthritis (n = 1)	Ulnar head reconstruction (n = 1)	Intra-articular malunion of the distal radius (n = 7)	Intra-articular malunion of the distal radius (n = 7) Ulnar head reconstruction (n = 2)
Follow-up (mo) (range)	49.5 (39–60)	26 (6–40)	48	65 (20–96)	59.5 (18–111)
Complications wrist	No complications reported	Resection scaphoid that was associated with the reconstruction was insufficient for pain relief	Protruding screws (n = 1)	Excision ulnar styloid (n = 1) Excision skin island (n = 2) Screw removal (n = 1) Volar locking plate removal (n = 1)	Protruding screw (n = 1) Protruding K-wire (n = 1) Adhesion EDC2
Complications donor site	1 × “No leg pain” 1 × “No pain at the proximal tibiofibular joint”	Minimal donor site morbidity “Discomfort”	Asymptomatic foot	Minimal donor site Foot morbidity	Minimal donor site Foot morbidity
Mean AROM (post – pre = Δ in degrees) (post – pre = % contralateral side) Flexion–extension RD UD Rotation	No preoperative measurements Post: 117 26 30 186	102 – 44 = 58 – – “Preserved”	Pre: 90 Post: 99% 110 – 40 = 70	100 – 50 = 50 10 – 5 = 5 34 – 23 = 11 162 – 99 = 63	113 – 89 = 24 151 – 150 = 1
Mean (VAS) score pain (post – pre = Δ)	Post: 1 × “no pain” 1 × not reported	2.5 – 5.0 = – 2.5	1x “no pain”	1 – 8 = – 7	1.8 – 4.8 = – 3
Grip strength (post – pre = Δ in kg) (post – pre = Δ in % from contralateral side)	Post: 1 × 24 kg 1 × 57.3 kg	27 – 15 = 12	43 – 14 = 29 81 – 30% from contralateral side	86–45% Only % from contralateral side	49–41 = – 8



**Table 3** (Continued)

Study	Mehin et al, 2003 (n = 2)	Obert et al, 2011 (n = 7)	Del Piñal et al, 2012 (n = 1)	Del Piñal et al, 2013 (n = 7)	Stougie et al, 2022 (n = 9)
Patient satisfaction	-	-	-	High	High
Return to work	-	5/7 1 retired	1	5/7 2 retired	8/9
Return to hobby	1				8/9
Plain films	"Normal cartilage space" "Excellent radiocarpal joint space"	No avascular necrosis or metaplasia on the cartilaginous side	Joint narrowing distal radioulnar joint	No signs of osteoarthritis or resorption	No evidence of nonunion, avascular necrosis, or bone resorption
Postoperative regime	3-wk immobilization Short-arm cast 6-wk External fixation device <sup>a</sup>	1-mo immobilization Short-arm cast	3-wk immobilization Long-arm cast	5-wk immobilization Short-arm cast	1-wk immobilization Short-arm cast Long-arm cast <sup>a</sup>

Abbreviations: AROM, active range of motion; EDC, extensor digitorum communis; F, female; M, male; post, postoperative; pre, preoperative; RD, radial deviation; UD, ulnar deviation; VAS, visual analogue scale.  
 Note: A, difference.  
<sup>a</sup>Acute case.

small sample sizes, lack of preoperative and postoperative data regarding wrist and forearm motion, grip strength, and pain score in the VAS.

Our midterm results of nonvascularized metatarsal bone grafting suggest the same functional outcome, patient satisfaction, foot morbidity, and minor complications as vascularized metatarsal bone grafting. The postoperative regimes differ considerably that may result in less complications regarding protruding osteosynthesis material in Del Piñal et al's<sup>5,11</sup> study and better wrist motion in our study.

Due to the absence of a microsurgical component in this procedure, it is probably less time consuming and technically less demanding. Another advantage is an easier inset of the metatarsal bone graft that results in a less bulky graft. The results in our study demonstrate a decrease in pain score in the VAS with a reasonable wrist motion with a follow-up up to 9 years in three cases. However, the long-term results are unknown.

This study is limited by its retrospective design, heterogeneous and small group, slightly various surgical techniques, donor sites, and variation in follow-up duration. Expectations of surgery were not available for all patients. As a result, patient satisfaction and PRWE scores were evaluated retrospectively that may cause recall bias among participants. Due to the small and heterogeneous group size statistical analysis was limited to descriptive statistical analysis, which is a drawback of this study.

In conclusion, we believe that nonvascularized metatarsal articular bone grafting for osteochondral defects of the wrist becomes a feasible option for young and/or demanding patients when they are not ready for (partial) fusion or arthroplasty. Patients should be aware of the risk of minor complications, which may require additional surgery and patients should be informed in the consent process that they are likely to have mild foot pain at 1 year that requires wearing walking boots to reduce the mild pain. The nonvascularized metatarsal bone grafts do not interfere with possible future salvage procedures such as a proximal row carpectomy, total wrist arthroplasty, and distal radioulnar joint arthroplasty. For the future, it could be an alternative treatment when implants become less available.

#### Ethical Approval

Approval was obtained by the local Ethics Committee of the University Medical Centre Utrecht, the Netherlands.

#### Informed Consent

Written informed consent was obtained from a legally authorized representative(s) for anonymized patient information to be published in this article.

#### Authors' Contributions

All names authors were actively involved in the planning, enactment, and writing up of the study.

#### Funding

None declared.

**Conflict of Interest**

None declared.

**References**

- 1 Gates DH, Walters LS, Cowley J, Wilken JM, Resnik L. Range of motion requirements for upper-limb activities of daily living. *Am J Occup Ther* 2016;70(01):p1, p10
- 2 Saffar P. Radio-lunate arthrodesis for distal radial intraarticular malunion. *J Hand Surg [Br]* 1996;21(01):14–20
- 3 Zijlker HJA, Ritt MJPF, Beumer A. Fourth-generation total wrist arthroplasty: a systematic review of clinical outcomes. *J Wrist Surg* 2021;11(05):456–464
- 4 Mehin R, Giachino AA, Backman D, Grabowski J, Fazekas A. Autologous osteoarticular transfer from the proximal tibiofibular joint to the scaphoid and lunate facets in the treatment of severe distal radial fractures: a report of two cases. *J Hand Surg Am* 2003; 28(02):332–341
- 5 del Piñal F, Klausmeyer M, Moraleda E, et al. Vascularized graft from the metatarsal base for reconstructing major osteochondral distal radius defects. *J Hand Surg Am* 2013;38(10):1883–1895
- 6 Obert L, Lepage D, Ferrier M, Tropet Y. Rib cartilage graft for posttraumatic or degenerative arthritis at wrist level: 10-year results. *J Wrist Surg* 2013;2(03):234–238
- 7 Goon PKY, Stougie SD, Vaghela KR, Coert JH. Reconstruction of distal radius osteochondral defects using metatarsal autografts: a multi-case series. *Rev Iberam Cir Mano.* 2019; 47:3–9
- 8 MacDermid JC, Tottenham V. Responsiveness of the disability of the arm, shoulder, and hand (DASH) and patient-rated wrist/hand evaluation (PRWHE) in evaluating change after hand therapy. *J Hand Ther* 2004;17(01):18–23
- 9 Del Piñal F, Garcia-Bernal F, Delgado J, Sanmartin M, Regalado J. Reconstruction of the distal radius facet by a free vascularised osteochondral autograft: anatomical study and report of a patient. *J Hand Surg Am* 2005;30A:1200.e1–1200.e14
- 10 Nakamura T. Surgeons' level of expertise. *J Wrist Surg* 2020;9(03): 185–185
- 11 del Piñal F, Guerrero-Navarro ML, Studer A, Thams C, Moraleda E. Reconstruction of the ulnar head with a vascularized second metatarsal head: case report. *J Hand Surg Am* 2012;37(08): 1568–1573