Article published online: 2023-09-22

Images in GI Infection: Common Cyst at an Uncommon Location: Hydatid Cyst of Lesser Omentum

Vibhu Jain[1] Abuji Kishore[1] Santhosh Irrinki[1] Yashwant Raj Sakaray[1]

[1] Department of General Surgery, Postgraduate Institute of Medical Education and Research, Chandigarh, India

J Gastrointest Infect 2023;13:46–47.

Address for correspondence Yashwant Raj Sakaray, MBBS, MS, Department of General Surgery, Postgraduate Institute of Medical Education and Research, Sector 12, Chandigarh 160012, India (e-mail: sakaraypgi@gmail.com).

Abstract

Hydatid disease is a parasitic disease caused most commonly by the tapeworm Echinococcus granulosus. Treatment options can range from observation to radical excision of the cyst. The most common site is the liver, and the most common extra-hepatic location is the lung. We present a rare case of a 22-year-old male, who presented with complaints of right upper quadrant abdominal pain for a duration of 3 months, which on evaluation was associated with eosinophilia and radiological imaging revealed an extra-hepatic hydatid cyst arising from the lesser omentum. Pericystectomy was performed, and the postoperative course was grossly uneventful. The cut section of the cyst and the final histopathological study confirmed the diagnosis. There are very few case reports in the literature of isolated omental hydatidosis, and we present one such unique case.

Keywords
- hydatid cyst
- uncommon location
- lesser omentum

A 22-year-old male presented with right upper abdominal pain for a duration of 3 months. There was a single spike of high-grade fever of 102°F (38.9°C). It was also associated with early satiety. There were no features suggestive of cholangitis. Per-abdomen examination was grossly normal. He was evaluated with an ultrasound abdomen which revealed a cystic lesion of size 8.6 × 7 cm in segment VI and VII of liver with dependent debris and calcific foci. Further evaluation with a triphasic contrast-enhanced computerized tomography abdomen revealed a large cystic lesion of size 7.8 × 8.9 × 10.5 cm in relation to the left lobe of the liver with extension into subhepatic and gastrohepatic recess with a thin concentric membrane within the cyst (►**Fig. 1A, B**). Serological testing showed elevated anti-*Echinococcus* antibodies (immunoglobulin G; 1:1,600 by ELISA [enzyme-linked immunosorbent assay] method). With a provisional diagnosis of hydatid cyst, the patient was planned for exploratory laparotomy after a preoperative course of Albendazole for 2 weeks. Intraoperatively there was a cystic lesion seen in the lesser omentum. However, the cyst was seen to be free from the liver surface and was in close relation to the lesser curvature of the stomach (►**Fig. 1C**). Pericystectomy was performed. A thick-walled single-layered cyst was retrieved from within the mass; however, no daughter cysts were seen (►**Fig. 1D**). The histopathological examination of the sections from the cyst showed thick, avascular, eosinophilic laminated membrane with a few hooklets, with overall features consistent with hydatid cyst. The postoperative course was uneventful, and the patient was discharged on postoperative day 4. In view of the fact that the cyst was excised in toto and there was no intraoperative spillage of the cyst contents, he was not advised postoperative Albendazole therapy.

Hydatid disease is a parasitic disease caused by the larval stage of the tapeworm *Echinococcus* primarily affecting the liver and lung.[1] The most common location of

received
January 9, 2023
revised
January 25, 2023
accepted
January 27, 2023

DOI https://doi.org/10.1055/s-0043-1768147.
ISSN 2277-5862.

© 2023. Gastroinstestinal Infection Society of India. All rights reserved.
This is an open access article published by Thieme under the terms of the Creative Commons Attribution-NonDerivative-NonCommercial-License, permitting copying and reproduction so long as the original work is given appropriate credit. Contents may not be used for commercial purposes, or adapted, remixed, transformed or built upon. (https://creativecommons.org/licenses/by-nc-nd/4.0/)
Thieme Medical and Scientific Publishers Pvt. Ltd., A-12, 2nd Floor, Sector 2, Noida-201301 UP, India

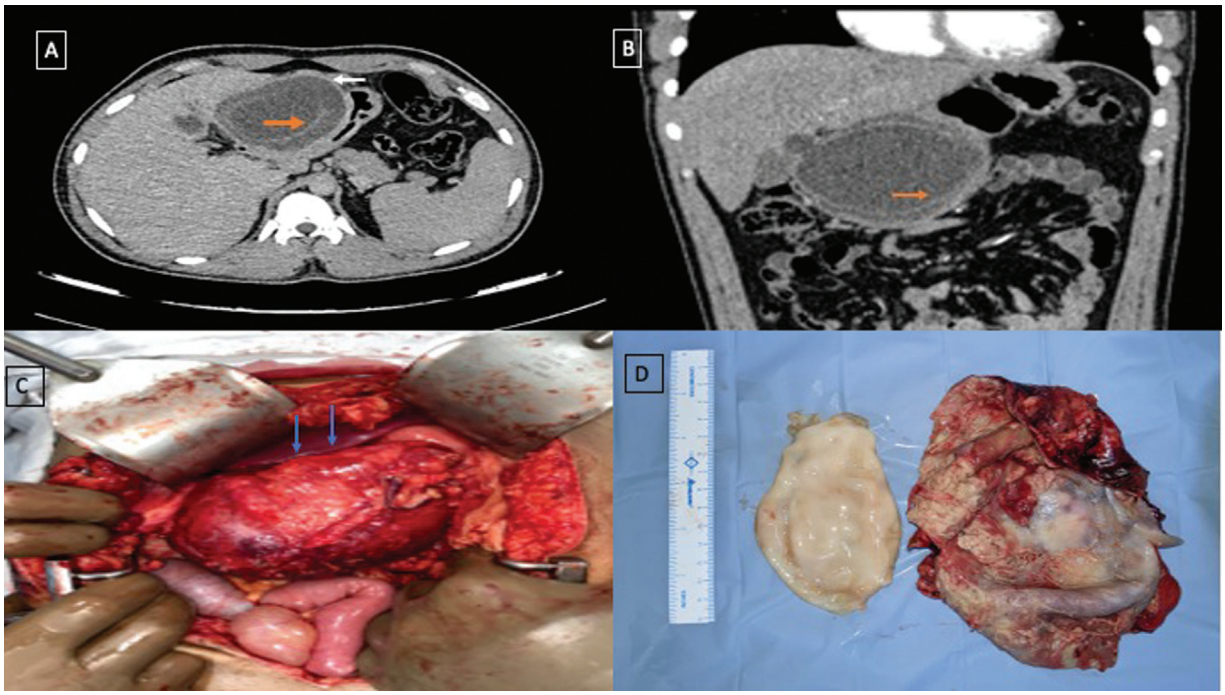

Fig. 1 **(A)** Axial CT scan image showing cystic lesion in relation to the left lobe of the liver with extension into gastrohepatic space (*white arrow*) and containing a thin concentric membrane (*orange arrow*). **(B)** Coronal CT scan image showing the cystic lesion in the lesser omentum with the concentric membrane within (*orange arrow*). **(C)** Intraoperative image showing the mass in the lesser omentum which was seen to be free from the lower edge of the liver (*blue arrow*). **(D)** Cut section of the resected specimen showing a thick membranous cyst which was retrieved from within the resected mass. CT, computed tomography.

hydatid cyst is the liver, and the most common extra-abdominal site is lung.[2] Ours was a unique case in terms of the organ of origin from the lesser omentum, with very few number of case reports available in the literature with hydatid cyst arising from the lesser omentum.[3–5] Omental hydatid should be excised, preferably by the open laparotomy approach or even laparoscopically. Special precautions should be taken like covering the rest of the peritoneal cavity with betadine or 20% saline-soaked sponges to avoid dissemination of the disease in case of inadvertent rupture of the cyst.

Informed Consent
Written consent was obtained from the patient.

Ethical Statement
Ethical approval was taken from the institute's ethics board.

Authors' Contribution
V.J.: preparation of manuscript and data collection; A.K.: preparation of manuscript and data collection; S.I.: conceptualization and supervision; Y.R.S: patient management, conceptualization, and supervision.

Data Availability Statement
There are no data associated with this work.

Conflict of Interest
None declared.

References
1 Leitão P, Carvalho A, Fernandes T, Gonçalves J. Cystic echinococcosis: a case of extrahepatic intra-abdominal involvement. Case Rep Radiol 2017;2017:8919546
2 Pedrosa I, Saíz A, Arrazola J, Ferreirós J, Pedrosa CS. Hydatid disease: radiologic and pathologic features and complications. Radiographics 2000;20(03):795–817
3 Sable S, Mehta J, Yadav S, Jategaokar P, Haldar PJ. "Primary omental hydatid cyst": a rare entity. Case Rep Surg 2012;2012:654282
4 Sekmenli T, Koplay M, Sezgin A. Isolated omental hydatid cyst: clinical, radiologic, and pathologic findings. J Pediatr Surg 2009; 44(05):1041–1043
5 Sethi SK, Patnaik S, NarayanNayak SN. Isolated omental hydatid cyst–a case report. J Indian Med Assoc 2004;102(11):644–646, 646

 © 2023. Gastroinstestinal Infection Society of India. All rights reserved.