

Enhancement of the parent vessel in a giant thrombosed aneurysm

Aneurisma gigante trombosado com realce do vaso de origem

Flávia Sprenger¹ Zeferino Demartini Junior² Bernardo Corrêa de Almeida Teixeira¹

¹ Universidade Federal do Paraná, Hospital de Clínicas, Departamento de Radiologia, Curitiba PR, Brazil.

² Universidade Federal do Paraná, Hospital de Clínicas, Departamento de Hemodinâmica, Curitiba PR, Brazil.

Address for correspondence: Flávia Sprenger (email: flaviasprenger@gmail.com).

Arq. Neuropsiquiatr. 2023;81:510–512.

A 62-year-old female with a previous history of 2 ischemic strokes presented with sudden headache and left hemiparesis. Imaging revealed a partially-thrombosed right cavernous carotid artery aneurysm (► **Figures 1** and **2**). Vessel wall imaging showed an extensive vascular wall enhancement of the parent vessel, which might be related to vasa vasorum or inflammation (► **Figure 3**). The role of vascular inflammation within the defective areas of the aneurysm are well known. However, less explored are the inflammatory changes of the parent vessel, which can be detected by magnetic resonance (MR) angiography (► **Figure 4**) and indicate a pathologic artery more subject to aneurysmal formation and thrombotic events.^{1,2}

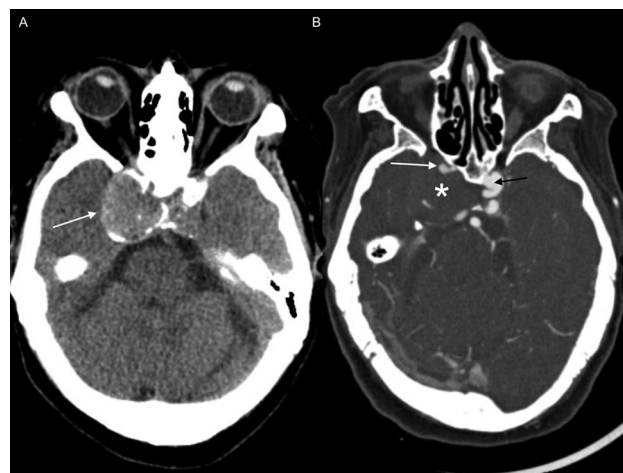

Figure 1 Unenhanced axial computed tomography (CT) scan (A) and CT angiography (B) showing a hyperdense mass adjacent to the right cavernous sinus with peripheral calcifications (arrow in A) and no enhancement (asterisk in B), opacification of the pervious internal carotid artery (white arrow in B), and a small contralateral aneurysm (black arrow).

received
September 9, 2022
received in its final form
November 5, 2022
accepted
November 20, 2022

DOI <https://doi.org/10.1055/s-0043-1767820>.
ISSN 0004-282X.

© 2023. Academia Brasileira de Neurologia. All rights reserved. This is an open access article published by Thieme under the terms of the Creative Commons Attribution 4.0 International License, permitting copying and reproduction so long as the original work is given appropriate credit (<https://creativecommons.org/licenses/by/4.0/>).
Thieme Revinter Publicações Ltda., Rua do Matoso 170, Rio de Janeiro, RJ, CEP 20270-135, Brazil

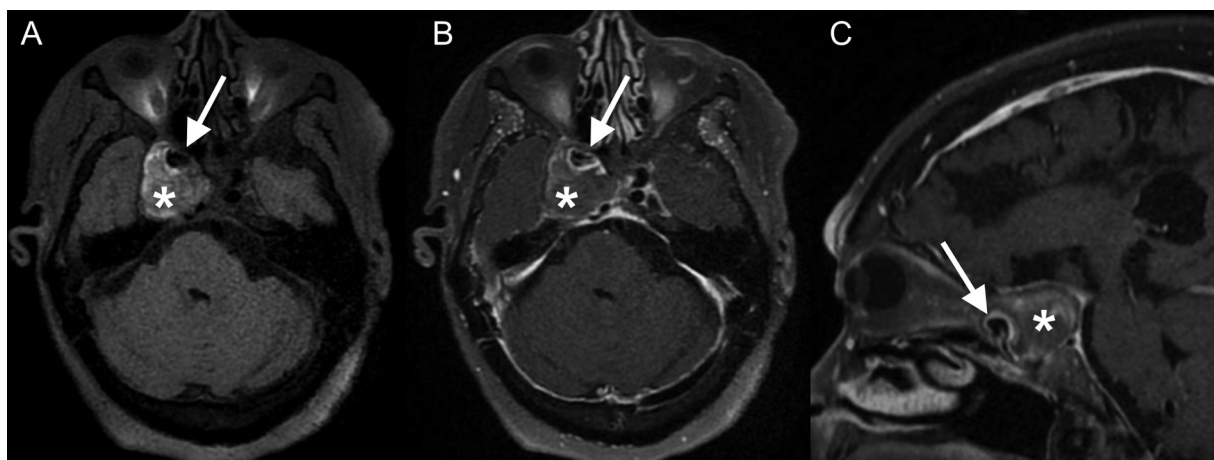


Figure 2 Pre- (A) and postgadolinium vessel wall magnetic resonance images (B-C) showing the expected flow void of the parent aneurysm (arrow in A) and the giant non-enhancing thrombosed eccentric component (asterisks). Notice the thickened and enhancing wall of the parent internal carotid artery (arrows in B and C).

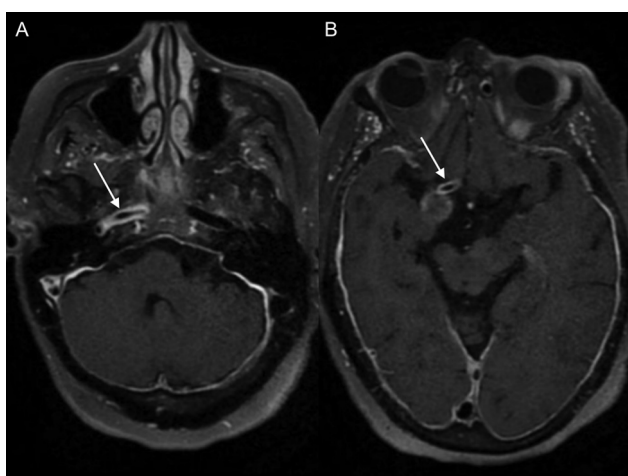


Figure 3 Postgadolinium axial vessel wall magnetic resonance images of the petrous (A) and remaining precommunicant segments (B), showing the extension of the arterial wall thickening and enhancement (arrows).

Authors' Contributions

FS: was responsible for case and literature review; FS, ZDJ, and BCAT: were responsible for gathering the images and writing the manuscript; BCAT: was responsible for this report's concept and manuscript review.

Conflict of Interest

The authors have no conflict of interest to declare.

References

- 1 Rutland JW, Delman BN, Gill CM, Zhu C, Shrivastava RK, Balchandani P. Emerging use of ultra-high-field 7T MRI in the study of

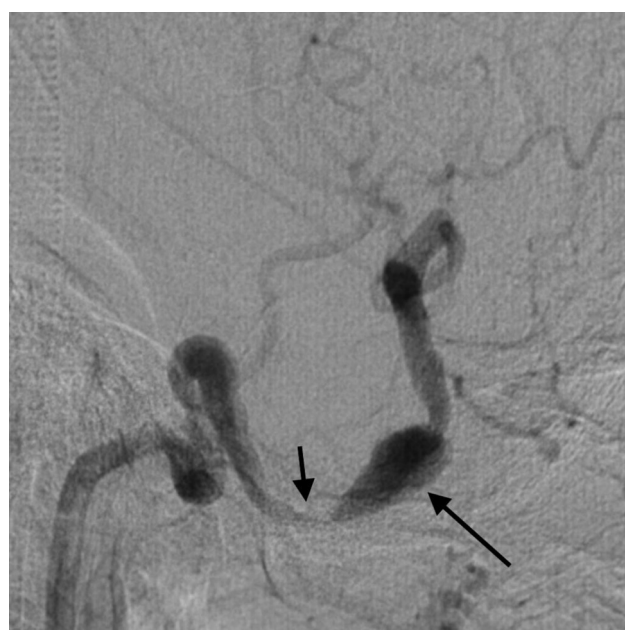

Figure 4 Angiography demonstrating focal stenosis of the right cavernous internal carotid artery due to thrombus compression (short arrow), followed by an aneurysmal dilation (long arrow), with no opacification of the previously-described thrombosed part.

intracranial vascularity: State of the field and future directions. *AJNR Am J Neuroradiol* 2020;41(01):2-9

- 2 Samaniego EA, Roa JÁ, Zhang H, et al. Increased contrast enhancement of the parent vessel of unruptured intracranial aneurysms in 7T MR imaging. *J Neurointerv Surg* 2020; 12(10):1018-1022