

# Update on Surgical Management of FAP

Tianqi Zhang, MD<sup>1</sup> Ye Xu, PhD, MD<sup>1</sup>

<sup>1</sup>Department of Colorectal Surgery, Fudan University Shanghai Cancer Center, Shanghai, People's Republic of China

Address for correspondence Ye Xu, PhD, MD, Dong'an Road, 270, Shanghai, 200032, People's Republic of China (e-mail: yexu@shmu.edu.cn).

Clin Colon Rectal Surg 2023;36:385–390.

## Abstract

Familial adenomatous polyposis (FAP) is an autosomal dominant disease caused by pathogenic germline adenomatous polyposis coli mutation, and characterized with multiple adenomas in the colon and the rectum. Various genetic variants have been confirmed to be associated with corresponding FAP phenotypes, which play important roles in the diagnosis and surgical treatment of FAP. Generally, proctocolectomy is recommended for FAP patients at the age of 20s. Exceptionally, for patients with attenuated FAP, high-risk of desmoid, chemoprevention therapy, or other circumstances, surgery can be postponed. With the wide application of minimal invasive surgery in colorectal cancer, laparoscopic, robotic surgery, and natural orifice specimen extraction are proved to be feasible for FAP patients, but high-level evidences are needed to confirm their safety and advantages. In the times of precise medicine, the surgical management of FAP should vary with individuals based on genotype, phenotype, and clinical practice. Therefore, in addition to innovation in surgical procedures, investigation in links between genetic features and phenotypes will be helpful to optimize the surgical management of FAP in the future.

## Keywords

- ▶ familial adenomatous polyposis
- ▶ genotype
- ▶ phenotype
- ▶ surgery

With technological advances in genomics and analytics, genetics research has developed rapidly. Deeper understanding of the link between genome-wide sequence and phenotypes will empower the development of diagnosis and therapy in hereditary diseases in clinical setting.<sup>1</sup> Nowadays, more underlying mechanisms of hereditary colorectal cancer (HCRC) had been gradually recognized. Familial adenomatous polyposis (FAP), one of the common HCRCs, accounting for 1% of all colorectal cancer (CRC), is an autosomal dominant disease.<sup>2</sup> It is primarily caused by germline adenomatous polyposis coli (APC) mutation, which is a tumor suppressed gene and located at 5q21-q22 locus.<sup>3</sup> APC can inhibit the initiation and development of CRC, while its mutations contribute in early adenoma creation leading to chromosomal instability.<sup>4</sup>

FAP is characterized with multiple adenomas in the colon, so proctocolectomy is recommended for patients diagnosed with FAP to prevent adenocarcinoma from developing into CRC. As FAP is a complex and genetic defects disease with several clinical features and genotypes, making a therapeutic scheme for FAP individuals is a collaborative task by many

specialists. Moreover, it has been demonstrated that FAP phenotypes are associated with genotypes of APC mutations.<sup>5</sup> Herein, based on the concept of personalized treatment for cancer, it is significant to explore the relationship between FAP genotypes and phenotypes, which may direct the surgery timing and approach options among FAP patients.

This review will outline the current treatment strategies and focus on the updated surgical management of FAP.

## Manifestation and Diagnosis of FAP

Varied with the APC variants, FAP patients are characterized with hundreds of colonic adenomas since adolescence and 100% penetrance. Based on the burden of polyposis in the colon and the rectum, FAP is divided into profuse FAP (over 1,000, in which normal colorectal mucosa cannot be macroscopically or endoscopically observed), sparse FAP (100–1,000 adenomas, in which normal colorectal mucosa is visualized and multiple adenomas can be counted), and attenuated FAP (AFAP) (10–99 adenomas). Profuse and

article published online  
April 17, 2023

Issue Theme Application of Molecular Profiling in Colorectal Cancer Surgery; Guest Editor: Pei-Rong Ding, MD, PhD

© 2023, Thieme. All rights reserved.  
Thieme Medical Publishers, Inc.,  
333 Seventh Avenue, 18th Floor,  
New York, NY 10001, USA

DOI <https://doi.org/10.1055/s-0043-1767707>.  
ISSN 1531-0043.

**Table 1** FAP-associated lesions

Colonic manifestation (polyps burden)	Classical FAP
	Profuse FAP (> 1,000)
	Sparse FAP (100–1,000)
	Attenuated FAP (10–99)
Extracolonic manifestation	Desmoid
	Upper intestinal polyposis (fundic gland polyposis, gastric adenoma, duodenal adenoma)
	Congenital hypertrophy of retinal pigment epithelium (CHRPE)
	Neoplastic lesions (subcutaneous soft tissue tumors, osteomas, and dental abnormalities)
	Other tumorous lesions (thyroid cancer, adrenal tumor, hepatoblastoma, and brain tumors)

Abbreviation: FAP, familial adenomatous polyposis.

sparse types are often collectively called classical FAP (CFAP) or typical FAP, while strict differentiation between severe and sparse types is of little clinical significance.<sup>6</sup>

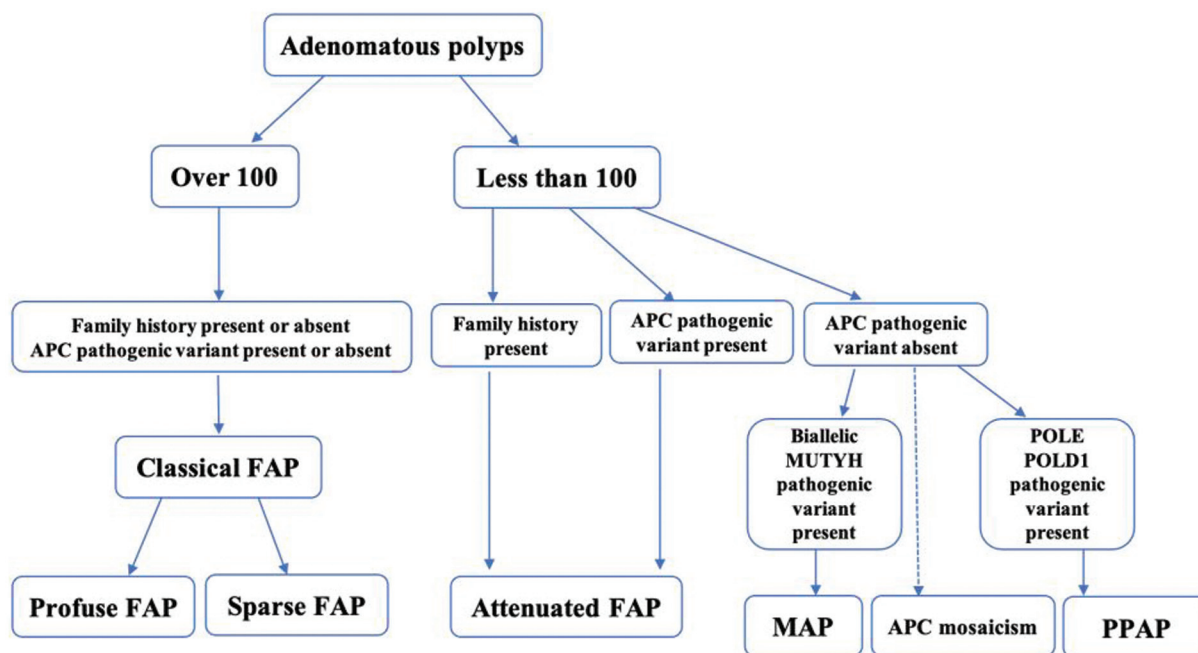
In addition to colorectal manifestations, some extracolonic lesions are associated with FAP (► **Table 1**): (1) desmoid tumors (DTs), second cause of death of patients with FAP, are fibroblastic lesions that do not metastasize but present aggressive growth and it has demonstrated that family-history, specific APC mutations, female, and surgery are high-risk factors in FAP-associated DT<sup>7,8</sup>; (2) upper intestinal polyposis, including fundic gland polyposis, gastric

adenoma, duodenal adenoma, and ampullary adenoma, is often detected in FAP patients; (3) congenital hypertrophy of retinal pigment epithelium (CHRPE); (4) neoplastic lesions, such as subcutaneous soft tissue tumors, osteomas, and dental abnormalities; and (5) other tumorous lesions, including thyroid cancer, adrenal tumor, hepatoblastoma, and brain tumors.<sup>6,9,10</sup>

Therefore, FAP can be diagnosed by clinical characters ( $\geq 100$  adenomas in colorectal, regardless of FAP family history or  $< 100$  adenomas in the presence of a family history of FAP) and/or genetical test (pathogenic germline APC variant).<sup>6,10</sup> Extracolonic manifestations are useful clues for FAP diagnosis. Though APC mutations may not be detected in 20 to 40% of FAP patients, genetic test is necessary, because FAP should be differentiated from MUTYH-associated polyposis (MAP, an autosomal recessive mode of inheritance caused by biallelic germline MUTYH mutations), polymerase proofreading-associated polyposis (an autosomal dominant mode of inheritance caused by pathogenic germline variants in the POLE or POLD1), and somatic APC mosaicism.<sup>2,11,12</sup> A flowchart of FAP diagnosis is shown in ► **Fig. 1**.

### Genotype-Phenotype Relationships in FAP

In previous studies, it has been demonstrated that different phenotypes of FAP have corresponding genotypes. In the classification of FAP, variant at codon 1250–1464 (in particular at codon 1309) indicated profuse FAP; extreme ends and selective splicing site of exon 9 is correlated with AFAP; and the remaining part (codon 157–1595) is related with sparse FAP.<sup>13</sup> Additionally, extracolonic FAP-associated lesions are also closely related with APC mutation types: susceptibility to DT is correlated with mutations between codons 1395 and 2000, or at the 3' of codon 1444; CHRPE has been associated



**Fig. 1** Flowchart of familial adenomatous polyposis (FAP) diagnosis.

with mutations between codon 457 and 1444<sup>14</sup>; APC mutations located at 3' of before codon 1395, exon 4, and codon 564–1493 may predict the upper intestinal polyposis.<sup>15</sup> Hepatoblastoma was found to be related with APC mutations between codon 141 and 1751 and thyroid tumors are between codon 140 and 1309.<sup>16</sup> Therefore, it is helpful for FAP diagnosis and therapy to carry out genetic test early.

However, the clinical detection rate of APC pathogenic variants is approximately 60%, indicating that a part of FAP patients' genotypes remain unclear and other additional pathogenic mechanisms are unknown.<sup>17</sup> Thus, exploring the relationship between FAP clinical features and genotypes is significant for FAP treatment and some progresses have been made. Scientists from Italy performed a literature meta-analysis of clinically characterized patients ( $n=97$ ) harboring truncating mutations in APC C-terminus after screening APC mutations in one family whose members ( $n=4$ ) developed gastric polyposis, colon oligopolyposis, and DTs, and described a novel FAP clinical variant, named as gastric polyposis and desmoid FAP.<sup>18</sup> Based on the comprehensive genomic analysis, a complex 3.9Mb rearrangement involving 14 fragments from chromosome 5q22.1q22.3 is identified, which separates APC promoter 1B from the coding open reading frame thus leading to allele-specific downregulation of APC messenger ribonucleic acid and disrupts the APC-Axin-GSK3B- $\beta$ -catenin pathway; this constitutional chromothripsis underlies some FAP patients' clinical phenotype and may be a cause of genetic predisposition to colon cancer.<sup>19</sup> Through multigene panels to screen 46 unrelated probands, the Chinese research found that the onset time of upper gastrointestinal polyp is much earlier in patients with both APC and MUTYH mutations than MUTYH or APC mutation carriers, suggesting APC and MUTYH gene mutation analyses should be simultaneous.<sup>20</sup> In addition, many novel APC mutations are discovered by genomic sequence, such as insertion [c.3992\_3993insA; p.Thr1332Asnfs\*10] in exon 16, c.646-1G>T, c.1285delC, c.1350\_1352delinsAC, c.230\_233delITAGA, and Ex3\_16DEL (EX3\_16/CDS3\_15) from different pedigrees,<sup>21,22</sup> which helps us to deeply understand the pathogenic mechanisms and genotype-phenotype relationships of FAP.

Moreover, results of studies proved that links between genotypes and clinical features are varied from races and regions.<sup>23,24</sup> Thus, the international guidelines may be not applied to all populations. Hereby, genomic sequence should be applied globally and it will assist to capture the links between genetic variants and diseases.

## Decision about the Timing of Surgery

Up to date, there is no definite guideline about the timing of surgery. Generally, patients with CFAP are recommended proctocolectomy at the age of 20s.<sup>6</sup> Proctocolectomy may damage the anus function, fecundity, and increase the risk of desmoid incidence, which affect patients' quality of life (QOL).<sup>13</sup> Prior to the surgery, factors including genotype, severity of the familial phenotype (including risk for desmoid disease), the extent of polyposis at diagnosis, individual

considerations, and local practices and expertise should be accessed.<sup>10</sup>

With the deep understanding of FAP and the rapid progress of endoscopic technology, not all the patients diagnosed with FAP need surgery immediately, while proctocolectomy may be delayed in parts of FAP patients.<sup>25</sup> How to stratify these patients is always on the debate. Normally, for FAP patients with presence of symptoms, or lesions over 5 mm, or high-grade dysplasia, or not amenable to endoscopic resection, immediate proctocolectomy is recommended. Some patients can be postponed surgery: young and asymptomatic patients compliant with surveillance, AFAP, and high-risk incidence of DT (preoperative diagnosis, positive family history, or genetically susceptible).<sup>6,13</sup> In light of these factors, many researchers are exploring the timing of surgery for FAP based on the genotypes and manifestations. For example, Prof. James M. Church from Cleveland Clinic created a Web-based model to help clinicians to stratify patients' likelihood of colorectal surgery within 2 and 5 years of their initial examination.<sup>26</sup>

For AFAP patients, studies demonstrated that the development of CRC might be at the age of 46 in Finland and 55 in Japan,<sup>6,27</sup> indicating that timing of surgery for AFAP patients should be decided individually with reference to the colon endoscopy findings.<sup>28</sup> So some doctors insisted that diagnosis of AFAP should be based on phenotype as genotype is not a reliable indicator.<sup>29</sup> Normally, in the cases of less polyp count, mild polyposis may even be managed endoscopically, and surgery can be postponed.

Surgery is a high-risk factor for the incidence of desmoid. Thus, for patients with high-risk of desmoid, the prophylactic surgery should be performed as late as possible but before cancer development, how to optimize the operation time is worth investigating. Recently, through sequence and mutation analysis, a study showed that (1) except mutations at 5' end of APC (5' to 495), all FAP patients need to consider the risk of desmoid after colectomy; (2) the chance of life-threatening DTs was higher in patients with 3' 1062 codon mutation and peaked in patients with 3' 1399 codon mutation; and (3) scheduled monitoring of TP53 circulating tumor deoxyribonucleic acid is proposed to be a novel tool for optimizing the operation time.<sup>25</sup> This study not only emphasized the importance of genetic test in FAP patients, but also provided a method to monitor the incidence of desmoid. Meanwhile, frequent surveillance by computed tomography, magnetic resonance imaging, and palpation is also necessary for desmoid surveillance.

Is chemotherapy effective in postponing surgery? Substantial researches have investigated the chemoprevention medications in an aim to prevent disease progression and postpone the need for colectomy.<sup>30</sup> Randomized controlled trials (RCTs) had reported that sulindac (an nonsteroidal anti-inflammatory drug) and celecoxib (a COX-2 inhibitor) can reduce the number and size of colorectal adenomas in FAP patients, but damage the rectal mucosal and increase risk of cardiovascular events, respectively.<sup>31,32</sup> Another RCT demonstrated that eicosapentaenoic acid, a fish oil, has chemopreventative efficacy in FAP with a well toleration with adverse events similar to

placebo.<sup>33</sup> In addition, more new agents targeting novel pathways in FAP are under investigation to prolong the treatment period, for example, rapamycin targeting the mammalian target of rapamycin pathway.<sup>30</sup>

Above all, timing of surgery for FAP patients varies individually and delay in surgery is feasible for some particular patients. Clinical features, endoscopic findings, genotypes, chemoprevention therapy, and philosophy of medical care should all be taken into consideration when to postpone or decide surgery.

## Surgical Options for FAP

Based on the rectal polyp burden (distribution, size, and number), function of anal sphincter, and whether colon or rectal cancer is present at diagnosis, three different options are listed for FAP patients: total abdominal colectomy (TAC) with ileorectal anastomosis (IRA), total proctocolectomy (TPC) with ileal pouch-anal anastomosis (IPAA), and TPC with end ileostomy (EI).<sup>6,9,10</sup>

TAC with IRA is recommended for patients with less adenomas (< 20) in rectum, or AFAP, or female before pregnancy or marriage, it has little damage on the function of anus, fertility, and sexuality, while endoscopy surveillance is needed every 6 to 12 months after surgery to detect early adenoma in rectum. If adenomas in rectum are over 20, IPAA is the golden standard procedure after TPC, which preserves patients' anus, the QOL to some extent, and is suitable to most CFAP patients.<sup>6,10</sup> Pouch formation is important and has progressed in the past years. Compared with S- or W-pouch configuration, J-shaped pouch has been favored by most surgeons, as it is easier to be constructed and confers a long-term QOL.<sup>34</sup> To obviate the risk of a J-tip leak, D-pouch anal anastomosis, a modified J-pouch, is designed to eliminate the ileal stump, and its construction time was shorter than that for a standard J-pouch.<sup>35</sup>

Two ways of anastomosis are IPAA with mucosectomy, also called hand-sewn IPAA, and ileal pouch anal canal anastomosis, sometimes called stapled IPAA. Hand-sewn IPAA with neoplasia or potential lesions cutoff can lower the risk of adenoma recurrence at anastomotic site, while stapled IPAA has the advantages of shorter time of surgery, better bowel function, and preservation of the anal transitional zone. Besides, a multiple study used Clavien-Dindo classification and Wexner fecal incontinence to evaluate the postoperative complications between the both, and found that stapled IPAA is a safe option in patients with FAP with a potential benefit in reducing pouch-related complications.<sup>36</sup> Thus, stapled IPAA is preferred by surgeons and careful follow-up is required after this procedure. As for the postoperative low anterior resection syndrome, Qin et al found that TPC with straight ileoanal anastomosis plus pedicled omental transposition for FAP is consistent with intestinal physiology, with good intestinal compliance and anal function tended to be as expected over time.<sup>37</sup>

For patients with extensive polyposis in whole colon and lower rectal cancer, anus cannot be preserved, EI is proposed after TPC. Though this surgical approach can prevent CRC

completely, it also deteriorates body image with permanent colostomy. By the way, in patients with failed IPAA, or unsuitable anatomy for IPAA, or problems of an EI, continent ileostomy can serve as an alternative.<sup>38</sup>

Every procedure has pros and cons, and surgeons should choose suitable procedures for patients individually in a clinical setting. Surgical options for FAP are showed in ►Fig. 2. While more extensive studies are needed to investigate these benefits and pitfalls.

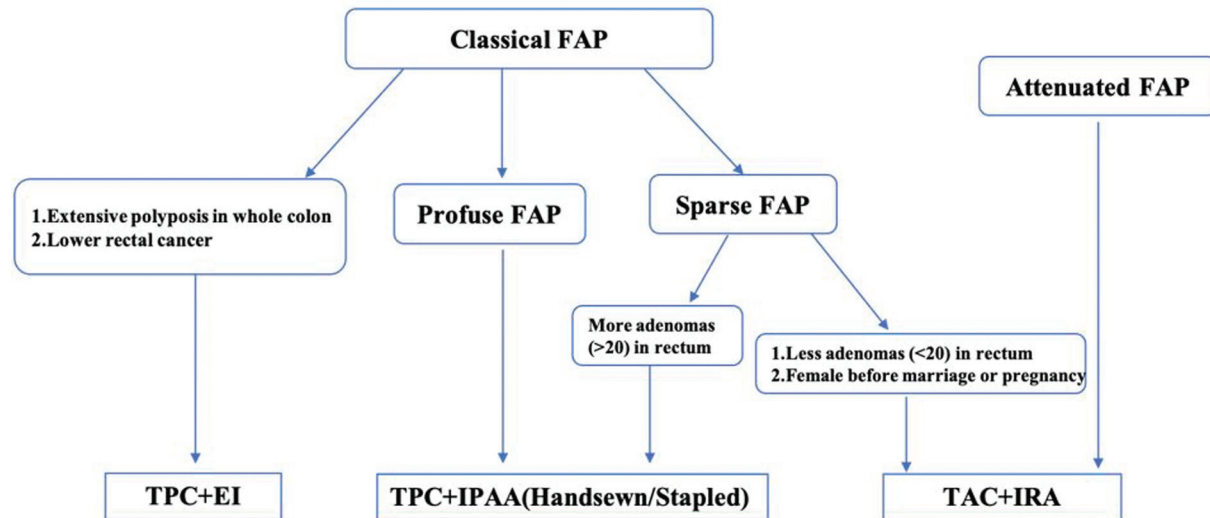
## Minimal Invasive Surgery Applied in FAP

Nowadays, minimally invasive surgery (MIS) has been widely applied in CRC surgical treatment, with the advantage of small incision, quick recovery, short hospital stays, and less pain after operation.<sup>39,40</sup> Laparoscopic TPC has been increasingly applied in FAP treatment nowadays and laparoscopic IPAA is also feasible and safe.<sup>41</sup> Multicenter retrospective cohort studies showed that laparoscopic surgery are feasible options for FAP patients with low rates of morbidity, good functional outcomes, and excellent overall survival rates.<sup>42,43</sup> So laparoscopic surgery has been written in some guidelines.<sup>6,9</sup>

On the other hand, robotic surgery for CRC is gaining popularity, evidence had showed that for CRC, robotic surgery resulted in better oncological quality of resection than conventional laparoscopic surgery, with less surgical trauma and better postoperative recovery.<sup>44-46</sup> However, robotic surgery is limited for multiquadrant abdominal resection, because to achieve this by robotics, a repositioning of the patient-side robotic cart is needed, leading to an increased operative time and workload.<sup>47,48</sup> A single center summarized their experience and demonstrated that robotic multiquadrant colorectal surgery is safe and effective, with low morbidity and mortality rates.<sup>49</sup> Nevertheless, more high-level evidences are needed to support the application of robotic surgery in FAP.

Though laparoscopic or robotic surgery in colorectal disease has many advantages over open surgery, extracting specimens from the abdomen need a mini-laparotomy. Natural orifice specimen extraction (NOSE), as a rising star in the field of MIS, can avoid additional incisions and decrease incision-related complications after totally laparoscopic proctocolectomies.<sup>50,51</sup> As FAP is a sophisticated disease, whether NOSE can be applied in proctocolectomy of FAP is on the debate. Though some experiences about NOSE for FAP had been shared in case reports,<sup>52,53</sup> high-level evidences with long-term follow-up are needed to explore its postoperative outcomes.<sup>54</sup>

Surgical trauma is a risk for incidence of FAP-associated desmoid, and whether MIS could reduce its incidence is to be confirmed. A comparative study evaluating the impact of prophylactic laparoscopic colectomy on the risk of developing DT showed that 16.3% (98/602) in open approach developed desmoid, versus 4% (3/70) in laparoscopic, and concluded that laparoscopic surgery decreased the risk of DT after prophylactic colectomy in patients with FAP.<sup>55</sup> Conversely, a multicenter retrospective cohort study demonstrated that approach (laparoscopic vs. open,  $p=0.17$ ) had no significant effect on the



**Fig. 2** Flowchart of familial adenomatous polyposis (FAP) surgical options. TPC, total proctocolectomy; TAC, total abdominal colectomy; IRA, ileorectal anastomosis; EI, end ileostomy.

increased risk of DT occurrence.<sup>56</sup> Therefore, the relationship between MIS and incidence of FAP-associated desmoid still needs more investigations.

## Conclusion

As a HCRC with various clinical features and multiple genetic variants, the surgical management of FAP has made progresses based on the genotype, phenotype, clinical experience, and psychosocial philosophy. With the rapid development of precise medicine and minimal invasive surgery, investigation in the novel pathogenic mechanisms and innovation on the surgery procedures will help to achieve personalized treatment of FAP.

### Conflict of Interest

None declared.

## References

- Zeggini E, Gloyn AL, Barton AC, Wain LV. Translational genomics and precision medicine: moving from the lab to the clinic. *Science* 2019;365(6460):1409–1413
- Rofes P, González S, Navarro M, et al. Paired somatic-germline testing of 15 polyposis and colorectal cancer-predisposing genes highlights the role of APC mosaicism in de novo familial adenomatous polyposis. *J Mol Diagn* 2021;23(11):1452–1459
- Giang H, Nguyen VT, Nguyen SD, et al. Detection of a heterozygous germline APC mutation in a three-generation family with familial adenomatous polyposis using targeted massive parallel sequencing in Vietnam. *BMC Med Genet* 2018;19(01):188
- Druliner BR, Ruan X, Sicotte H, et al. Early genetic aberrations in patients with sporadic colorectal cancer. *Mol Carcinog* 2018;57(01):114–124
- Nieuwenhuis MH, Vasen HF. Correlations between mutation site in APC and phenotype of familial adenomatous polyposis (FAP): a review of the literature. *Crit Rev Oncol Hematol* 2007;61(02):153–161
- Tomita N, Ishida H, Tanakaya K, et al; Japanese Society for Cancer of the Colon, Rectum. Japanese Society for Cancer of the Colon and Rectum (JSCCR) guidelines 2020 for the clinical practice of hereditary colorectal cancer. *Int J Clin Oncol* 2021;26(08):1353–1419
- Ophir G, Sivan S, Hana S, et al. Abdominal desmoid: course, severe outcomes, and unique genetic background in a large local series. *Cancers (Basel)* 2021;13(15):3673
- Ashar S, Lipsa A, Khan N, Sarin R. High cumulative risk of colorectal cancers and desmoid tumours and fibromatosis in South Asian APC mutation carriers. *J Med Genet* 2022;59(05):492–495
- Syngal S, Brand RE, Church JM, Giardiello FM, Hampel HL, Burt RW American College of Gastroenterology. ACG clinical guideline: genetic testing and management of hereditary gastrointestinal cancer syndromes. *Am J Gastroenterol* 2015;110(02):223–262, quiz 263
- Weiss JM, Gupta S, Burke CA, et al. NCCN Guidelines® Insights: Genetic/Familial High-Risk Assessment: Colorectal, Version 1.2021. *J Natl Compr Canc Netw* 2021;19(10):1122–1132
- Aelvoet AS, Buttitta F, Ricciardiello L, Dekker E. Management of familial adenomatous polyposis and MUTYH-associated polyposis; new insights. *Best Pract Res Clin Gastroenterol* 2022;58–59:101793
- Mur P, García-Mulero S, Del Valle J, et al. Role of POLE and POLD1 in familial cancer. *Genet Med* 2020;22(12):2089–2100
- Campos FG. Surgical treatment of familial adenomatous polyposis: dilemmas and current recommendations. *World J Gastroenterol* 2014;20(44):16620–16629
- Talseth-Palmer BA. The genetic basis of colonic adenomatous polyposis syndromes. *Hered Cancer Clin Pract* 2017;15:5
- Fukushi G, Yamada M, Kaku Gawa Y, et al. Genotype-phenotype correlation of small intestinal polyps on small-bowel capsule endoscopy in familial adenomatous polyposis. *Gastrointest Endosc* 2023;97(01):59–68.e7
- Leoz ML, Carballal S, Moreira L, Ocaña T, Balaguer F. The genetic basis of familial adenomatous polyposis and its implications for clinical practice and risk management. *Appl Clin Genet* 2015; 8:95–107
- Grover S, Kastrinos F, Steyerberg EW, et al. Prevalence and phenotypes of APC and MUTYH mutations in patients with multiple colorectal adenomas. *JAMA* 2012;308(05):485–492
- Disciglio V, Fasano C, Cariola F, et al. Gastric polyposis and desmoid tumours as a new familial adenomatous polyposis clinical variant associated with APC mutation at the extreme 3'-end. *J Med Genet* 2020;57(05):356–360

- 19 Scharf F, Leal Silva RM, Morak M, et al. Constitutional chromothripsis of the APC locus as a cause of genetic predisposition to colon cancer. *J Med Genet* 2022;59(10):976–983
- 20 Li N, Kang Q, Yang L, et al. Clinical characterization and mutation spectrum in patients with familial adenomatous polyposis in China. *J Gastroenterol Hepatol* 2019;34(09):1497–1503
- 21 Wang D, Liang S, Zhang X, et al. Targeted next-generation sequencing approach for molecular genetic diagnosis of hereditary colorectal cancer: Identification of a novel single nucleotide germline insertion in adenomatous polyposis coli gene causes familial adenomatous polyposis. *Mol Genet Genomic Med* 2019;7(01):e00505
- 22 Wang D, Zhang Z, Li Y, et al. Adenomatous polyposis coli gene mutations in 22 Chinese pedigrees with familial adenomatous polyposis. *Med Sci Monit* 2019;25:3796–3803
- 23 de Oliveira JC, Viana DV, Zanardo C, et al. Genotype-phenotype correlation in 99 familial adenomatous polyposis patients: a prospective prevention protocol. *Cancer Med* 2019;8(05):2114–2122
- 24 Khider F, Cherbal F, Boumejdi AL, et al. Germline mutations of the adenomatous polyposis coli (APC) gene in Algerian familial adenomatous polyposis cohort: first report. *Mol Biol Rep* 2022;49(05):3823–3837
- 25 Ge S, Cheng D, Zhang X, et al. Using genotype to assist clinical surveillance: a retrospective study of Chinese familial adenomatous polyposis patients. *Am J Cancer Res* 2022;12(09):4254–4266
- 26 Sarvepalli S, Burke CA, Monachese M, et al. Web-based model for predicting time to surgery in young patients with familial adenomatous polyposis: an internally validated study. *Am J Gastroenterol* 2018;113(12):1881–1890
- 27 Koskenvuo L, Ryyänen H, Lepistö A. Timing of prophylactic colectomy in familial adenomatous polyposis. *Colorectal Dis* 2020;22(11):1553–1559
- 28 Kobayashi H, Ishida H, Ueno H, et al. Association between the age and the development of colorectal cancer in patients with familial adenomatous polyposis: a multi-institutional study. *Surg Today* 2017;47(04):470–475
- 29 Anele CC, Martin I, McGinty Duggan PM, et al. Attenuated familial adenomatous polyposis: a phenotypic diagnosis but obsolete term? *Dis Colon Rectum* 2022;65(04):529–535
- 30 Kemp Bohan PM, Mankany G, Vreeland TJ, et al. Chemoprevention in familial adenomatous polyposis: past, present and future. *Fam Cancer* 2021;20(01):23–33
- 31 Cruz-Correa M, Hyland LM, Romans KE, Booker SV, Giardiello FM. Long-term treatment with sulindac in familial adenomatous polyposis: a prospective cohort study. *Gastroenterology* 2002;122(03):641–645
- 32 Solomon SD, McMurray JJ, Pfeffer MA, et al; Adenoma Prevention with Celecoxib (APC) Study Investigators. Cardiovascular risk associated with celecoxib in a clinical trial for colorectal adenoma prevention. *N Engl J Med* 2005;352(11):1071–1080
- 33 West NJ, Clark SK, Phillips RK, et al. Eicosapentaenoic acid reduces rectal polyp number and size in familial adenomatous polyposis. *Gut* 2010;59(07):918–925
- 34 Ng KS, Gonsalves SJ, Sagar PM. Ileal-anal pouches: a review of its history, indications, and complications. *World J Gastroenterol* 2019;25(31):4320–4342
- 35 Zhang Y, Hu H, Jiang C, Qian Q, Ding Z. D-pouch: a modified ileal J-pouch for patients with ulcerative colitis and familial adenomatous polyposis. *Tech Coloproctol* 2021;25(11):1209–1215
- 36 Konishi T, Ishida H, Ueno H, et al. Postoperative complications after stapled and hand-sewn ileal pouch-anal anastomosis for familial adenomatous polyposis: a multicenter study. *Ann Gastroenterol Surg* 2017;1(02):143–149
- 37 Qin T, Liao J, Qin H, et al. Advantages of total proctocolectomy with straight ileoanal anastomosis plus pedicled omental transposition for familial adenomatous polyposis: a preliminary study. *World J Surg Oncol* 2022;20(01):20
- 38 Wu XR, Ke HX, Kiran RP, Shen B, Lan P. Continent ileostomy as an alternative to end ileostomy. *Gastroenterol Res Pract* 2020;2020:9740980
- 39 Shinji S, Yamada T, Matsuda A, et al. Recent advances in the treatment of colorectal cancer: a review. *J Nippon Med Sch* 2022;89(03):246–254
- 40 Hahn SJ, Sylla P. Technological advances in the surgical treatment of colorectal cancer. *Surg Oncol Clin N Am* 2022;31(02):183–218
- 41 Ahmed Ali U, Keus F, Heikens JT, et al. Open versus laparoscopic (assisted) ileo pouch anal anastomosis for ulcerative colitis and familial adenomatous polyposis. *Cochrane Database Syst Rev* 2009;(01):CD006267
- 42 Ueno H, Kobayashi H, Konishi T, et al. Prevalence of laparoscopic surgical treatment and its clinical outcomes in patients with familial adenomatous polyposis in Japan. *Int J Clin Oncol* 2016;21(04):713–722
- 43 Konishi T, Ishida H, Ueno H, et al. Feasibility of laparoscopic total proctocolectomy with ileal pouch-anal anastomosis and total colectomy with ileorectal anastomosis for familial adenomatous polyposis: results of a nationwide multicenter study. *Int J Clin Oncol* 2016;21(05):953–961
- 44 Feng Q, Yuan W, Li T, et al; REAL Study Group. Robotic versus laparoscopic surgery for middle and low rectal cancer (REAL): short-term outcomes of a multicentre randomised controlled trial. *Lancet Gastroenterol Hepatol* 2022;7(11):991–1004
- 45 Park JS, Kang H, Park SY, et al. Long-term oncologic after robotic versus laparoscopic right colectomy: a prospective randomized study. *Surg Endosc* 2019;33(09):2975–2981
- 46 Degiuli M, Ortenzi M, Tomatis M, et al. Minimally invasive vs. open segmental resection of the splenic flexure for cancer: a nationwide study of the Italian Society of Surgical Oncology-Colorectal Cancer Network (SICO-CNN). *Surg Endosc* 2023;37(02):977–988
- 47 Protyniak B, Jordan J, Farmer R. Multi-quadrant robotic colorectal surgery: the da Vinci Xi vs Si comparison. *J Robot Surg* 2018;12(01):67–74
- 48 Jimenez-Rodriguez RM, Quezada-Diaz F, Tchack M, et al. Use of the Xi robotic platform for total abdominal colectomy: a step forward in minimally invasive colorectal surgery. *Surg Endosc* 2019;33(03):966–971
- 49 Bianchi G, Gavriilidis P, Martínez-Pérez A, et al. Robotic multi-quadrant colorectal procedures: a single-center experience and a systematic review of the literature. *Front Surg* 2022;9:991704
- 50 Palanivelu C, Rangarajan M, Jategaonkar PA, Anand NV. An innovative technique for colorectal specimen retrieval: a new era of “natural orifice specimen extraction” (N.O.S.E). *Dis Colon Rectum* 2008;51(07):1120–1124
- 51 Zhang M, Liu Z, Wang X. Is natural orifice specimen extraction surgery the future direction of minimally invasive colorectal surgery? *Surg Open Sci* 2022;10:106–110
- 52 Awad Z. Laparoscopic total colectomy with transvaginal extraction of the colon and ileorectal anastomosis. *Ann Surg Oncol* 2014;21(09):3029
- 53 Kayaalp C, Yagci MA, Soyer V. Laparoscopic and natural orifice transluminal restorative proctocolectomy: no abdominal incision for specimen extraction or ileostomy. *Wideochir Inne Tech Malo Inwazyjne* 2016;11(02):115–120
- 54 Wolthuis AM, de Buck van Overstraeten A, D’Hoore A. Laparoscopic natural orifice specimen extraction-colectomy: a systematic review. *World J Gastroenterol* 2014;20(36):12981–12992
- 55 Vitellaro M, Sala P, Signoroni S, et al. Risk of desmoid tumours after open and laparoscopic colectomy in patients with familial adenomatous polyposis. *Br J Surg* 2014;101(05):558–565
- 56 Saito Y, Hinoi T, Ueno H, et al. Risk factors for the development of desmoid tumor after colectomy in patients with familial adenomatous polyposis: multicenter retrospective cohort study in Japan. *Ann Surg Oncol* 2016;23(Suppl 4):559–565