



Invasive Giant B-Cell Lymphoma Mimicking Fulminant Pulmonary Embolism

Marc Irqsusi¹ Susanne von Gerlach² Ardawan Julian Rastan¹ Tamer Ghazy¹

¹Department of Heart Surgery, University Hospital, Philipps University of Marburg, Marburg, Germany

²Institute of Pathology, Philipps University of Marburg, Marburg, Germany

Address for correspondence Marc Irqsusi, MD, Department of Heart Surgery, University Hospital, Philipps University Marburg, Baldinger Str. 1, 35039 Marburg, Germany (e-mail: irqsusi@med.uni-marburg.de).

Thorac Cardiovasc Surg Rep 2023;12:e21–e23.

Abstract

Keywords

- ▶ cardiovascular surgery
- ▶ cardiac anatomy/pathologic anatomy
- ▶ histology
- ▶ mediastinal tumor

Background Cardiac non-Hodgkin's lymphoma is rare and has a poor prognosis. Here we report a rare case mimicking pulmonary embolism.

Case Description A 38-year-old woman suffered from severe dyspnea after cesarean section. With the clinical picture of fulminant central pulmonary embolism, lysis therapy was initiated. Further deterioration necessitated extracorporeal membrane oxygenation (ECMO) support and cardiosurgical intervention. Intraoperatively, a massive intravascular tumor obstructed the pulmonary bifurcation and was found to be B-cell lymphoma. Aggressive excision and pulmonary tree reconstruction improved the critical condition and initiated convalescence.

Conclusion High suspicion in central pulmonary embolism and early cardiosurgical therapy after ineffective lysis are essential.

Introduction

Malignant lymphoma of the heart is relatively common but difficult to detect. A small number of studies have discussed this subject in the literature.¹

Primary cardiac lymphomas account for ~1% of primary cardiac tumors and 0.5% of extranodal lymphomas. In contrast, disseminated lymphoma with cardiac involvement can occur in up to 20% of patients with lymphoma. Approximately 80% of primary cardiac lymphoma cases in immunocompetent hosts are diffuse B-cell lymphomas, and in immunodeficient patients, small noncleaved or immunoblastic lymphomas are more frequent. Most cardiac lymphomas are diagnosed post-mortem via autopsy, but current data show a decrease from 64% of cases to only 15%. Common sites of cardiac infiltration by primary cardiac lymphomas are the right atrium, the right ventricle, and the left atrium, followed by the left ventricle.^{1,2} Infiltration of the great cardiac vessels is rare and appears to be

caused by invasion of the mediastinal structures with connection to the lymphatic circulation or blood vessels.³ Here we present a case of a giant B-cell lymphoma with pulmonary vascular invasion mimicking acute pulmonary embolism.

Case Report

A woman in her 30s, suffering from severe dyspnea and repeated syncope after a recent cesarean section, was transferred to our hospital with suspected fulminant pulmonary embolism for further investigation and treatment. Laboratory findings revealed increased liver enzymes and D-dimer levels, as well as an elevated NT-pro-BNP level of 6,825 pg/mL. Electrocardiography showed sinus tachycardia (115 beats per minute) with right axis deviation but no further signs of pulmonary embolism. Echocardiography revealed normal left ventricular function and markedly reduced right

received
January 3, 2023
accepted
January 12, 2023

DOI <https://doi.org/10.1055/s-0043-1764473>.
ISSN 2194-7635.

© 2023. The Author(s).

This is an open access article published by Thieme under the terms of the Creative Commons Attribution-NonDerivative-NonCommercial-License, permitting copying and reproduction so long as the original work is given appropriate credit. Contents may not be used for commercial purposes, or adapted, remixed, transformed or built upon. (<https://creativecommons.org/licenses/by-nc-nd/4.0/>)

Georg Thieme Verlag KG, Rüdigerstraße 14, 70469 Stuttgart, Germany

ventricular function with associated pressure and volume overload, tricuspid annular plane systolic excursion (TAPSE) of 12 mm, and tricuspid regurgitation with a systolic pulmonary pressure of 80 mm Hg above the central venous pressure.

Despite the lack of sonographic evidence of deep vein thrombosis, computed tomography (CT) angiography revealed subtotal occlusion of the pulmonary arterial trunk and the left pulmonary artery. Catheter-based local lysis therapy with a recombinant tissue-type plasminogen activator was initiated.

Despite the lysis, the patient deteriorated within 24 hours. Due to progressive cardiogenic shock and resuscitation, mechanical circulatory support via venoarterial extracorporeal membrane oxygenation (VA-ECMO) through the right femoral vessels was initiated. Repeat CT angiography (►Fig. 1A) confirmed subtotal occlusion of the pulmonary trunk and pulmonary bifurcation, while all lobar pulmonary arteries were free from thrombus formation (►Fig. 1B). Due to the severe cardiogenic shock, we decided not to perform a catheter-based biopsy of the findings, especially as this would not have improved the clinical condition. After discussion with the cardiology team, the patient was transferred to the operating room for high-risk surgical intervention.

Intraoperatively, surgeons identified a mediastinal mass arising from the left lobe of the thymus gland with infiltration of the pulmonary trunk. The mass grew invasively into the lumen of the pulmonary trunk and extended to the right and left pulmonary arteries while the outflow of the lobar pulmonary arteries remained tumor free. Due to the clinical urgency of the case and its unexpected findings, an instantaneous section was not possible. Under suspicion of angiosarcoma, the mass was radically resected, necessitating replacement of the pulmonary trunk and both pulmonary arteries with a vascular T graft. The right pulmonary artery was replaced by an 18-mm Hemashield graft (Vascular Graft AlboGraft Polyester), which was connected end to side to a 26-mm Hemashield graft (Vascular Graft Hemashield Platinum), which was interposed between the pulmonary root and the distal left pulmonary artery. Despite uneventful surgery, prolonged right heart failure and respiratory distress required postoperative ECMO and inhalational nitric oxide (NO) support. The patient was weaned from ECMO

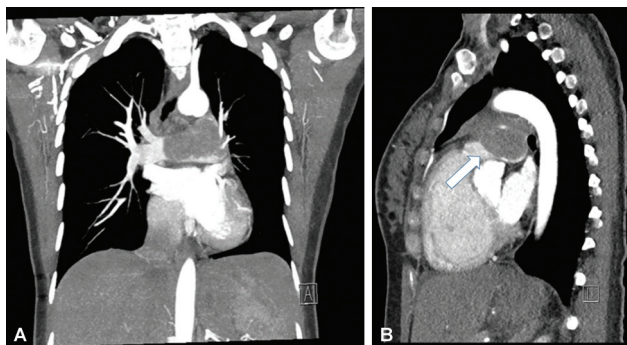


Fig. 1 (A) Computed tomography (CT) angiograph revealing tumor mass. (B) Chest radiograph demonstrates prominent pulmonary artery segment on the left side and lysis catheter in the right pulmonary artery. Arrow indicates tumor mass in the pulmonary trunk.

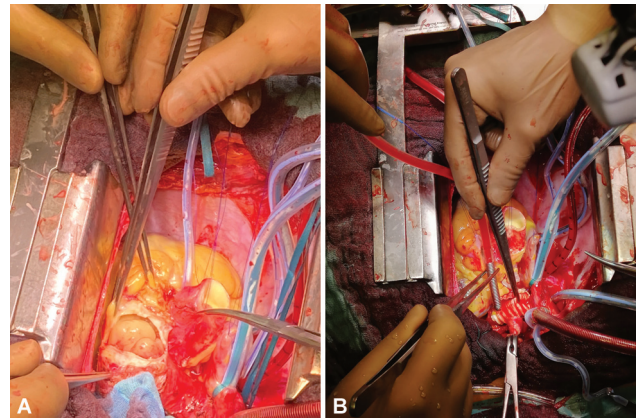


Fig. 2 Mediastinal giant B-cell lymphoma infiltrating the great cardiac vessels. Intraoperative view after opening (A) the pulmonary trunk with direct view of the tumor mass and (B) subsequent reconstruction of the pulmonary vessels with a polyester graft.

support and NO-inhalation therapy on the third and fourth postoperative days, respectively. Extubation was possible on the sixth postoperative day. After further recovery, the patient was transferred to the hematology department for immediate chemotherapy. However, due to the histological findings (see below) and R0 resection, no chemotherapy was initiated. The patient had a full recovery, was discharged to a rehabilitation center, and then home. Six months after the operation, the patient was free of any symptoms and tumor relapse.

The primary histopathological examination confirmed a complete excision of a 7 cm × 6 cm gray-brown, plain tumor mass (►Fig. 2), with spindle-like cells and increased proliferative activity consistent with a B-cell lymphoma (►Fig. 3). The final histopathological diagnosis confirmed an intermediary lymphoma with histopathological signs of both non-Hodgkin's and B-cell lymphoma, and a high-grade expression of pleomorphic CD20-positive blasts and lymphocytic small cells positive for CD3+ and CD5+.

In the CT scan analysis, we had found no evidence for an origin of this B-cell lymphoma except in the heart. The question remains if the B-cell lymphoma really primary originated from the heart or if it secondary infiltrated in the pulmonary artery.

Due to the tumor board decision and the fact that it was an R0 resection, the decision was made not to adjuvant chemotherapy. The clinical and technical follow-up controls should be performed using positron emission tomography and CT (PET-CT).

To our knowledge, this is the first report of a primary mediastinal lymphoma infiltrating the great vessels of the heart and causing life-threatening cardiogenic shock.

Discussion

Primary cardiac lymphomas are extremely rare, and their pathogenesis remains unclear. With nonspecific clinical manifestations, most primary cardiac lymphomas are of B-cell lineage and have poor prognosis.² Large B-cell lymphomas represent the majority of cardiac lymphomas, with up to

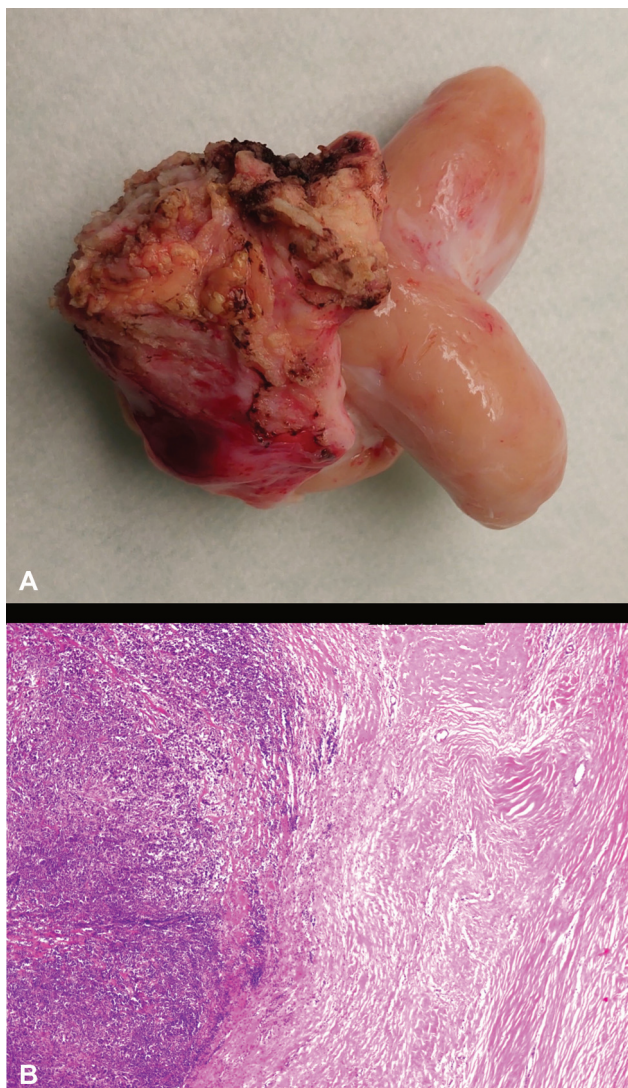


Fig. 3 Histopathological examination of the resected intraluminal mass. Hematoxylin and eosin staining showing infiltration to the (A) pulmonary artery and (B) numerous blast cells.

59% in several case studies, followed by other histologic subtypes, such as T-cell lymphoma (5%), Burkitt's lymphoma (7%), and small lymphocytic lymphoma (4%).²

The predominant clinical features in up to 34% of these cases were signs of heart failure, while up to 20% did not show these signs. Depending on their location and growth, lymphomas only become clinically evident with features such as pericardial effusion, symptoms of heart failure, or even sudden cardiac death. Most patients typically suffer from dyspnea, as well as nonspecific chest pain, atrial fibrillation, and other arrhythmias. The median survival after diagnosis is 3 months (range: 0–72 months), and patients with initial presentations of heart failure had poorer out-

comes. Patients with primary cardiac involvement had better outcomes than those with secondary tumors.⁴

The sensitivity and specificity of different clinical imaging modalities vary. Chest radiography may only demonstrate signs of cardiomegaly. Transthoracic echocardiography is an excellent noninvasive diagnostic tool, while transesophageal echocardiography (TEE) is a more sensitive but invasive technique. CT can demonstrate the morphology, location, potential infiltration, and extent of cardiac structures. Magnetic resonance imaging provides excellent soft-tissue imaging and can further evaluate cardiac function and intracardiac blood flow. Furthermore, ¹⁸F-fluorodeoxyglucose PET is considered an invaluable diagnostic tool for revealing and differentiating cardiac infiltrations.^{5–8} Nevertheless, accurate pathological diagnosis is critical to the decision-making process for further disease management.

Our patient had an unusual presentation of classic Hodgkin's lymphoma (mixed cellularity) with an intravascular tumor mass clinically simulating a fulminant pulmonary embolism. Acute right heart failure and extracorporeal life support required emergency surgical intervention. Although CT imaging was not completely consistent with pulmonary embolism, the intraoperative finding was surprising and required complex allogenic reconstruction of the central pulmonary artery. This case highlights the importance of early and multidisciplinary decisions in patients with life-threatening signs of pulmonary embolism.

Funding

None.

References

- McDonnell PJ, Mann RB, Bulkley BH. Involvement of the heart by malignant lymphoma: a clinicopathologic study. *Cancer* 1982;49(05):944–951
- Gowda RM, Khan IA. Clinical perspectives of primary cardiac lymphoma. *Angiology* 2003;54(05):599–604
- Petrich A, Cho SI, Billett H. Primary cardiac lymphoma: an analysis of presentation, treatment, and outcome patterns. *Cancer* 2011;117(03):581–589
- Wu ZR, Weng DS, Ding YQ, Han HX, Zhu MG. Primary diffuse large B-cell lymphoma of the heart: a clinicopathological study. *Nan Fang Yi Ke Da Xue Xue Bao* 2006;26(10):1481–1483
- Gordon MJ, Danilova O, Spurgeon S, Danilov AV. Cardiac non-Hodgkin's lymphoma: clinical characteristics and trends in survival. *Eur J Haematol* 2016;97(05):445–452
- O'Mahony D, Peikarz RL, Bandettini WP, Arai AE, Wilson WH, Bates SE. Cardiac involvement with lymphoma: a review of the literature. *Clin Lymphoma Myeloma* 2008;8(04):249–252
- Kaida H, Kumode T, Kimura M, Ishii K. ¹⁸F-FDG PET/CT finding of primary cardiac lymphoma. *Clin Nucl Med* 2020;45(04):319–321
- Camoni L, Albano D. Contrast-enhanced ¹⁸F-FDG PET/CT to differentiate primary cardiac lymphoma from primary cardiac angiosarcoma. *J Nucl Cardiol* 2022;29(04):2390–2392